

Anti Tuberculous Treatment: An Amazing Newer Modality Of Treating Foreign Body Aspiration

R Dwivedi, N Samanta, S Chakraborty, S Agarwal

Citation

R Dwivedi, N Samanta, S Chakraborty, S Agarwal. *Anti Tuberculous Treatment: An Amazing Newer Modality Of Treating Foreign Body Aspiration*. The Internet Journal of Pediatrics and Neonatology. 2006 Volume 7 Number 2.

Abstract

Airway foreign bodies continue to be diagnostic and therapeutic challenge for the practicing otolaryngologists and pediatricians. Because foreign body aspiration can mimic other conditions (Pneumonia, croup etc.), particularly without a witnessed event or history of aspiration, there can be delay in management or at times mismanagement of extreme degree with its consequences. In this case report one such, grossly mismanaged case of foreign body aspiration is being presented, who was kept on ATT (Anti tuberculous treatment) for more than 7 months without any significant improvement in the patients condition, additionally the child developed right upper quadrant pain during the course of treatment. Per oral rigid bronchoscopy was performed and foreign body removed after clearing granulation tissue, the patient was relieved.

INTRODUCTION

The incidence of airway foreign bodies has not changed significantly, but the safety in removal has increased dramatically. Despite improvement in public awareness and emergency care, foreign bodies result in approximately 3000 deaths per year caused by asphyxiation (1). Most airway foreign body aspirations occur in patients younger than 15 years of age. The highest incidence occurs between 1 and 3 years of age; up to 25% of the patients are younger than 1 year. Vegetative foreign bodies are seen in 70% to 80% of cases, the most common are peanuts. Plastic pieces comprise 5% to 15% of airway foreign bodies and tend to remain lodged for a longer period because they are inert and radiolucent.

Of all the airway foreign bodies, 80% to 90% are found in bronchi (2). Bronchial foreign bodies are more common in the right bronchus, which is thought to be caused by the position of carina to the left of midline and its lesser angle of divergence from the tracheal axis (3)

Because foreign body aspiration can mimic other medical conditions, particularly without a witnessed event or history of aspiration, there can be delay in management or at times mismanagement, which may lead to complications.

CASE REPORT

A 7 year old boy was brought by his parents with complaints of fever and dry cough for 8 months. There was history of

foreign body aspiration some 8 months back, while sucking the backside of a pen he accidentally inhaled a plastic sealing of a pen (Fig.1). Patient suddenly developed bouts of cough and shortness of breath, which lasted for a few hours. Two days later he developed fever and dry cough, for which his parents consulted various doctors who prescribed him antibiotics and antipyretics, but symptoms continued to persist. When the fever persisted for long, some learned local doctor started ATT (anti tuberculous treatment) empirically, overlooking the past history of aspiration. He kept on taking ATT for about 7 months, without any relief, although he started having pain in right upper abdomen for past few months. He was brought to ENT OPD. Breath sounds were decreased in left lower lobe and the patient was having mild tender hepatomegaly. X- Ray chest showed a collapsed left lung (Fig.3), which were seen in previous X-rays also (Fig.2), LFT was marginally deranged; other workups were within normal limits. ATT was stopped and Bronchoscopy was performed which revealed granulations obstructing left bronchus. The granulation tissue was removed and the foreign body was retrieved. Hemostasis was achieved by adrenaline pledgets and the patient was relieved.

Figure 1

Figure 1: Extracted Foreign body



Figure 2

Figure 2: X-Ray chest PA view (Previous X-Ray), based on which ATT was started

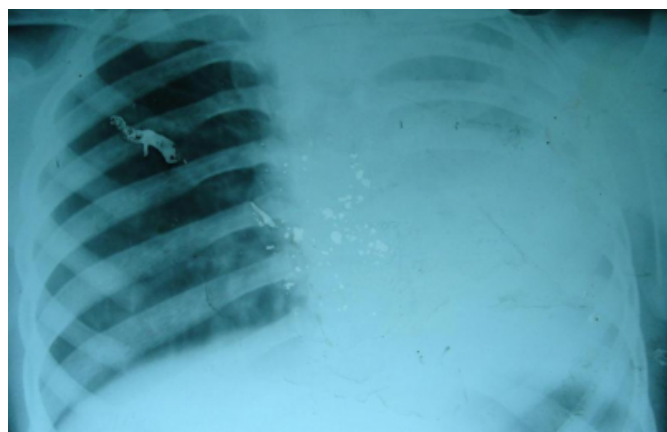
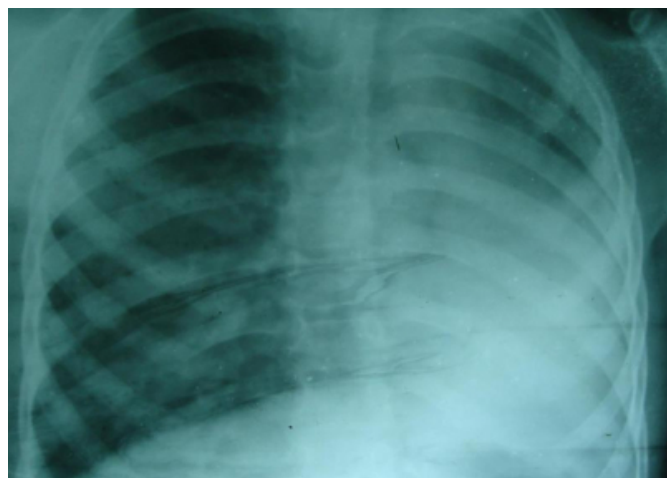


Figure 3

Figure 3: X-Ray chest PA view, just after bronchoscopy



DISCUSSION

Foreign body aspiration is suspected when a victim develops

acute choking or severe coughing with respiratory distress. At times the diagnosis is obscured if the event is unwitnessed in young child. Some children do not admit to aspiration because of fear of punishment. Symptoms of foreign body aspiration can mimic conditions such as asthma, croup (4) and pneumonia. Sudden onset of wheezing in an otherwise healthy child is particularly suggestive of a bronchial foreign body particularly if unilateral but may be a subtle finding (5). About 65% patients have the classic triad of cough, wheezing and decreased breath sounds (6) but up to 95% present with at least one finding only (7).

There are three clinical phases of foreign body aspiration (3). The initial phase consists of choking, gagging and paroxysmal cough and airway obstruction, which occurs at the moment of aspiration. This subsides during the asymptomatic phase when the foreign body becomes lodged and the reflexes fatigue. The asymptomatic phase can last for hours to weeks. Complications occur in the third phase when obstruction, erosion or infection causes pneumonia, atelectasis, abscess or fever. Most complications are a result of delay in diagnosis and treatment (5,6). A high index of suspicion is a must, for early diagnosis and prompt management so as to avoid complications. In general, a careful history and physical examination are the most important factors in diagnosing foreign body aspiration.

All patients presenting with positive history of foreign body inhalation, even when the physical finding and radiological examinations is negative must be subjected to endoscopic evaluation (8). Medical management in the treatment of foreign body aspiration is just an adjunctive (in cases of associated secondary infections) and is not an alternative to bronchoscopy at all. Any kind of wild empirical treatments should not be tried and ATT, of course not. Though Tuberculosis is fairly prevalent in third world countries, but still ATT (Anti tuberculous therapy) should be judiciously used owing to their potential to cause severe toxicity, especially in the pediatric age group.

CONCLUSION

Essentially the only treatment of foreign body aspiration is a rigid bronchoscopy and removal of foreign body under general anesthesia. Role of medical management is limited to the treatment of associated secondary infections only and not as a substitute to bronchoscopy. ATT and other wild kind of therapies must not be used, unless very clearly indicated. High index of suspicion is the only key for early diagnosis and timely treatment. In cases of suspected foreign

bodies, endoscopic evaluation is important because negative radiographs are not enough to rule out the presence of a foreign body (9).

CORRESPONDENCE TO

Prof. Satya P Agarwal

Dept. of Otolaryngology & Head-Neck Surgery

King George's Medical University, Lucknow, India- 226007

+91-0522-2361604, +91-0522-23655539, +91-9415181078

E-mail: raghav_dwivedi@rediffmail.com

References

1. Accident facts, Chicago, 1995, National Safety Council.
2. Esclamado RM, Richardson MA: Laryngotracheal foreign bodies in children: a comparison with bronchial foreign bodies, *Am J Dis Child* 1992; 141:259.
3. Darrow DH, Holinger LD: Foreign bodies of the larynx, trachea and bronchi. In Bluestone C, Stool S, editors: *Pediatric otolaryngology*, Philadelphia, 1996, WB Saunders.
4. Jackson C, Jackson CL: *Disease of the air and food passages of foreign body origin*, Philadelphia, 1936, WB Saunders.
5. Franzese CB, Schweinfurth JM: Delayed diagnosis of a pediatric airway foreign body: Case report and review of the literature, *Ear Nose Throat J* 2002; 8: 655.
6. Inglis AF, Wagner DB: Lower complication rates associated with bronchial foreign bodies over the last 20 years, *Ann Otol Rhinol Laryngol* 1992; 101:61.
7. Black RE, Johnson DG, Matlak ME: Bronchoscopic removal of aspirated foreign bodies in children, *J Pediatric Surg* 1994; 29:682.
8. Cohen SR. Unusual presentations and problems created by mismanagement of foreign bodies in the aerodigestive tract of the paediatric patient *Ann Otol* 1981; 90: 316-22.
9. Silva AB, Muntz HR, Clary R: Utility of conventional radiography in the diagnosis and management of pediatric airway foreign bodies, *Ann Otol Rhinol Laryngol* 1998; 107: 834.

Author Information

Raghav C. Dwivedi

Senior Resident, Department of Otolaryngology and Head Neck Surgery, King George's Medical University

Nirmalya Samanta

Resident, Department of Otolaryngology and Head Neck Surgery, King George's Medical University

Swagnik Chakraborty

Resident, Department of Otolaryngology and Head Neck Surgery, King George's Medical University

Satya P. Agarwal

Professor, Department of Otolaryngology and Head Neck Surgery, King George's Medical University