

Is Dexmedetomidine A Useful Adjunct For Awake Intubation In Retropharyngeal Neurofibromatosis?

N Turgut, A Turkmen, A Altan, A Ali, M Hatiboglu, S Bek

Citation

N Turgut, A Turkmen, A Altan, A Ali, M Hatiboglu, S Bek. *Is Dexmedetomidine A Useful Adjunct For Awake Intubation In Retropharyngeal Neurofibromatosis?*. The Internet Journal of Anesthesiology. 2006 Volume 12 Number 2.

Abstract

We wanted to discuss a successful endotracheal intubation practice that we performed by using dexmedetomidine in a case of neurofibromatosis with neurofibromas narrowing the retropharyngeal region.

An operation was planned in a 27 year old male patient weighing 60 kg with the diagnosis of cervical neurofibromatosis. Four percent lidocaine oral gargle and nebulization was used to anesthetize the oral cavity and supraglottic area. We administered 0.6 µg kg⁻¹ i.v. dexmedetomidine as infusion within 15 minutes in our patient to provide a moderate level of sedation without causing respiratory distress or hemodynamic instability during intubation. The epiglottis was raised with a flexible type rigid laryngoscope and intubation was achieved with insertion of a 7.5 mm internal diameter endotracheal tube.

In conclusion, in patients who expected to have difficult intubation such as in cases of retropharyngeal neurofibromas, successful endotracheal intubation can be performed with a flexible laryngoscope when suitable conditions are provided with local anaesthetics-dexmedetomidine.

INTRODUCTION

The neurofibromatoses are autosomal dominant diseases that have widespread effects on ectodermal and mesodermal tissue.^{1,2} Neurofibromas are the characteristic lesions of the condition and occur not only in the neuraxis but may also be found in the oropharynx and larynx; these may produce difficulties with laryngoscopy and tracheal intubation.^{3,4,5} In these patients, operation is frequently conducted under regional anaesthesia,^{6,7} and tracheostomy is recommended because of difficult intubation.^{8,9,10} In recent years, awake fiberoptic intubation has been a question of debate but there are some conditions that this practice also fails.^{11,12} Awake intubation in the patient with a potentially difficult airway is a stimulating procedure which may be associated with wide haemodynamic changes. To attenuate this response, blunting of airway reflexes is required without losing the patient's cooperation.¹³ Lidocaine sprayed down the endotracheal tube is effective in blunting the reflexes.¹⁴

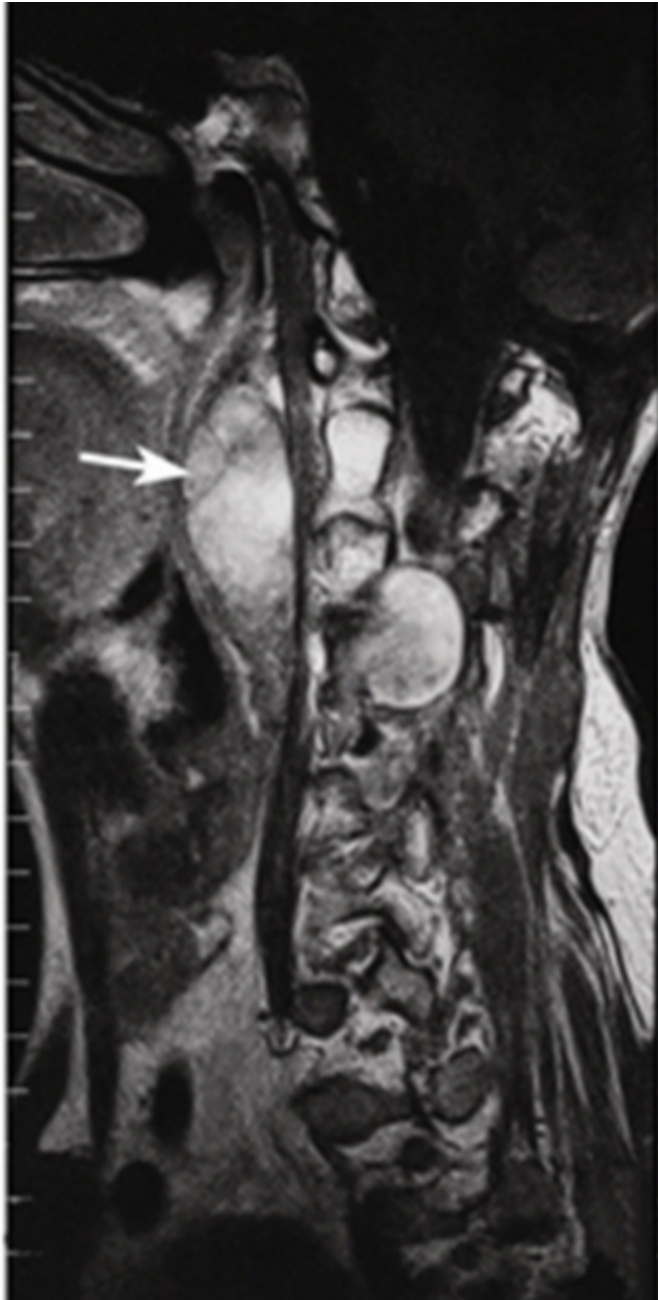
Dexmedetomidine a highly selective α_2 agonist that has a unique property of sedation and providing analgesia without affecting the patient's respiration.^{15,16} It has been successfully used for attenuating the stress response to laryngoscopy.¹⁷ We wanted to discuss a successful endotracheal intubation practice that we performed by using dexmedetomidine in a

case of neurofibromatosis with neurofibromas narrowing the retropharyngeal region.

CASE REPORT

An operation was planned in a 27 year old male patient weighing 60 kg with the diagnosis of cervical neurofibromatosis. Tubular lesions with lobulated contours localized bilaterally inside neural foramina with intraspinal and paravertebral region extensions were observed along C2-C6 levels (Figure 1).

Figure 1



The lesions on the left side obliterated the retropharyngeal region markedly. The widest dimensions in axial plane were approximately 2.7 x 4.9 cm. On physical examination; Mallampati Class III, thyromental distance 6cm, mouth opening 3 cm, neck circumference 39.5cm, sternomental distance 9.7 cm. The examinations of the other systems were normal.

After approval of the ethical committee of the hospital, informed consent was obtained. On the day of surgery, after placement of an IV catheter, the patient was taken to the operating room, where routine monitors were applied. Initial

vital signs were as follows: blood pressure (BP); 128/67mmHg; heart rate (HR); 82 beats per minutes and oxygen saturation (SpO₂); 100%. Four percent lidocaine oral gargle and nebulization was used to anesthetize the oral cavity and supraglottic area. Patient received dexmedetomidine 0.6 µg kg⁻¹ i.v. over a 15 minutes period. The vital signs before intubation were as following: BP, 94/58mmHg; HR, 70 and SpO₂, 100%.

The epiglottis was raised with a flexible type rigid laryngoscope and intubation was achieved with insertion of a 7.5 mm internal diameter endotracheal tube. The vital signs were as following at this time: BP, 110/60mmHg; HR, 77 and SpO₂, 99%. Anesthesia was maintained with air (50%), oxygen (50%) and propofol.

The tumor mass extending into the foramen at C2-C6 levels was removed microsurgically in the sitting position. Propofol was discontinued on skin closure and the patient was allowed to wake up and was extubated. The patient experienced no respiratory difficulty after extubation.

DISCUSSION

Neurogenic tumours arising in the trachea are rare; the association with Von Recklinghausen's (peripheral neurofibromatosis, NF1) disease is exceptional. The disease continues with intra-oral manifestations in 5% of the NF1 patients.¹⁸ The pathologies in NF1 affecting the tongue, larynx and cervical tissues may cause obstruction.

In these cases, elective awake fiberoptic tracheal intubation can fail. Emergency tracheostomy conditions should always be maintained. After induction of anaesthesia airway obstruction and requirement for tracheostomy have been reported in patients with a tongue neurofibroma and a neurofibroma involving the laryngeal inlet.^{8, 9, 11}. In our case, a tumor of 2.7x4.9 cm was localized in retropharyngeal region. Furthermore, our patient had macroglossia and mandibular abnormality. Since we do not have the necessary facilities for awake fiberoptic intubation we planned endotracheal entubation under dexmedetomidine sedation. On the other hand, there were cases in which awake fiberoptic intubation also failed because of the gross changes in the intraoral cavity.¹²

Many drugs such as remifentanyl, midazolam, propofol, dexmedetomidine were used to provide required sedation in patients with considered awake fiberoptic intubation.^{19 20,21} However, successful intubation after inhalational anaesthesia with sevoflurane has been described.²² The most important

feature of the drug selected should be causing non respiratory depression. In recent years, dexmedetomidine was used for this purpose and discussed.^{13, 23, 24}

Dexmedetomidine provides a unique "conscious sedation" (patients appear to be asleep, but are readily aroused), analgesia without respiratory depression. Clinical applications of dexmedetomidine for several procedures such as awake craniotomy, fiberoptic tracheal intubation or MRI examination have been reported, suggesting its usefulness and problems. We administered 0.6 µg kg⁻¹ i.v. dexmedetomidine as infusion within 15 minutes in our patient to provide a moderate level of sedation without causing respiratory distress or haemodynamic instability during intubation.

In conclusion, in patients who expected to have difficult intubation such as in cases of retropharyngeal neurofibromas, successful endotracheal intubation can be performed with a flexible laryngoscope when suitable conditions are provided with local anaesthetics-dexmedetomidine.

CORRESPONDENCE TO

Namigar Turgut Ortaklar Cad. Mevlut Pehlivan Sok. Ali Balaban Apt.No:10/3 Mecidiyekoy /Istanbul / Turkey Tel + 90 212 2112920 e-mail: neturgut@ttnet.net.tr

References

1. Korf BR. Neurocutaneous syndromes: Neurofibromatosis 1, neurofibromatosis 2, and tuberous sclerosis. *Curr Opin Neurol* 1997; 10: 131-6
2. Kloos RT, Rufini V, Gross MD, Shapiro B. Bone scans in neurofibromatosis: neurofibroma, plexiform neuroma and neurofibrosarcoma. *J Nucl Med*. 1996 Nov;37(11):1778-83.
3. Sharma SC, Srinivasan S. Isolated plexiform neurofibroma of tongue and oropharynx: A rare manifestation of von Recklinghausen's disease. *J Otolaryngol* 1998; 27: 81-4
4. Chang-Lo M. Laryngeal involvement in von Recklinghausen's disease: A case report and review of the literature. *Laryngoscope* 1977; 87: 435-42
5. Fisher M, Mc D. Anaesthetic difficulties in neurofibromatosis. *Anaesthesia* 1975; 30: 648-50
6. Sahin A, Aypar U. Spinal anesthesia in a patient with neurofibromatosis. *Anesth Analg*. 2003 Dec;97(6):1855-6.
7. Spiegel JE, Hapgood A, Hess PE. Int J Obstet Anesth. Epidural anesthesia in a parturient with neurofibromatosis type 2 undergoing cesarean section. 2005 Oct;14 (4):336-9.
8. Reddy AR. Unusual case of respiratory obstruction during induction of anaesthesia. *Can Anaesth Soc J*. 1972 Mar;19(2):192-7.
9. Crozier WC. Upper airway obstruction in neurofibromatosis. *Anaesthesia*. 1987 Nov; 42(11):1209-11
10. Chang-Lo M. Laryngeal involvement in Von Recklinghausen's disease: a case report and review of the literature. *Laryngoscope*. 1977 Mar; 87(3):435-42.
11. Nagase K, Akamatsu S, Ueda N, Shimonaka H, Dohi S. Difficult tracheal intubation with von Recklinghausen disease. *Masui*. 1998 Sep;47(9):1128-30.
12. Wulf H, Brinkmann G, Rautenberg M. Management of the difficult airway. A case of failed fiberoptic intubation. *Acta Anaesthesiol Scand*. 1997 Sep;41(8):1080-2.
13. Maroof M, Khan RM, Jain D, Ashraf M. *Can J Anaesth*. Dexmedetomidine is a useful adjunct for awake intubation. 2005 Aug-Sep;52(7):776-7
14. Jee D, Park SY. Lidocaine sprayed down the endotracheal tube attenuates the airway-circulatory reflexes by local anesthesia during emergence and extubation. *Anesth Analg*. 2003 Jan;96(1):293-7
15. Belleville JP, Ward DS, Bloom BC, Maze M. Effect of intravenous dexmedetomidine in humans. I. Sedation, ventilation, and metabolic rate. *Anesthesiology* 1992; 77: 1125-33.
16. Ebert TJ, Hall JE, Barney JA, Ulrich TD, Colino MD. The effects of increasing plasma concentrations of dexmedetomidine in humans. *Anesthesiology* 2000; 93: 382-94.
17. Scheinin B, Lindgreen L, Randell T, Scheinin H, Scheinin M. Dexmedetomidine attenuates sympathoadrenal responses to tracheal intubation and reduces the need for thiopentone and perioperative fentanyl. *Br J Anaesth* 1992; 68: 126-31.
18. Baden E, Pierce HE, Jackson WF. Multiple neurofibromatosis with oral lesions; review of the literature and report of a case. *Oral Surg* 1955; 8: 263-80
19. Zhu YS, Jiang H. Study on midazolam used for awake blind intubation of maxillofacial surgery. *Shanghai Kou Qiang Yi Xue*. 2000 Jun;9(2):97-9.
20. Machata AM, Gonano C, Holzer A, Andel D, Spiss CK, Zimpfer M, Illievich UM. Awake nasotracheal fiberoptic intubation: patient comfort, intubating conditions, and haemodynamic stability during conscious sedation with remifentanyl. *Anesth Analg*. 2003 Sep;97(3):904-8.
21. Hamard F, Ferrandiere M, Sauvagnac X, Mangin JC, Fuscuardi J, Mercier C, Laffon M. Propofol sedation allows awake intubation of the difficult airway with the Fastrach LMA. *Can J Anaesth*. 2005 Apr;52(4):421-7.
22. Wang CY, Chiu CL, Delikan AE. Sevoflurane for difficult intubation in children. *Br J Anaesth* 1998; 80: 408
23. Avitsian R, Lin J, Lotto M, Ebrahim Z. Dexmedetomidine and awake fiberoptic intubation for possible cervical spine myelopathy: a clinical series. *J Neurosurg Anesthesiol*. 2005 Apr;17(2):97-9.
24. Grant SA, Breslin DS, MacLeod DB, Gleason D, Martin G. Dexmedetomidine infusion for sedation during fiberoptic intubation: a report of three cases. *J Clin Anesth*. 2004 Mar;16(2):124-6.

Author Information

Namigar Turgut, M.D.

Department of Anaesthesiology and Reanimation, Ministry of Health, Okmeydani Research and Training Hospital

Aygen Turkmen, M.D.

Department of Anaesthesiology and Reanimation, Ministry of Health, Okmeydani Research and Training Hospital

Aysel Altan, M.D.

Department of Anaesthesiology and Reanimation, Ministry of Health, Okmeydani Research and Training Hospital

Achmet Ali, M.D.

Department of Anaesthesiology and Reanimation, Ministry of Health, Okmeydani Research and Training Hospital

Mustafa Aziz Hatiboglu, M.D.

Department of Neurosurgery, Ministry of Health, Okmeydani Research and Training Hospital

Sirzat Bek, M.D.

Department of Neurosurgery, Ministry of Health, Okmeydani Research and Training Hospital