

# Successful Management Of A Patient In Labour With Hereditary Angioedema

M Thirukkamu, K Salaunkey, S Walker

## Citation

M Thirukkamu, K Salaunkey, S Walker. *Successful Management Of A Patient In Labour With Hereditary Angioedema*. The Internet Journal of Anesthesiology. 2009 Volume 27 Number 2.

## Abstract

Hereditary Angioedema (HAE) is a rare life threatening condition which can complicate pregnancy<sup>1</sup>. We present a successfully managed 33 year old primiparous lady who presented at 38 weeks gestation to our Obstetric unit. She also had a history of suxamethonium apnoea whilst undergoing an appendicectomy earlier. She was managed by a multidisciplinary team that included Obstetricians, Immunologists and Anaesthetists. Peripartum management plans were made much in advance and recorded in her notes. The planning and management led to an uneventful delivery of the baby by Caesarean section.

## INTRODUCTION

Hereditary Angioedema (HAE) is a rare autosomal dominant condition, which causes episodic angioedema precipitated by various stress factors, causing acute airway obstruction, cutaneous angioedema or severe abdominal pain<sup>2,3</sup>. Prior to development of effective therapy the mortality is estimated to be 20-30% during an attack due to laryngeal edema<sup>4</sup>. We report a case of a 33 year old primiparous lady, with known C1 esterase inhibitor deficiency, also with a history of suxamethonium apnoea.

## CASE REPORT

A 33 year old primiparous lady presented to the Obstetric suite at our hospital at 38 weeks gestation in labour. She suffered episodes of abdominal pain during childhood, and one such episode masqueraded as an appendicitis which led to her undergoing an appendicectomy for what essentially was a normal appendix. During this episode she suffered from suxamethonium apnoea. There were no episodes of acute airway oedema, despite her suffering multiple episodes of peripheral swelling. Her sister too was diagnosed to be suffering from HAE.

Further investigations led to a diagnosis of C1 esterase inhibitor deficiency when she was 13 years old. She also had multiple episodes of peripheral swelling but no history of laryngeal oedema. Her initial management included danazol, which was discontinued shortly afterwards due to hot sweats, weight gain and mood swings. She was then started on tranexamic acid which too was discontinued because it

was not effective. The management then onwards was C1 esterase inhibitor 1500 I.U., twice weekly, self administered by the patient.

She was referred to the anaesthetic department by the Obstetric team at 34 weeks gestation, after having seen the immunologists. Immunologists advised that she should remain on her current regime of C1INH concentrate, and in the event of her needing Caesarean section a further 1500 I.U. should be administered up to six hours prior if it was a planned procedure or immediately before if it was an emergency surgery.

The anaesthetic management plan was formulated in consultation with Immunologists and Obstetricians outlining the important issues of prophylaxis and emergency management of an acute attack, progress of labour, and anaesthetic considerations of airway emergencies, suxamethonium apnoea and intravascular fluid shifts, which were, placement of an early epidural, and rocuronium for intubation if needed.

The patient self administered C1inh as soon as she was in established labour.

Investigations at 34 weeks gestation revealed C3: 1.4g/l (0.75-1.65); C4- 0.08g/l (0.14-0.54); C1 esterase inhibitor- undetectable (<45mg/l) consistent with Type 1 HAE, 17% of function; Full blood count, urea& electrolytes and liver function tests were normal. Helicobacter pylori serology and Hepatitis B & C were negative.

The patient received an early epidural, to facilitate analgesia and management of labour and after duration of seven hours the patient underwent a category 2 LSCS due to non progress of labour, with an epidural “top up” of 0.5%Bupivacaine 15ml + Fentanyl 100 mcg.

She had an uneventful surgical and postoperative period.

### DISCUSSION

C1 Inh deficiency (Hereditary Angioedema) is a rare autosomal dominant disorder of Chromosome 11 causing a clinical spectrum of disorders ranging from life threatening laryngeal oedema to mild rashes and abdominal pains<sup>5</sup>. Episodes can be precipitated by stress, trauma, and drugs and are sometimes entirely unpredictable<sup>2</sup>.

### EPIDEMIOLOGY

There are more than 100 different spontaneous mutations that have been described leading to HAE, without any sex or racial bias. The prevalence is 1:50000 around 85% of whom have HAE type 1. There is little correlation between the symptoms and the genotype among different patients. There is also an acquired cause of C1 Inh deficiency described.<sup>2</sup>

### PATHOPHYSIOLOGY

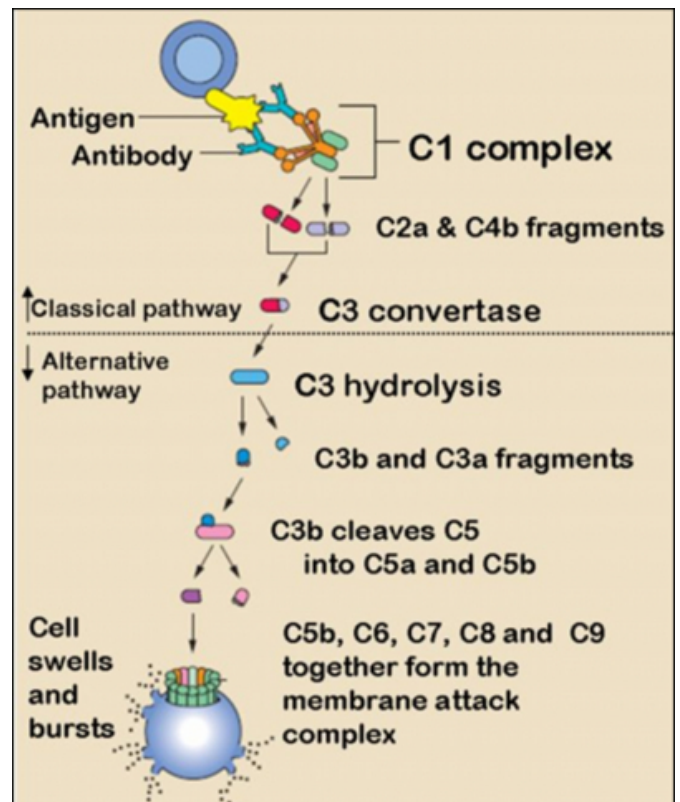
A brief review of the complement system follows; the complement system is a group of about 20 inactive circulating proteins that can be activated by the classical or the alternative pathway. The classical pathway is activated by circulating immune complexes and the alternative pathway by microbes and tumour cells. Activation of complement can lead to lysis, opsonisation, anaphylotoxin activity and immune complex clearance<sup>7</sup>.

C1 Inh is a  $\alpha_2$  globulin serine protease inhibitor, synthesised by the liver, which binds stoichiometrically to C1s, C1r thus inactivating the pathway. Individuals deficient in C1 Inh are unable to control the spontaneous/stress related activation of complement pathway leading to C2 and kinin mediated effects of increased vascular permeability and oedema. There is no Histamine involvement in this process<sup>7</sup>.

C1Inh also inactivates the coagulation cascade by inhibiting factor XIIa, XIa, kallikrien , plasmin and tissue plasminogen activator<sup>7</sup>.

**Figure 1**

Figure 1. Complement activation pathway.



Types of C1 INH Deficiency<sup>9</sup>:

### HEREDITARY

Type 1: Hereditary condition caused by deficiency of C1 Inh

Type 2: Hereditary condition caused by dysfunctional C1 Inh.

### ACQUIRED

Type 1: Increased consumption of C1 Inh due to rapid complement activation by tumour cells.

Type2: Antibodies directed against C1 Inh.

### CLINICAL FEATURES

The disease manifests itself by the third decade, but two third of subjects are symptomatic at 13 years and about a half at 10 years of age. Usually a positive family history can be elicited. Symptoms are precipitated by trivial trauma or emotional upset and can be far ranging from fatal laryngeal oedema to cutaneous oedema, abdominal pain and vomiting.

Acquired C1 Inh tends to occur at an older age and without any family history but can be associated with a lymphoproliferative disorder.

The swelling involves the deep dermis and is non pruritic, non erythematous, circumscribed, cutaneous and asymmetric. Nearly 25% have a non pruritic rash associated with the swelling described as erythema marginatum. The presence of a pruritic blanching rash (urticaria) with oedema usually suggests a diagnosis other than HAE<sup>11</sup>.

The swelling characteristically involves the face, extremities and the aero digestive tract. Facial oedema is the usual initial presenting feature and airway obstruction usually begins slowly with voice change and dysphagia, though there are reports of fairly rapid development of laryngeal oedema. The attacks are more frequently seen during dental procedures and there are case reports of sudden life threatening laryngeal oedema in untreated patients of HAE undergoing dental procedures. It's less manifested during abdominal or orthopaedic procedures probably due to tracheal intubation.

Oedema of the digestive tract leads to colic, nausea, constipation, diarrhoea and functional intestinal obstruction. It must be emphasised that recurrent abdominal pain without rigidity or peritoneal signs may be the only manifestation of HAE<sup>12</sup>. The pain is described as colicky, associated with diffuse abdominal tenderness and high pitched bowel sounds. The associated diarrhoea and sequestration of fluid in the peritoneal cavity can lead to problems of volume loss and haemoconcentration.

During pregnancy the attacks are unpredictable but the risk tends to decrease after the first trimester and during delivery. Though the symptoms may worsen with pregnancy, there is no effect on foetal viability. Pregnancy women with HAE may also suffer from cystic ovaries.<sup>1</sup>

### DIAGNOSIS

C4 level is a rapid screening test for C1 Inh deficiency, normal levels during an attack rule out diagnosis, but decreased levels during an attack warrant an assay for C1 Inh, C2 and C4 and they should remain low in-between attacks. Low C1 and C1q levels suggest acquired C1 Inh deficiency. There is no correlation between the C1 Inh levels and the severity of the disease<sup>13</sup>.

### MANAGEMENT

#### PRIMARY PREVENTION

First & foremost, is the identification of triggers and dealing with them<sup>2</sup>.

Emphasis should be laid on early treatment of infections, eradication of H pylori, and treating infected tooth if any<sup>14</sup>.

Avoidance of Oestrogen in Oral contraceptive (OCP) or Hormone replacement therapy (HRT)<sup>15</sup>.

ACE inhibitors and Angiotensin II antagonists can precipitate HAE due to their effects on the bradykinin pathway and should hence be avoided<sup>12</sup>.

#### Drug Therapy:

The current drug therapy used to manage HAE includes Tranexamic Acid<sup>17</sup>, Androgens, Fresh Frozen Plasma and C1 Inh<sup>2, 4, 16</sup>.

Tranexamic acid is an antifibrinolytic drug that inhibits plasminogen activation and used in the prophylaxis of HAE as it decreases C1 activation. It's used in the prophylaxis of HAE but is not as efficacious as the Androgens. There are concerns about thrombus formation and teratogenic potential. Diarrhoea is usually the limiting side effect. It's usually avoided during pregnancy.

Androgens such as methyl testosterone, danazol and stanozolol act by increasing production of C1 Inh inhibitor from the liver. They can cause weight gain, virilisation, muscle pains, deranged LFT's and reduction of growth in children. They are contraindicated in pregnancy as they cause virilisation of the foetus. It's used for prophylaxis of C1 Inh and also for acute attacks.

The above drugs are unsuitable for use in pregnancy due to their side effect profile of thromboembolic potentiation and androgenic side effects on the foetus C1inh would be the drug of choice to use in pregnancy<sup>18</sup>.

C1 Inh concentrate: It's a blood product and the specific therapy for this condition. It can be used to treat both acute attacks and also for prophylaxis. After administration the effects are seen in 15 min and last for about two days. It can be self administered by patients who have received training in self cannulation.

The best drug to treat an emergency attack is C1 Inh. If C1inh is not available, Fresh frozen plasma can be given but occasionally FFP does worsen the attack due to the presence of C2 a C4 in them.

Further pharmacological developments such as human recombinant C1-INH; Icatibant a bradykinin B2 receptor antagonist; Ecallantide (DX-88), a recombinant kallikrien inhibitor and several protease inhibitors which have been found to have functional overlap with C1-INH; have a role in the management of HAE.<sup>19</sup>

## **ANAESTHETIC CONSIDERATIONS**

In this patient establishment of an early working epidural, and topping it up for a Caesarean section avoided the need for a general anaesthetic.

Prophylaxis needs to be administered where possible before these patients have any surgical procedure, and regional anaesthesia is preferred to general anaesthesia as it avoids airway manipulation thus eliminating an important trigger for precipitation of an attack. If GA can't be avoided, then mask ventilation is preferred over ET intubation. The use of LMA is unclear due to their large contact area of the LMA potentially causing worse laryngeal oedema.

In conclusion, this report demonstrates that rare life threatening conditions which when presented to a District Hospital could still be managed effectively with adequate perioperative planning and preparation involving a dedicated multidisciplinary team.

## **References**

1. Hereditary angioedema and pregnancy, Chinniah N; Katelaris CH; Aust N Z J Obstet Gynaecol. 2009 Feb; 49(1):2-5.
2. C1 inhibitor deficiency: consensus document. Gompels MM et al; Clin Exp Immunol 2005 Mar; 139(3):379-94.
3. Canadian 2003 International Consensus Algorithm for the Diagnosis Therapy, and Management of Hereditary Angioedema. Bowen T et al; J allergy and Clinical Immunology 2004 Sep; 114(3):629-37.
4. Angioedema, Hereditary, Warren Heymann et al, emedicine, updated 14 Apr 2010.
5. C1-inhibitor deficiency and angioedema: molecular mechanisms and clinical progress. Trends Mol Med. 2009; 15(2):69-78 .
6. Craig T, Riedl M, Dykewicz MS, et al. When is prophylaxis for hereditary angioedema necessary? Ann Allergy Asthma Immunol. May 2009;102(5):366-72
7. The pathophysiology of hereditary angioedema. Davies A E Clin Immunol 2005 Jan; 114(1):3-9.
8. <http://biochemistryquestions.wordpress.com/2009/06/11/biochemistry-of-the-complement-system/>
9. Cugno M, Zanichelli A, Foiemi F, Caccia S, Cicardi M. C1-inhibitor deficiency and angioedema: molecular mechanisms and clinical progress. Trends Mol Med. Feb 2009;15(2):69-78.
10. Hereditary angioedema, new findings concerning symptoms, affected organs and course, American Journal of Medicine, 2006, 119(3) 267-74.
11. Erythema Marginatum and hereditary angioedema, Starr JC et al, South Med J. Oct 2004; 97(10): 948-50.
12. Bork K et al, Recurrent episodes of skin angioedema and severe attacks of abdominal pain induced by oral contraceptives or hormone replacement therapy. Am J Med. Mar 2003; 114(4): 294-8.
13. Zuraw BL. Clinical practice. Hereditary angioedema. N Engl J Med. Sep 4 2008; 359(10):1027-36.
14. Karlis V, Glickman RS, Stern R, Kinney L. Hereditary angioedema: case report and review of management. Oral Surg Oral Med Oral a. Pathol Oral Radiol Endod 1997; 83:462-4.
15. Bork K, Fischer B, Dewald G. Recurrent episodes of skin angioedema and severe attacks of abdominal pain induced by oral contraceptives or hormone replacement therapy. Am J Med 2003; 114:294-8.
16. Kreuz W, Martinez-Saguer I, Aygoren-Pursun E, Rusicke E, Heller C, Klingebiel T. C1-inhibitor concentrate for individual replacement therapy in patients with severe hereditary angioedema refractory to danazol prophylaxis. Transfusion. May 20 2009.
17. Sheffer AL et al, Tranexamic acid: preoperative prophylactic therapy for patients with hereditary angioneurotic edema, J Allergy Clin Immunol 1977; 60:38-40.
18. Lindoff C, Treatment with tranexamic acid during pregnancy, and the risk of thrombo-embolic complications, Thromb Haemost 1993; 70:238-40.
19. Zuraw BL. Novel therapies for hereditary angioedema. Immunol Allergy Clin North Am. Nov 2006;26(4):691-708

**Author Information**

**M Thirukkamu**

William Harvey Hospital

**K Salaunkey**

William Harvey Hospital

**S Walker**

William Harvey Hospital