

Images in Neurology: Hypsarrhythmia

N Sethi, B Kosofsky, J Torgovnick, G Solomon, E Arsura, P Sethi

Citation

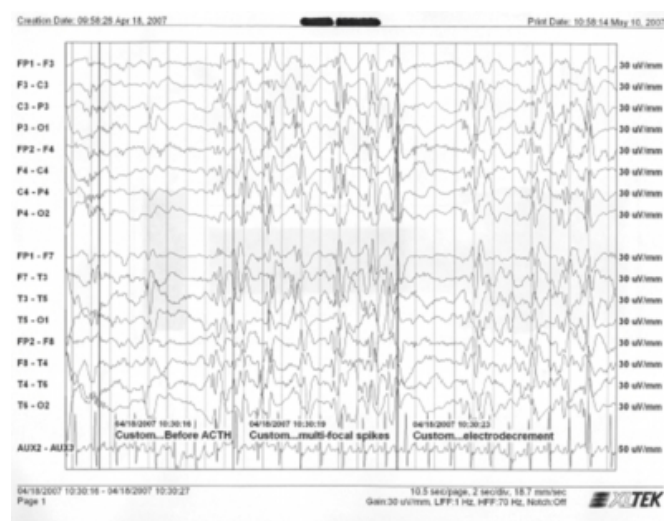
N Sethi, B Kosofsky, J Torgovnick, G Solomon, E Arsura, P Sethi. *Images in Neurology: Hypsarrhythmia*. The Internet Journal of Neurology. 2006 Volume 7 Number 1.

Abstract

A 7-month old infant boy with global developmental delay and no history of prenatal or perinatal disorders was referred to the neurophysiology laboratory for a routine electroencephalogram (EEG). There was no history or examination features suggesting the presence of epilepsy or a specific epileptic syndrome. Routine EEG (Fig 1) revealed a disorganized background and a characteristic inter-ictal pattern consisting of high to extremely high-voltage polymorphic delta and theta rhythms with superimposed multifocal spikes and wave discharges consistent with hypsarrhythmia.

Figure 1

Figure 1: EEG showing typical inter-ictal background of high voltage delta and theta rhythms with multifocal spikes and wave discharges compatible with hypsarrhythmia. Intermittent generalized attenuation (electrodecremental response) is noted.

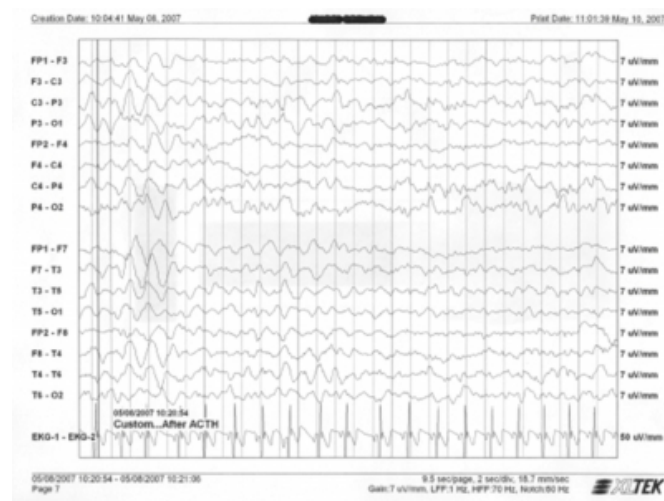

On Video-EEG study intermittent high-voltage frontal predominant generalized slow wave transient followed by voltage attenuation (electrodecremental response) were seen. These were time locked to flexor and extensor spasms consisting of contraction of the flexor muscles of the neck,

torso and the limbs resulting in a brief jerk on the video record. These spasms were seen to occur in cluster once every 5-7 seconds. No change was noted in the inter-ictal EEG after administration of pyridoxine. Extensive work-up for etiology of infantile spasms including neuroimaging and screening for metabolic disorders and neurocutaneous syndromes (phakomatosis) was unrevealing. Clinical response to adrenocorticotrophic hormone (ACTH) was gratifying with disappearance of spasms and normalization of the EEG (Fig 2).

Figure 2

Figure 2: Normalization of the EEG 10 days after initiation of ACTH therapy.



SUMMARY

Seizures should be considered in the differential diagnosis of developmental delay in infants and young children. Infantile spasms may be subtle and missed by both the parents and even a trained physician. Routine and prolonged video-EEG monitoring may help to clarify the diagnosis in suspected cases. Response to medications like ACTH and vigabatrin at least initially might be gratifying with normalization of the EEG and control of infantile spasms.

CORRESPONDENCE TO

NK Sethi, MD Comprehensive Epilepsy Center NYP-Weill
Cornell Medical Center 525 East, 68th Street New York, NY
10021 (USA) Email: sethinitinmd@hotmail.com

References

1. Glauser TA, Morita DA. Infantile spasm (West Syndrome). Article in emedicine.
<http://www.emedicine.com/neuro/topic171.htm> - 114k.

Author Information

N. K. Sethi

Comprehensive Epilepsy Center, NYP-Weill Cornell Medical Center

B. Kosofsky

Department of Pediatric Neurology, NYP-Weill Cornell Medical Center

J. Torgovnick

Department of Neurology, Saint Vincent's Hospital and Medical Centers

G. Solomon

Comprehensive Epilepsy Center, NYP-Weill Cornell Medical Center

E. Arsura

Department of Medicine, Saint Vincent's Hospital and Medical Centers

P. K. Sethi

Department of Neurology, Sir Ganga Ram Hospital