

Reducing Anastomotic Time - Technical Aspects Of Using The VCS® Clip Applier For Microvascular Anastomosis In Free Flap Surgery.

C Cope, D Pennington

Citation

C Cope, D Pennington. *Reducing Anastomotic Time - Technical Aspects Of Using The VCS® Clip Applier For Microvascular Anastomosis In Free Flap Surgery.* The Internet Journal of Plastic Surgery. 2000 Volume 1 Number 1.

Abstract

Technical aspects of using the VCS(r) clip applier (a nonpenetrating titanium clip applied in an interrupted, everting fashion) for microvascular anastomoses are discussed. This technique has the advantage that it can be used for arterial, venous, end-to-side, and end-to-end anastomoses. It is a fast, reliable technique, with a very low complication rate, which can reduce total anastomotic time to 10-20 minutes. This technique has definite advantages in complex or lengthy reconstructions eg where 2 free flaps are being performed, where vein grafts are being used, or where access to the anastomosis is limited.

INTRODUCTION

Free flaps have now become a routine part of reconstructive surgery practice. Although failure rates have decreased with increasing experience, there is still a significant failure rate, even in the best hands. Many free flap failures are due to technical problems in performing the anastomosis. To try to reduce the complication rate there have been many alternatives developed to sutured anastomoses, including cuffs/couplers, penetrating staples, adhesives, and laser welding.^{1,2,3,4,5,6,7,8} Although many of these anastomotic devices have been available for many years, none has gained widespread acceptance. The most popular of these, the 3M precise microanastomotic vascular system has been available for 10 years, with 2 clinical studies showing the effectiveness of this system^{9,10}.

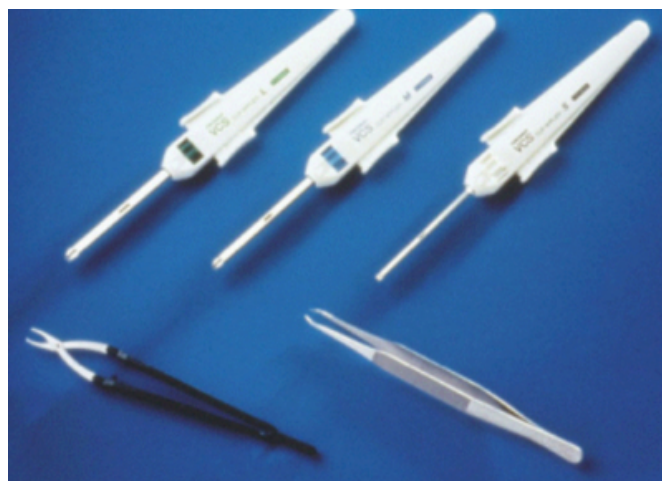
The VCS(r) clip applier (a nonpenetrating titanium clip applied in an interrupted, everting fashion) was first reported in 1992¹¹, and has recently been shown to be an effective method of performing microvascular anastomoses in a large clinical series¹². This technique has a number of advantages over other non-suture methods. Not only can it significantly reduce the anastomotic time, but it also has a very low complication rate. In this report we give details, including potential pitfalls, of the technique.

TECHNIQUE

The VCS(r) (vascular closure staple) clip is an arcuate-legged, nonpenetrating titanium clip manufactured by

Autosuture. It is available in 3 sizes (see below), 2 of which are applicable to microsurgery – the small (0.9mm) and medium (1.4mm) sizes. The larger size is only applicable for macrovascular anastomoses.

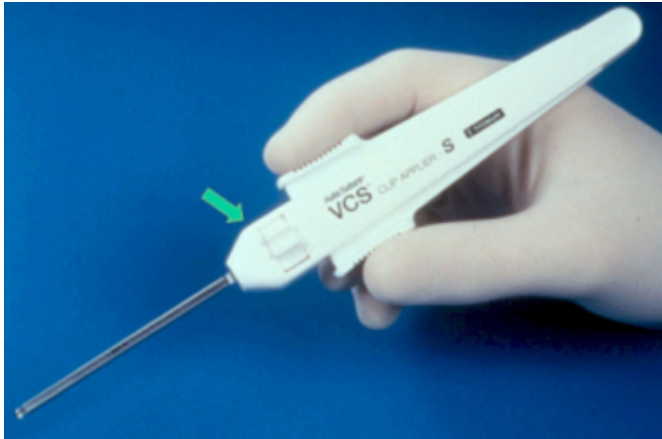
Figure 1



There is also a special clip remover (lower left), which is necessary for removal of clips that are applied incorrectly.

There are 35 clips per applier, and the applier has a head which allows 360° rotation (the arrow below points to head adjustment control), and which is self-releasing following clip application.

Figure 2

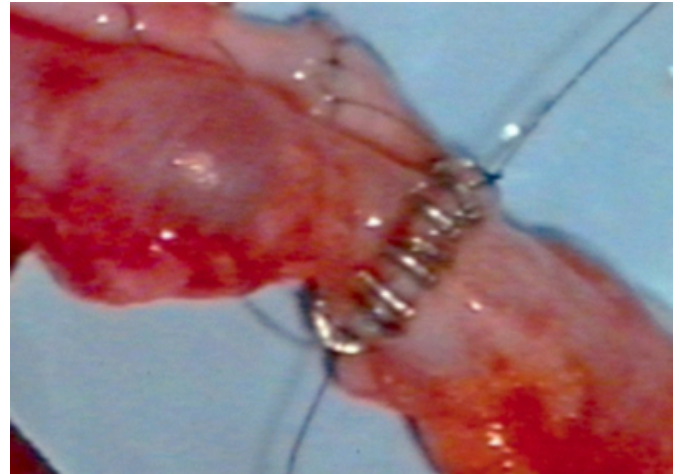


The small VCS(r) clip applier, with finger and thumb resting on the firing mechanism.

The technique of end-to-end anastomosis involves placement of three stay sutures spaced evenly around the circumference of the vessel using the operating microscope.

Symmetrical eversion and opposition of the vessel walls is then produced by applying traction on adjacent stay sutures. Looking from the surgeon's perspective, the right hand stay suture is held by the left hand of the assistant, and the left hand stay by the left hand of the surgeon while he applies the clips with his right hand. An important part of the technique is that the assistant's right hand holds the adventitia of the deep aspect of the vessel closest to the surgeon, or the stay suture on the deep aspect of the anastomosis, pulling it downwards to ensure that the back wall is not caught as the clips are applied. The clips are then applied in an interrupted fashion between the sutures, progressing around the wall of the vessel between the stitches until the anastomosis is completed.

Figure 3



End-to-end anastomoses can be performed by dividing the anastomosis into 4 and applying clips between the sutures in a similar fashion.

The technique has a definite learning curve, with the time taken to perform an anastomosis using the clip applier decreasing significantly with experience. The time taken to perform an anastomosis with experience can routinely be reduced to less than 5 minutes, with 3-minute anastomotic times possible.

We have performed most anastomoses using the small-size clips (1.0mm), including TRAM or rectus flaps, latissimus dorsi, radial forearm, fibula, and gastrocnemius free flaps. Radial forearm flaps, when harvested to include the cephalic vein with the venous anastomosis performed end-to-side to the internal jugular vein, can be anastomosed using the medium-size clips (1.4mm). Vessels smaller than 1.5 mm diameter are probably not amenable to anastomosis using these clips. Although most of the flaps we have used the stapler for have been elective free flaps, we have used the stapler for acute traumatic free flaps without any problems.

We have encountered technical difficulties on a number of occasions, which are listed below. Firstly it should be emphasized that a competent microsurgical assistant is important for this technique, and that it is difficult to apply the clips successfully in the "single-operator only" scenario - we have had to abandon stapling twice due to lack of microsurgical assistance.

If there is a large inequality in vessel diameter of the anastomosed vessels, then the edges of the vessels may not be properly drawn together by tension applied to the stay

sutures because of the unequal length of the vessels between the stay sutures. This can often be overcome by increasing the number of stay sutures to 4 or 5. Inequality in wall thickness between the two vessels can also be a problem, especially when using the saphenous vein as a vein graft anastomosed to another vein with a much thinner wall. A saphenous vein graft will often need the anastomotic edge of the vessel's wall thinned before the anastomosis can be performed.

Approximately 5 % of clips have to be removed and replaced when using this technique (less than 1 per anastomosis). We have found the disposable clip remover supplied by Autosuture to be cumbersome and difficult to use when using the small clips (it works better with the medium-size clips).

DISCUSSION

The VCS(r) clip applier is a nonpenetrating device which minimises intimal damage compared to suture techniques,^{11,13} thus decreasing early postoperative events such as bleeding and thrombosis at the anastomosis. Laboratory studies have shown faster endothelialisation using VCS(r) clips compared to sutures, the same strength as sutures, and long-term there are no differences histologically in relation to intimal thickness, anastomotic stricture, or patency rates.^{11,13,14,15}

Recently it has been shown that the VCS(r) clip applier is a safe and effective method of performing microvascular anastomoses in a large clinical series¹² – this series showed no postoperative anastomotic complications of bleeding, thrombosis, or need for revision (100% patency rate) in 87 free flaps, with a significantly reduced time for completion of anastomoses. It is our belief that the anastomotic complication rate of this technique is actually lower than that of sutured anastomoses, although we have not performed enough free flaps using the VCS(r) clip applier for a statistical significance to become evident.

The VCS(r) clip applier has a number of advantages over other anastomotic devices. The most important of these is that the VCS(r) clip applier can be used for nearly all microvascular anastomoses – arterial, venous, end-to-side, and end-to-end anastomoses. This means that this technique allows significant time savings on nearly all free flaps.

Although there is a learning curve, with anastomoses taking

up to 15 minutes to perform initially, during the latter part of this study the time to perform an anastomosis was routinely less than 5 minutes. Nataf et al.¹⁶ showed a similar reduction, from 20 minutes per anastomosis to 7 minutes per anastomosis after only 10 patients. Matsumoto et al.¹⁷ also showed a reduction of 50-60% in time taken to perform an anastomosis. The average time to complete two sutured anastomoses varies from 35-60 minutes, with the average time to complete two microvascular anastomoses with VCS clips, including stay sutures, being 10 to 20 minutes.

This time saving is especially useful in particularly complex or lengthy reconstructions, where two free flaps are being performed eg bilateral free TRAM breast reconstruction, or where vein grafts are needed. In both these situations up to an hour of operating time can be saved. The technique is also useful in situations where there is limited or difficult access to the vessels being anastomosed, and may have increasing applications in the future with the development of endoscopic and minimal access incisions in reconstructive surgery.

The VCS(r) clip applier allows significant reduction in operating time, has a very low complication rate, and is suitable for use in most free flaps. It provides an excellent alternative to sutures when performing microvascular anastomoses.

ACKNOWLEDGEMENTS

Some of the material contained in this article has previously been published in: Cope, C., Lee, K., Stern, H., & D.Pennington. Use of the vascular closure staple clip applier for microvascular anastomosis in free-flap surgery. *Plast. Reconstr. Surg.* 2000;106:107-10.

References

1. Daniel, R.K., and Olding, M. An absorbable anastomotic device for microvascular surgery: clinical applications. *Plast. Reconstr. Surg.* 1984;74:337.
2. Nakayama, K., Yamamoto, K., and Makino, H. A new vascular anastomosing instrument and its clinical application. *Clin. Orthop.* 1963;29:123.
3. Li YN, Wood MB End-to-side-anastomosis in the dog using the 3M precise microvascular anastomotic system: a comparative study. *J Reconstr Microsurg* 1991;7:345-50.
4. Kimura H, Muneshige H, Ikuta Y Evaluation of an absorbable ring for vascular anastomosis. *J Reconstr Microsurg* 1999;15:331-6.
5. Karamursel S, Kayikcioglu A, Safak T, et al. A new technique for microvascular anastomosis: external metallic circle *Plast Reconstr Surg* 1999;104:1059-65.
6. Gottlob, R., and Blumel, G. Anastomoses of small arteries and veins by means of bushing and adhesive. *J. Cardiovasc. Surg.* 1968 ;9:337.

7. Han SK, Kim SW, Kim WK Microvascular anastomosis with minimal suture and fibrin glue: experimental and clinical study. *Microsurgery* 1998;18:306-11.
8. Kiyoshige, Y., et al. CO2 laser-assisted microvascular anastomosis: biomechanical studies and clinical applications. *J. Reconstr. Microsurg.* 1991 ;7:225.
9. Ahn CY, Shaw WW, Berns S, Markowitz BL Clinical experience with the 3M microvascular coupling anastomotic device in 100 free-tissue transfers. *Plast Reconstr Surg* 1994;93:1481-4.
10. DeLacure MD, Kuriakose MA, Spies AL Clinical experience in end-to-side venous anastomoses with a microvascular anastomotic coupling device in head and neck reconstruction. *Arch Otolaryngol Head Neck Surg* 1999;125:869-72.
11. Kirsch, W.M., Zhu, Y.H., Hardesty, R.A., and Chapolini, R. A new method for microvascular anastomosis: report of experimental and clinical research. *Am. Surg.* 1992;58:722.
12. Cope, C., Lee, K., Stern, H., & D.Pennington. Use of the vascular closure staple clip applier for microvascular anastomosis in free-flap surgery. *Plast. Reconstr. Surg.* 2000;106:107-10.
13. Kirsch, W.M., Zhu, Y.H., Steckel, R., et al. Comparative evaluation of sutures and non-penetrating metal clips for vascular reconstruction. *Cardiovasc. Surg.* 1995;26:136.
14. Boeckx, W., Darius, O., van den hof, B., and van Holder, C. Scanning electron microscopic analysis of the stapled microvascular anastomosis in the rabbit. *Ann. Thorac. Surg.* 1997;63:S128.
15. Leppaniemi, A., Wherry, D., Pikoulis, E., et al. Arterial and venous repair with vascular clips: comparison with suture closure. *J. Vasc. Surg.* 1997 ;26:24.
16. Nataf, P., Kirsch, W., Hill, A.C., et al. Nonpenetrating clips for coronary anastomosis. *Ann. Thorac. Surg.* 1997;63:S135.
17. Matsumoto, K., Obara, H., Hayashi, S., et al. A new technique of vascular anastomosis with VCS clip applier system. In *Proceedings of the 30th World Congress of the International College of Surgeons*, Kyoto, Japan, November, 25-29, 1996.

Author Information

Charles Cope, FRACS

Plastic and Reconstructive Surgery, Surgery, Royal Prince Alfred Hospital

David Pennington, FRCS(Ed), FRACS

Visiting Surgeon, Plastic and Reconstructive Surgery, Surgery, Royal Prince Alfred Hospital