

Endoscopic Transnasal approach to Sino-orbital Foreign body

A GUPTA, S BANSAL, U SINGH, R BANSAL

Citation

A GUPTA, S BANSAL, U SINGH, R BANSAL. *Endoscopic Transnasal approach to Sino-orbital Foreign body*. The Internet Journal of Ophthalmology and Visual Science. 2009 Volume 8 Number 1.

Abstract

A minimal invasive approach to sino-orbital foreign body following transorbital penetrating injury is being reported.

INTRODUCTION

Foreign bodies in the paranasal sinuses and orbit are rare. It is usually traumatic and rarely iatrogenic¹. Foreign body may be organic or inorganic. Retained organic foreign bodies can cause inflammation, whereas inorganic foreign bodies are inert and well tolerated except copper². Nasal endoscopes facilitate removal of foreign body from the sinuses with minimal morbidity³. We report a case of sino-orbital foreign body being exclusively removed by endoscopic transnasal approach.

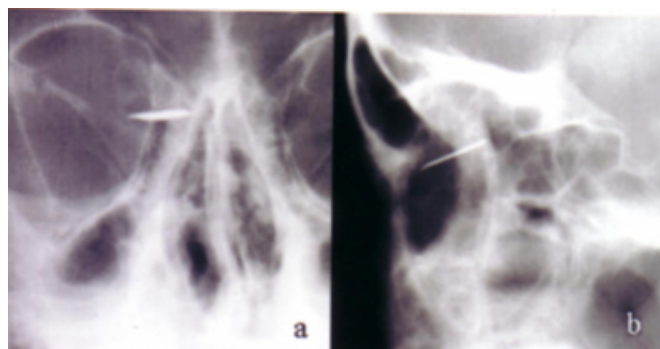
CASE REPORT

Otorhinolaryngology services were called for management of a metallic foreign body of seven days duration in ethmoid sinus projecting to the orbit in a 30-year-old male patient. He had history of penetrating injury just above the medial canthal region while working in a steel plant. The lacerated wound was sutured elsewhere in a private clinic before he was referred to ophthalmology department for pain and diminution of vision of left eye with suspected intraorbital foreign body. The ophthalmic evaluation showed lid edema, conjunctival chemosis with two cm sutured lacerated wound of the upper eyelid just above the medial canthal region. Visual acuity was 6/6 in the right eye and 6/12 in the left eye with normal intra ocular pressure. Anterior segment examination of the both eyes was unremarkable. The left eye posterior segment examination revealed an area of posterior perforation nasal to the disc, near the equator. No obvious foreign body was seen. Ultrasonography (USG) of the orbit showed hypo-echoic shadow suggestive of hemorrhage near the insertion of medial rectus muscle. X-ray of the paranasal sinuses revealed a radio-opaque foreign body, lying horizontally, straddling the orbit and ethmoid sinus (fig. 1a

& b).

Figure 1

Fig.1 (a) Water's View (b) Lateral view of the paranasal sinuses:



Radio opaque foreign body in the right ethmoid sinus projecting into the orbit.

Computed tomography further revealed a foreign body in the anterior ethmoid sinus, partly projecting into the orbit in the medial extraconal region. Perforation site was lasered using frequency-doubled Nd: YAG laser.

In spite of inert nature of the foreign body, endoscopic removal was planned because of persistent pain. The patient was premedicated and anterior ethmoid and sphenopalatine nerve block was achieved with 4% xylocaine and adrenaline 1:1000. Surgery was done using 0° & 30° nasal endoscopes. After uncinectomy, anterior ethmoidectomy and clearing of cells below the anterior skull base was done along those extending into the orbit. The lamina papyracea was removed anterior to the foreign body and the foreign body was found piercing the periorbita. With a freer elevator it was displaced medially and inferiorly from fovea ethmoidalis and removed

with blakesley forceps (Fig. 2). The foreign body measured 17x 8 mm. The patient had an uneventful recovery with the vision becoming 6/6 again.

Figure 2

Fig. 2 Steel piece after endoscopic removal



Foreign body in the sinuses can extend intracranially or introrbitally⁴. Organic foreign bodies are capable of acute reaction like purulent inflammation, abscess formation, gangrene, tetanus and chronic reaction like granulomatous reaction, fistula formation and osteomyelitis. Inorganic foreign bodies usually cause little inflammatory reaction and are well tolerated, with the exception of copper². Sometime it may cause rhino sinusitis, rhinolith, neuralgia like symptoms and rarely malignancy¹. Type, site, size, extension and associated complication of the foreign body needs to be assessed in the management. Foreign bodies which are organic, copper, and which impair function of sinuses and orbit should be removed.

After the introduction of nasal endoscopes by Messerklinger, endoscopic sinus surgery at present is used not only for sinus surgery but also for orbital and skull base surgery. It is safe, simple and with minimal morbidity⁵. The application of endoscopes in the field of ophthalmology are dacryocystorhinostomy, orbital decompression, medial subperiosteal abscess drainage, orbital biopsy, endoscopic

optic nerve decompression, and removal of orbital tumors^{5,6,7}. It gives a distinct advantage of better illumination, magnification, visualization of critical areas and a scarless surgery.

Madina first reported endoscopic approach to sinus foreign body. In this case the metallic foreign body was in sphenoethmoidal junction with associated penetrating globe injury and traumatic optic neuropathy³. Sino orbital foreign body can be removed by exclusive endoscope or endoscope assisted along with open exploration^{8,9}. A written consent, in case of need of conventional open approach and slipping of foreign body into airway needs to be explained when done under local anesthesia. We have used choanal pack in this patient to prevent slipping of foreign body.

COMMENT

Endoscopic sinus surgery allows safe removal of deep foreign bodies even from critical areas with minimal morbidity. Sino-orbital foreign body can be attempted by endoscopic transnasal or endoscopic assisted approach.

References

1. Donald PJ, Gadre AK (1995) Neuralgia-like symptoms in a patient with an air gun pellet in the ethmoid sinus: a case report, *J Laryngol Otol*. 109(7):646-9.
2. Nasir AM, Haik BG, Fleming JC, Hailah M, Al-Hussain, Karcioğlu ZA (1999) Penetrating orbital injury with organic foreign bodies. *Ophthalmology* 106:523-532.
3. Madina R (1992) Endoscopic Sinus surgery: a metallic foreign body at the sphenoethmoidal junction. *J laryngol Otol* 106:998-999.
4. Wu MR, Shih CT, Yeh CW (1998). Transorbital penetrating injury of the paranasal sinuses. *J laryngol Otol* 112; 1202-1204.
5. Davidson TM, Stream G (1994). Extended indication for endoscopic sinus surgery. *ENT journal* 73:467-474.
6. Rajinikanth MG, Gupta AK, Gupta A, Bapuraj JR (2003). Traumatic optic neuropathy: visual outcome following combined therapy protocol. *Arch Otolaryngol Head Neck Surg* 129:1203-6.
7. Herman P, Lot G, Silhouette, et al (1999) Transnasal endoscopic removal of an orbital cavernoma. *Ann Otol Rhinol Laryngol* 108:147-150.
8. Khan-Lim D, Ellis J, Saleh H, Ram B (1999) Endoscopic transnasal removal of orbital foreign body, *Eye* 13:667-8.
9. Wu MR, Shih CT, Yeh CW (1998) Transorbital penetrating injury of the Paranasal sinuses. *J Laryngol Otol* 112 (12):1202-4.

Author Information

ASHOK KUMAR GUPTA, MS, MNAMS

Dept. of Otolaryngology and Head & Neck Surgery, Postgraduate Institute of Medical Education and Research

SANDEEP BANSAL, MS

Dept. of Otolaryngology and Head & Neck Surgery, Postgraduate Institute of Medical Education and Research

USHA SINGH, MS

Ophthalmology, Postgraduate Institute of Medical Education and Research

REEMA BANSAL, MS

Ophthalmology, Postgraduate Institute of Medical Education and Research