

# Primary Subfascial Cyst Hydatid Disease In Proximal Thigh: An Unusual Localisation: A Case Report

E Bulbuloglu, H Ciralik, M Uzel, K Coban, B Börekci

## Citation

E Bulbuloglu, H Ciralik, M Uzel, K Coban, B Börekci. *Primary Subfascial Cyst Hydatid Disease In Proximal Thigh: An Unusual Localisation: A Case Report*. The Internet Journal of Surgery. 2004 Volume 7 Number 1.

## Abstract

The incidence of musculoskeletal hydatidosis is not clear. According to several authors, the incidence of musculoskeletal echinococcosis including involvement of subcutaneous tissue is 1% - 5.4% among all cases of hydatid disease 1. The commonest clinical presentation is an asymptomatic slow growing mass. It is usually associated with involvement of other solid organs. Preoperative radiological diagnosis is very important to avoid biopsy. Diagnosis of echinococcosis should be excluded to avoid leakage of cyst contents and the accompanying risks of anaphylaxis and even death 2,3,4,5 . We presented a primary and subfascial involvement of echinococcal disease in the posterior compartment of the proximal thigh has not been reported previously.

## CASE REPORT

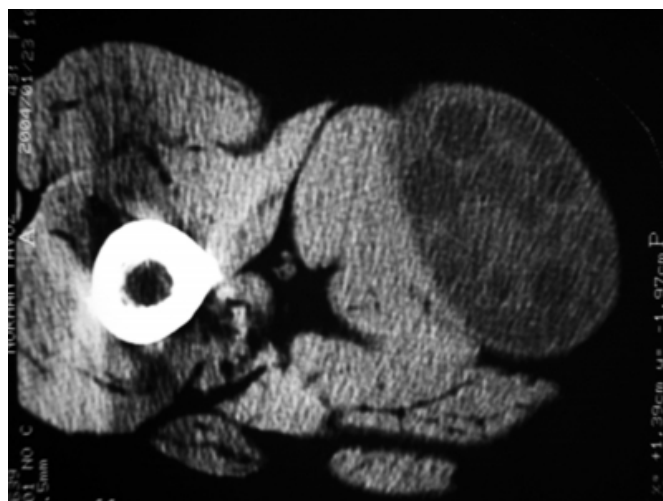
In August 2000, a 42-year-old woman referred with 6-month history of a painless mass slowly growing in posterior region of the right thigh. She had no history of trauma or any other health problem. She was living a village and had contact with both sheep and dogs from her childhood.

On examination, she had a well-rounded and mobile mass under the fascia on the posterior region of the upper-half part of the thigh. Vascular and neurologic functions, and also motions were within normal ranges.

Radiographs revealed a soft tissue mass. A presumptive diagnosis of cyst or neoplasm was made and computed tomography (CT) study was performed. The CT revealed a multilocular cystic mass (13x6 cm) with thick wall behind the muscles of the posterior compartment and under the fascia of the thigh ( Fig.1 ). Thorax radiographies and abdominal ultrasonography revealed no abnormality. Laboratory findings were in normal limits but moderate eosinophilia.

## Figure 1

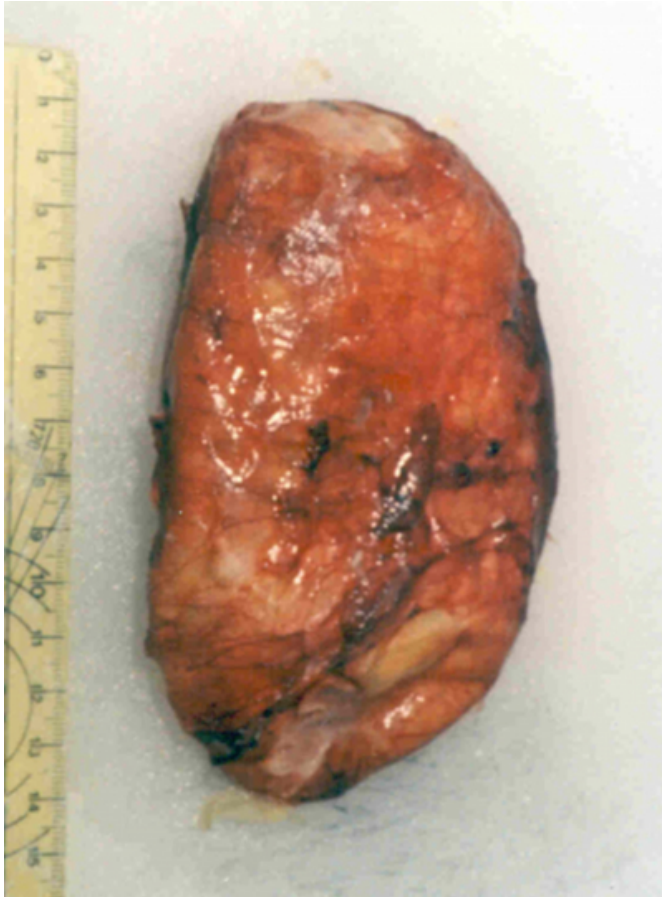Figure 1: CT showed a multilocular cystic mass (13x6 cm) with thick wall behind the muscles of the posterior compartment and under the fascia of the thigh



Surgical intervention was planned. The subfascial, extramuscular mass was exposed with posterior longitudinal incision. Wide excision was performed without destroying the cyst wall through a posterior longitudinal incision ( Fig. 2). A histopathologic examination of the resected cyst confirmed the diagnosis of hydatid cyst. The rim of hydatid cyst composed of three layers, namely endocyst, ectocyst and pericyst was seen.

**Figure 2**

Figure 2: Specimen of cyst hydatid



Diagnosis of primary extramuscular hydatidosis in the thigh was made. Postoperative courses have been uneventful.

## DISCUSSION

Hydatidosis is known since Hippocrates. Hydatid disease is the commonest disease in humans caused by helminths, but primary skeletal and/or muscular involvement seldom occurs. It is a zoonotic infection involving larval forms of small tapeworms of *Echinococcus granulosus*. This parasite inhabits the small intestine of carnivores such as dogs and wolves as definitive hosts in the cycle. Humans become infested by ingesting ova from the feces of these carnivorous animals. The liver and lung are primarily affected in this disease. This disease is ubiquitously distributed with more frequent occurrence in the Mediterranean countries, East Africa, South America, Russia and Australia. Primary involvement of the muscles is very rare and has been reported in only 1–4% of all patients with hydatidosis. It has been suggested that muscles provide a poor environment for the parasite because of the presence of lactic acid. To our knowledge, subfascial involvement of echinococcal disease the posterior compartment of the thigh has not been reported

previously <sup>1,2,3,4,5</sup>.

Diagnosis of echinococcosis should be considered when slowly growing soft tissue is present in patients from a rural areas especially in endemic countries. Preoperative diagnosis of musculoskeletal *E. granulosus* is sometimes difficult clinically and radiologically <sup>1</sup>. It may resemble any soft tissue tumor such as abscess, chronic hematoma, a synovial cyst, and necrotic malignant tumor. Before surgical excision or biopsy and extirpation of cyst, diagnosis of echinococcosis should be excluded to avoid leakage of cyst contents and the accompanying risks of anaphylaxis <sup>2,3,4</sup>. Echinococcosis resembles a benign neoplasm in many ways. In order to prevent serious complications, it should be diagnosed before any therapeutic intervention. The diagnosis is based on the history of exposure in an endemic area and US, CT, MRI findings <sup>2,3,4,5</sup>.

Several patterns of disease have been recognized using various imaging techniques. These include the unilocular cyst, the multilocular lesion and the atypical complex or solid lesion. The multilocular lesion with several daughter cysts inside the mother cysts characteristic, but not pathognomonic of hydatid disease <sup>2,3,4,5</sup>. Ultrasonography is sensitive and useful in diagnosis, showing the size, localisation and type of the cyst. CT scan should be performed in suspicious cases or in order to determine the technique of surgery with demonstration of the relationship to adjacent organs. MRI is capable of adequately demonstrating most features of hydatid disease with the exception of calcifications. Typical signs of hydatidosis are multivesicular lesions with or without hypointense peripheral ring (rim sign) <sup>2-5</sup>.

The diagnosis can be supplemented by specific Ig G, complement fixation, indirect fluorescent, and ELISA tests. The sensitivity of various serological tests used for hydatid disease varies from 64 to 87 %. The specificity of Casoni skin test is low because of this high, 40% false positivity. ELISA is 80–100 % sensitive and 88–96% specific for liver cyst infestation, but less sensitive for lung (50–56 %) or other organ involvement (25–26 %) . After surgical excision of the cyst, reaginic antibody ( Ig E ) titers decrease and become negative after 1–2 years. If titers do not decrease, recurrence of echinococcosis should be considered. Hydatid serology is only valuable when it is positive, negative serologic test does not exclude the diagnosis <sup>1,2,3,4,5</sup>.

Cure depends on total excision of the cysts. If radical surgery is not possible, medical treatment of these patients

does not eliminate the disease and new operations could be necessary. E. granulosus is best treated by complete excision of the intact cyst. If it isn't impossible to excise a large cyst en bloc, the cyst has to be drained intraoperatively, irrigated with a scolecidal agent such as hypertonic saline, and then excised

This case illustrates that echinococcal disease should be considered in the differential diagnosis of every cystic mass in any anatomic location, especially when they occur in areas where the disease is endemic. However, immigration will probably result in the appearance of this condition in unexpected countries. Echinococcosis can be prevented by public health eradication programs.

### **CORRESPONDENCE TO**

Ass. Prof. Dr. Ertan Bulbuloglu Kahramanmaraş Sutcuimam

University, School of Medicine, Department of General Surgery 46050 Kahramanmaraş – TURKEY Phone : +90 344 – 215 24 65 Fax : +90 344 - 221 23 71 e-mail : Ertanbulbuloglu@mynet.com

### **References**

1. C.K. Leow, W.Y. Lau. Soft-tissue images. Hydatid disease of the liver Can J Surg. 2000 43(5):330-1.
2. Saidi, F: Surgery of Hydatid Disease Saunders, Philadelphia 1976, 3:31
3. Rask, MR & Lattig, GJ: Primary intramuscular hydatidosis of the sartorius J Bone Joint Surg Am 1970, 52:582-584.
4. Duncan, GJ & Tooke, SMT: Echinococcus infestation of the biceps brachii Clin Orthop 1990, 261:247-250.
5. Tatari, H, Baran, Ö, Şanlıdağ, T, Göre, O, Ak, D, Manisalı, M, & Havıtcıoğlu, H: Primary intramuscular hydatidosis of supraspinatus muscle Arch Orthop Trauma Surg 2001, 121:93

**Author Information**

**Ertan Bulbuloglu, M.D.**

Department of General Surgery, School of Medicine, Kahramanmaraş Sutcuimam University

**Harun Ciralik, M.D.**

Department of General Surgery, School of Medicine, Kahramanmaraş Sutcuimam University

**Murat Uzel, M.D.**

Department of General Surgery, School of Medicine, Kahramanmaraş Sutcuimam University

**Kenan Coban, M.D.**

Department of General Surgery, School of Medicine, Kahramanmaraş Sutcuimam University

**Bekir Börekci, M.D.**

Department of General Surgery, School of Medicine, Kahramanmaraş Sutcuimam University