

Tuberculous Effusion Development in a Patient with Sarcoidosis During Corticosteroid Therapy

H Yanarda?, Y Güne?

Citation

H Yanarda?, Y Güne?. *Tuberculous Effusion Development in a Patient with Sarcoidosis During Corticosteroid Therapy*. The Internet Journal of Pulmonary Medicine. 2002 Volume 3 Number 1.

Abstract

A 47-year-old man was diagnosed as Löfgren's syndrome and corticosteroid therapy was started. On the seventh month of therapy a pleural effusion developed. Although no definite diagnosis could be made, anti-tuberculous therapy was started empirically. Three weeks later mycobacterium growth was detected on Löwenstein-Jensen culture. The patient recovered almost completely in 2 months with anti-tuberculous therapy. In a well controlled sarcoidosis patient who presents with pleural effusion, if other causes are excluded, it would be wise to start anti-tuberculous therapy since sarcoid pleural effusion is a rare form of disease which accompanies extensive disease and corticosteroid therapy renders patient vulnerable to tuberculosis.

INTRODUCTION

The relatively frequent coexistence of sarcoidosis and tuberculosis has provoked much curiosity and has been researched for decades, but no definite causal relationship has been discovered yet. In practice the differential diagnosis of sarcoidosis and tuberculosis may present a problem especially when rare manifestations of disease are confronted. Pleural involvement is rare in sarcoidosis, whereas it is a quite common entity in tuberculosis. Development of pleural effusion in a sarcoidosis patient could cause serious difficulties in diagnosis.

We present a case of sarcoidosis who developed a pleural effusion 7 months after the diagnosis of sarcoidosis, while taking corticosteroid therapy. The effusion was diagnosed to be due to tuberculosis by growth on Löwenstein-Jensen media, 3 weeks after anti-tuberculous therapy was started empirically.

CASE REPORT

A 47-year-old male hospital employee presented with fever, arthralgia, weight loss and cough. Bilateral hilar lymph nodes were present on his chest radiograph (Figure 1). Physical examination revealed erythema nodosum in the lower extremities and arthritis of the wrists, elbows and ankles. His complete blood count and biochemical analysis were normal. The computed tomographic (CT) scan showed enlarged mediastinal and bilateral hilar lymph nodes, and bilateral nodular and fibrotic lesions in the lung parenchyma.

An abdominopelvic CT scan was performed to exclude any malignancies. Examination of bone marrow biopsy was normal. Tuberculin test was negative (4x2mm).

Microbiological examination of the sputum for bacteria and Ziehl-Nielsen staining for acid-fast bacilli were negative.

There was no growth on ordinary cultures and Löwenstein Jensen media. Fiberoptic bronchoscopy was performed, and transbronchial biopsy and bronchoalveolar lavage fluid samples were taken. The pathological and microbiological examination of these samples were not diagnostic.

Pulmonary function tests were normal. Mediastinoscopy and mediastinal lymph node biopsies were performed.

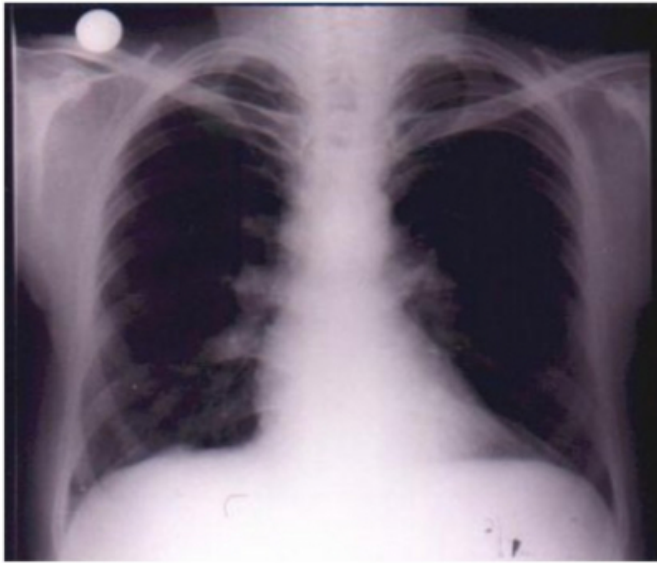
Histopathological examination showed non-caseating granulomatous lymphadenitis, compatible with sarcoidosis.

A diagnosis of sarcoidosis (Löfgren's syndrome) was made.

Oral methylprednisolone 60 mg/day was started. Patient's symptoms and erythema nodosum disappeared, and radiographic findings regressed almost completely. Steroid dose was gradually lowered.

Figure 1

Figure 1: Chest radiograph on admission showing bilateral hilar enlarged lymph nodes.

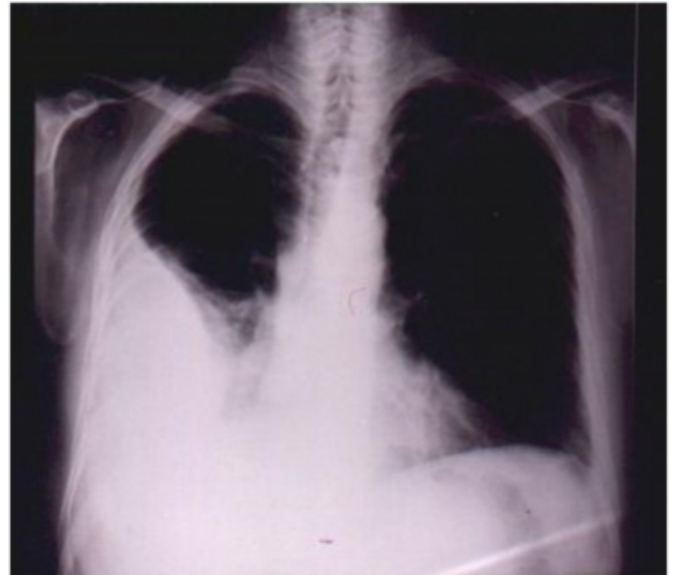


On the fifth month of therapy, the patient presented with right sided chest pain, dyspnea and fatigue. Physical examination was normal. Chest radiograph showed a non-homogenous infiltration in the right lower lung fields. D-dimer level was increased to twice as normal. Ventilation-perfusion scan revealed a low risk for pulmonary emboli. A regressing consolidation was detected on Thorax CT scan. The sedimentation rate was 97mm/hour. Non-specific antibiotic therapy and warfarin sodium were started. On follow up, his symptoms regressed, however the lesion in right lower lung field did not resolve. Antibiotic therapy was stopped after 15 days. Warfarin sodium 5mg/day and methylprednisolone 8 mg/day were continued. Two months later, the patient developed right chest pain and high fever again. A right pleural effusion was detected on his chest radiograph (Figure 2). Sedimentation rate was 111 mm/hour, and tuberculin test had become positive (15x14 mm). Pleural aspiration was performed. The pleural effusion was serofibrinous. Biochemical examination showed that the effusion was an exudate. Cytological examination showed a predominance of lymphocytes. Microbiological analysis including Ziehl-Nielsen staining was normal. Histopathological examination of pleural biopsy material showed chronic, fibrinous, non-specific inflammation, fibrosis and perivascular lymphoid aggregates. Antituberculous chemotherapy was started empirically. Three weeks later, while therapy was being continued, mycobacterium tuberculosis growth was detected on Löwenstein-Jensen culture of pleural effusion. Two months later the patient was symptom-free, and his pleural effusion

had disappeared.

Figure 2

Figure 2: A right sided pleural effusion developed on the seventh month of corticosteroid therapy, while no hilar lymph nodes or parenchymal lesions due to sarcoidosis were present.



DISCUSSION

Pleural involvement in sarcoidosis is usually associated with chronic sarcoidosis, with extrathoracic multiorgan involvement or extensive pulmonary parenchymal lesions (1). Due to the rare occurrence of pleural sarcoidosis, when a sarcoidosis patient presents with pleural effusion, other causes should be searched for first. Tuberculosis, mycotic and bacterial infections such as histoplasmosis and coccidiomycosis, congestive heart failure, renal failure, hypoalbuminemia, malignancies and collagen vascular diseases should be excluded before considering the patient as pleural sarcoidosis. Tuberculosis could likely be the diagnosis in countries where tuberculosis is common, especially when the patient is under corticosteroid therapy.

In this case, several factors urged us to start antituberculous therapy before microbiological evidence was present. Turkey is a country where tuberculin reactivity is very high; therefore, the patient's tuberculin conversion from negative to positive could indicate tuberculosis development following sarcoidosis. Exudative pleural effusion and lymphocyte predominance in a pleural effusion are common findings of both pleural sarcoidosis and tuberculosis. Although there was no granulomatous inflammation, tuberculosis was not excluded because fibrous inflammation might also be a manifestation of tuberculosis. Up to our

knowledge, pleural involvement of sarcoidosis without other manifestations of sarcoidosis has not been reported, and in this patient parenchymal sarcoidosis had regressed almost completely under steroid therapy, suggesting that pleural sarcoidosis is not probable. In addition to this, steroid therapy was another risk factor for development of tuberculosis. The fact that the patient is a porter in our hospital also makes it quite tempting to diagnose him as having tuberculosis, but a high rate of sarcoidosis among hospital employees has also been reported. In two studies on the epidemiology of sarcoidosis in the Isle of Man, it was detected that 18.8% of actively employed sarcoidosis patients were health care workers (_{2,3}). Also, in another study it was detected that the frequency of sarcoidosis is 7.5 times higher among nurses (₄).

As far as we know, there are two other reported cases of pleural effusion due to tuberculosis, developing during steroid therapy for sarcoidosis (_{5,6}). One of these cases was a 50 year-old female patient who developed tuberculous pleural effusion while receiving prednisolone 10-15mg/day for 3 years after being diagnosed as sarcoidosis (₅). Different from our patient, her tuberculin test was always negative and acid-fast bacilli were detected in her pleural effusion sample with Ziehl-Nielsen staining. The other case developed tuberculosis one year after corticosteroid therapy and had disseminated persistent sarcoidosis (₆).

The etiology of sarcoidosis is still unknown, and there seems to be a possible correlation between sarcoidosis and tuberculosis. There are reports on tuberculosis preceeding, following or occurring concomitantly with sarcoidosis (_{7,8}). During recent years *Mycobacterium tuberculosis* DNA was shown in tissues with sarcoidosis involvement in some studies (₉). But there has been much argument on this finding since the presence of previous tuberculosis infection could not be excluded in these patients and the causal relationship is not clear (₁₀). Although the basis of the relationship between sarcoidosis and tuberculosis is still not clear, the clinician must always keep tuberculosis in mind

when a patient with sarcoidosis presents with an unusual manifestation or when unexpected findings develop during the course of disease. In a well controlled sarcoidosis patient who presents with a pleural effusion, if other causes are excluded, it would be wise to start anti-tuberculous therapy since sarcoid pleural effusion is a rare form of disease which accompanies extensive disease and since corticosteroid therapy renders patients susceptible to tuberculosis. Tuberculin conversion could be a clue to diagnosis in such a patient.

CORRESPONDENCE TO

YANARDAG Halil, MD. Department of Internal Medicine, Cerrahpasa Faculty of Medicine, University of Istanbul, TR-34303, Cerrahpasa, Istanbul, TURKEY Phone and Fax no : +90 212 5862928 E-mail : yilmazleman@e-kolay.net

References

1. Chusid EL, Siltzbach LE: Sarcoidosis of the pleura. *Ann Int Med* 1974; 81(2):190-94.
2. Parkes SA, Baker SB, Bourdillan RE, Murray CR, Rakshit M: Epidemiology of sarcoidosis in the Isle of Man: Part 1- A case controlled study. *Thorax* 1987; 42(6):420-426.
3. Hills SE, Parkes SA, Baker SB: Epidemiology of sarcoidosis in the Isle of Man: Part 2- evidence for space-time clustering. *Thorax* 1987; 42(6):427-430.
4. Edmondstone WM: Sarcoidosis in nurses: Is there an association? *Thorax* 1988; 43(4):342-43.
5. Knox AJ, Wardman AG, Page RL: Tuberculous pleural effusion occurring during corticosteroid treatment of sarcoidosis. *Thorax* 1986; 41(8):651.
6. Giotaki HA, Stefanou DG: Biopsy-documented tuberculous pleural effusion in a patient with biopsy-proven sarcoidosis. *Respiration* 1988; 54(3):193-96.
7. Hatzakis K, Siafakas NM, Bouros D: Miliary sarcoidosis following miliary tuberculosis. *Respiration* 2000; 67(2):219-22.
8. Wong CF, Yew WW, Wong PC, Lee J: A case of concomitant tuberculosis and sarcoidosis with mycobacterial DNA present in the sarcoid lesion. *Chest* 1998; 114(2):626-29.
9. Saboor SA, Johnson NM, McFadden J: Detection of mycobacterial DNA in sarcoidosis and tuberculosis with polymerase chain reaction. *Lancet* 1992; 339:1012-1015.
10. Wilsher ML, Menzies RE, Croxson MC: Mycobacterium tuberculosis DNA in tissues affected by sarcoidosis. *Thorax* 1998; 53:871-874.

Author Information

Halil Yanarda?

Cerrahpasa Faculty of Medicine, Internal Medicine Respiratory Diseases Department, Istanbul University

Yilmaz Güne?

Institute of Cardiology, Istanbul University