

Ocular toxoplasmosis: A Case Report

S Pai, S Kamath, R Bhat

Citation

S Pai, S Kamath, R Bhat. *Ocular toxoplasmosis: A Case Report*. The Internet Journal of Ophthalmology and Visual Science. 2007 Volume 6 Number 1.

Abstract

Objective: An observational case study to discuss a case of unilateral congenital toxoplasmosis and the efficacy of Clindamycin as a single drug for treatment.

Methods: Observational case study.

Conclusions: A 11 year old boy with RE toxoplasma retinochoroiditis and positive serology was treated with Clindamycin supplemented with oral steroids. The lesions over the course of treatment regressed.

Results: Clindamycin along with oral steroids is effective treatment option for toxoplasmosis.

CASE REPORT

An 11 year old boy noticed poor vision in right eye accidentally. Vision in right eye was 1/60. Right eye fundus showed yellowish white raised lesion with surrounding oedema and irregular pigmentation in parafoveal region (Fig1.). Left eye was normal.

IgG toxoplasma was high. He was put on a course of Clindamycin and oral steroids. The lesion regressed to chronicity and vision improved (Fig2.).

Figure 1

Figure 1

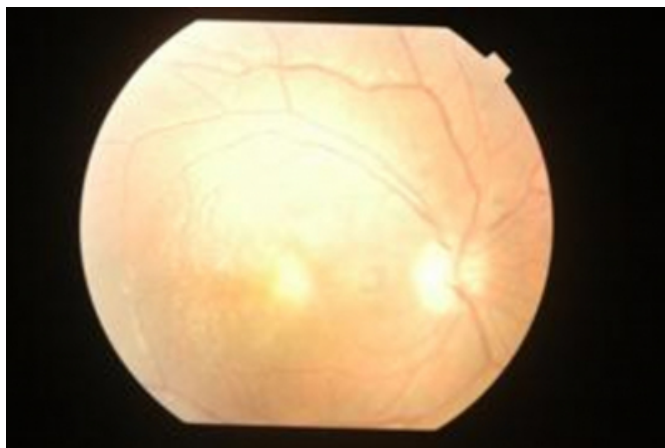
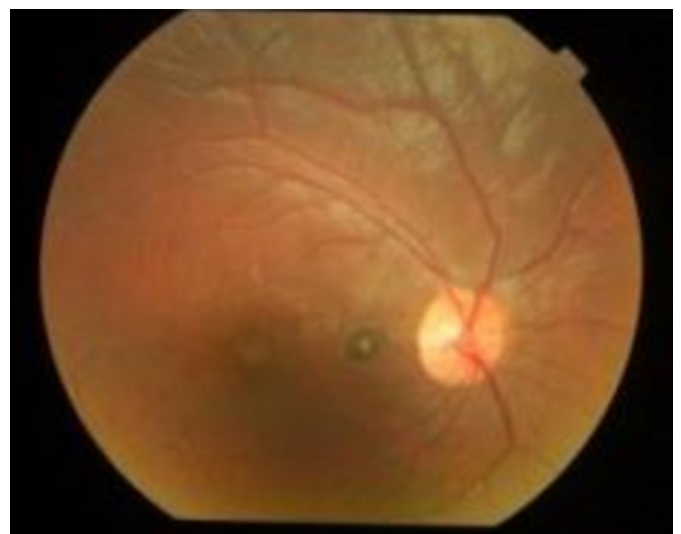

Figure 2

Figure 2



DISCUSSION

Ocular toxoplasmosis congenital variety is transmitted transplacentally.

Chorioretinal scar often bilateral is seen in 80% patients with congenital toxoplasmosis (1). The retinal lesions may be self limited and healed already at birth or may develop months or years after birth (2). The diagnosis of toxoplasmosis is primarily a clinical one. Serological tests are used in

selective cases – Sabin-Feldman dye test, ELISA, Indirect Hemeagglutination Test etc. Newer diagnostic modalities include Western Blot, PCR and Immunofluorescence test₍₃₎.

Toxoplasmosis in immunocompetent individuals is self limited. A two line decrease in visual acuity, lesions located within temporal arcade or affecting optic nerve, moderate to severe vitreous inflammation heralds treatment₍₂₎.

Triple therapy with pyrimethamine, sulfadiazine and oral steroids and quadruple therapy with addition of clindamycin is traditionally used. Several authors believe that

clindamycin alone or in combination is an effective antimicrobial drug that can cause rapid resolution of lesions and reduce recurrences. ₍₄₎

References

1. Met M B, Holfels E, Boyer K M, et al- Eye manifestations of congenital toxoplasmosis. Am J Ophthalmology, 1996
2. Ralph D Levinson, Ocular Toxoplasmosis, Narsing A Rao, Ophthalmology, New Delhi, Myron Yanoff, Mosby, 2006
3. Vishali Gupta, Amod Gupta, Ocular Toxoplasmosis, Modern Ophthalmology , New Delhi, Dutta, Jaypee, 2005
4. Lakhanpal V, Schocket S S, Nirankari V- Clindamycin in treatment of toxoplasmic retinochoroiditis, Am J Ophthalmology, 1983

Author Information

Shobha G. Pai, MS, DOMS

Department of Ophthalmology, Kasturba Medical College

Sumana J. Kamath, MS

Department of Ophthalmology, Kasturba Medical College

Ravindra S. Bhat, PG (Ophthalmology)

Department of Ophthalmology, Kasturba Medical College