

# Zenker's Diverticulum: Case Reports and Review of the Literature: Two Large Zenker's at a Single Institution

N Salehomoum, E Chang, S Kahn

## Citation

N Salehomoum, E Chang, S Kahn. *Zenker's Diverticulum: Case Reports and Review of the Literature: Two Large Zenker's at a Single Institution*. The Internet Journal of Surgery. 2009 Volume 25 Number 1.

## Abstract

Zenker's diverticulum is one of the most common diverticula involving the upper gastrointestinal tract and typically presents in the elderly population with dysphagia, regurgitation, halitosis, and malnutrition. Here we report two cases of large Zenker's diverticula from a single institution. One patient was malnourished secondary to dysphagia. She underwent an open resection of the Zenker's diverticulum and myotomy. Post-operatively she had a small bowel obstruction secondary to an incarcerated obturator hernia and underwent a second operation. The second patient was initially misdiagnosed with a near-obstructing esophageal mass. When correctly diagnosed, he also underwent an open, stapled diverticulectomy and myotomy. After their operations, both patients improved their oral intake and began regaining weight. They were both discharged to rehabilitation facilities. An open surgical approach rather than an endoscopic approach was the successful treatment in both these elderly, malnourished patients.

## INTRODUCTION

Zenker's diverticulum (ZD) is a pulsion diverticulum of the upper esophagus. ZD arises from an inherent area of weakness in the posterior esophageal wall termed Killian's triangle, bound laterally by the oblique fibers of the thyropharyngeal muscle, which constitutes part of the inferior pharyngeal constrictor muscle, and inferiorly by the horizontal cricopharyngeal muscle. Although ZD was first described in 1769 by Ludlow<sup>1</sup>, it was Friedrich von Zenker who recognized the pathophysiology of this disease was due to increased intrapharyngeal pressure.<sup>2</sup> The increased pressure is most frequently attributed to incomplete relaxation of the upper esophageal sphincter causing a high pressure zone within the hypopharynx. Other abnormalities in upper esophageal sphincter function such as uncoordinated contraction and premature contraction and relaxation have also been postulated as potential causes of this increased pressure.<sup>3,4</sup> Progressive tension and pressure cause a mucosal outpouching in the area of weakness which gradually enlarges and dissects posterior to the esophagus into the prevertebral space.<sup>5</sup>

Zenker's diverticula occur predominately in the elderly population of European descent greater than seventy years of age.<sup>6</sup> The reported incidence in the general population ranges from 0.01% to 0.11%, but the true incidence may be much

higher due to the number of asymptomatic patients.<sup>7</sup> Patients with ZD may complain of regurgitation, hoarseness, or halitosis but the most common complaint in 80 to 90% of people is dysphagia. As the diverticulum progressively enlarges, symptoms may worsen leading to profound weight loss and malnutrition as in our patients. Approximately 30 to 40% of these patients may also present with persistent cough and aspiration, with a few even having aspiration pneumonia.<sup>8</sup> More severe symptoms such as pain or bleeding, although uncommon in ZD, have been reported. These symptoms may signal the development of squamous cell cancer which has an incidence of 0.4 to 1.5%.<sup>9,10</sup>

The diagnosis of ZD can be made on a barium esophagogram. The diverticulum will be seen filling with barium at the level of the cricothyroid cartilage posterior to the esophagus. Due to its posterior location, it is important to obtain lateral views of the esophagogram so as not to miss the ZD.

The definitive treatment of ZD requires excision of the diverticulum and a cricopharyngeal myotomy. Although diverticulopexy has been described, this procedure has fallen into disfavor due to the high rate of recurrence. In the open procedure, an oblique incision through the left or right side is made along the anterior border of the sternocleidomastoid muscle. The dissection is carried down through the deep

cervical fascia to the prevertebral fascia taking care not to injure the recurrent laryngeal nerve in the tracheoesophageal groove. At this point the pharyngeal pouch is dissected and the cricopharyngeal myotomy is performed along the posterolateral portion of the cervical esophagus for a length of 4 cm. The diverticulum is then dissected down to its base and divided with a linear stapler. The platysma is then closed over a linear drain which is removed postoperatively after a contrast swallow study.<sup>11</sup>

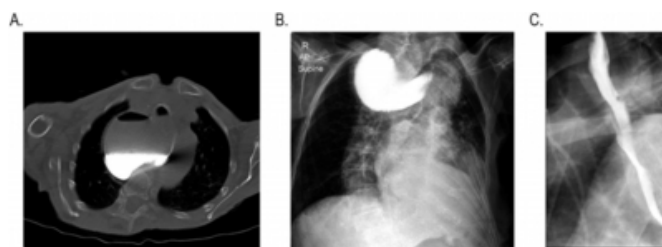
The endoscopic treatment of ZD entails division of the septum between the diverticulum and the esophagus which also contains the cricopharyngeal muscle. The flexible endoscope is introduced into the esophagus in order to visualize the septum which can then be divided to a length of less than 1 cm. Various methods have been described to divide the septum including the use of endostaplers, argon plasma coagulation, monopolar coagulation, or needle-knife incision.<sup>12-15</sup> This incision is typically 2 cm so that larger diverticula would require longer incisions or repeat procedures.<sup>16</sup> This method functionally joins the lumen of the diverticulum with that of the esophagus, thereby relieving the symptoms of dysphagia without actually resecting the diverticulum. Consequently the diverticulum will continue to be visualized on radiographic examination.

### CASE REPORT #1

A 91-year-old female presented with abdominal distention and a left groin bulge as well as several years of progressively worsening dysphagia, first with solids and then with liquids, to the point of a complete inability to swallow without aspiration. During this time she reported food getting stuck in her throat and a critical amount of weight loss. A computed tomography scan showed a left femoral hernia which was reduced on physical examination. While her abdominal distention and acute symptoms resolved, her chronic symptoms were further evaluated. She was diagnosed with a large Zenker's diverticulum protruding into the right superior mediastinum on computed tomography scan and barium swallow (Figure 1a, 1b). Subsequently, she underwent an open, stapled diverticulectomy and cricopharyngeal myotomy through a right cervical incision and a left femoral hernia repair to prevent future incarceration of the hernia. Five days after her surgery, a cine barium swallow demonstrated normal swallowing function without evidence of esophageal leak or obstruction (Figure 1c). Pathology demonstrated a 7 x 6 x 2.3 cm diverticulum with acute and chronic inflammation.

### Figure 1

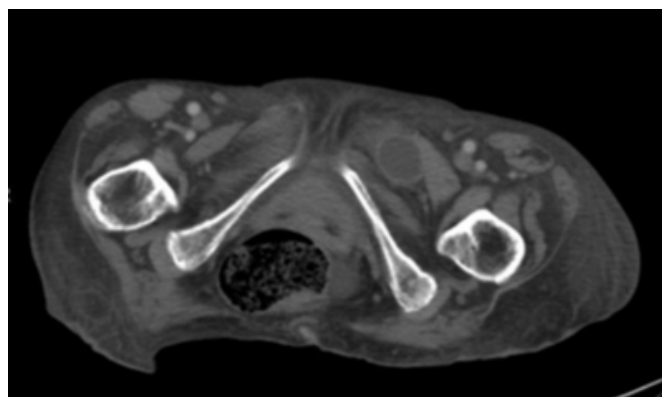
: Figure 1a is computed tomography of the chest depicting the large Zenker's diverticulum resting in the patient's right superior mediastinum. Figure 1b shows a barium esophagram in which contrast remains in the Zenker's diverticulum and fails to pass into the esophagus. Figure 1c is a view of the cine barium swallow confirming the diverticulectomy and passage of contrast through the esophagus.



Although she was tolerating an oral diet after her operation, she became distended and workup revealed a bowel obstruction. She then underwent an exploratory laparotomy and small bowel resection for an incarcerated obturator hernia. Her preoperative computed tomography scan was misinterpreted as a femoral hernia rather than an obturator hernia (Figure 2). Postoperatively, her diet was again gradually advanced with return of bowel function, and she was eventually discharged to a rehabilitation center. Months later, the patient continues to regain her weight.

### Figure 2

: Computed tomography of the pelvis showing a left obturator hernia containing small bowel.



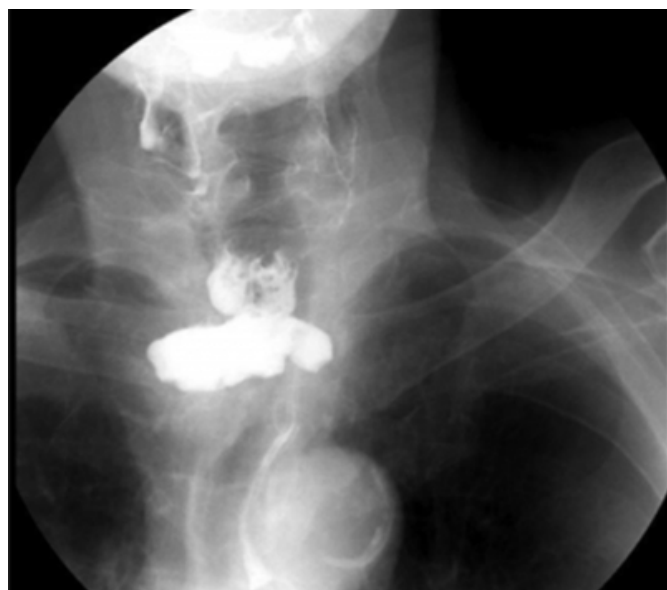### CASE REPORT #2

An 85-year-old male presented with progressive dysphagia for approximately two years and was erroneously thought to have a near-obstructing esophageal mass on barium swallow (Figure 3). He eventually underwent an upper endoscopy with multiple biopsies as well as an open gastrostomy tube placement due to severe malnutrition. The biopsy results

showed only esophagitis, and he was subsequently diagnosed with a Zenker's diverticulum and underwent an open, stapled diverticulectomy and cricopharyngeal myotomy through a left cervical approach. Pathology revealed a 4.3 x 3 x 2.3 cm esophageal diverticulum with focal erosion and acute and chronic inflammation. Postoperatively, the patient did well and was discharged home on postoperative day two tolerating a regular diet.

### Figure 3

: Barium esophagram in the second patient also showing contrast in the Zenker's diverticulum with failure of contrast to pass into the esophagus.



### DISCUSSION

There has been some debate as to which approach is superior for the treatment of ZD. Prior to the advent of the flexible endoscope, open diverticulectomy and cricopharyngeal myotomy was the only option available. Studies have shown that stapled diverticulectomy with cricopharyngeal myotomy is a safe and effective procedure for the treatment of ZD.<sup>17</sup> However, endoscopic treatment of ZD is attractive for higher risk patients and offers the advantage of faster recovery and shorter hospital stay while avoiding the potential complications associated with general anesthesia.<sup>18</sup> This procedure can be performed in the outpatient setting with patients being discharged within six hours. However, one series of 370 patients demonstrated that endostapling of smaller diverticula less than 3 cm was contraindicated because the diverticula could not accommodate a complete staple cartridge resulting in an incomplete myotomy and persistence of symptoms.<sup>19</sup> These findings were confirmed in

a recent prospective study by Rizzetto et al. who showed that endoscopic diverticulostomy was most effective for patients with medium sized diverticula while smaller diverticula should be treated with open myotomy resulting in complete division of the sphincter fibers and lower recurrence rates.<sup>20</sup> On the other hand, another retrospective study by Visosky et al. demonstrated that a diverticulum greater than 3 cm with redundant mucosa was a risk factor for recurrence after endoscopic treatment.<sup>21</sup>

Clearly the choice between open diverticulectomy and cricopharyngeal myotomy versus endoscopic treatment for the management of Zenker's diverticula remains controversial. The choice of approach requires a careful discussion between the surgeon and the patient in order to achieve the optimal outcome with minimal risk. Although the current literature suggests endoscopic therapy is safe and effective, a randomized controlled study comparing stapled diverticulectomy and endoscopic diverticulostomy is required to definitely prove the ideal treatment for symptomatic Zenker's diverticula. The open procedure is our preferred choice, and our results have been excellent with short lengths of hospital stays and no serious complications or recurrences.

### References

1. Ludlow A: A case of obstructed deglutition from a preternatural dilatation of and bag formed in the pharynx. *Medical Observations and Enquiries by a Society of Physicians in London*, 2nd edn.; 1769; 3: 85-101.
2. Zenker FA, von Ziemssen H: *Krankheiten des Oesophagus. Handbuch der Speciellen Pathologie and Therapie*, Vol. 7 (Suppl.); 1877; 1-87.
3. Fulp SR, Castell DO: Manometric aspects of Zenker's diverticulum. *Hepatogastroenterology*; 1992; 39: 123-6.
4. Cook IJ, Blumbergs P, Cash K, et al.: Structural abnormalities of the cricopharyngeus muscle in patients with pharyngeal (Zenker's) diverticulum. *J Gastroenterol Hepatol*; 1992; 7: 556-62.
5. Peters JH, Mason R: The physiopathological basis for Zenker's diverticulum. *Chirurg*; 1999; 70: 741-6.
6. Maran AGD, Wilson JA, Al Muhanna AH: Pharyngeal diverticula. *Clin Otolaryngol*; 1986; 11: 219-25.
7. Watemberg S, Landau O, Avrahami R: Zenker's diverticulum: reappraisal. *Am J Gastroenterol*; 1996; 91: 1494-8.
8. Bowdler DA: Pharyngeal pouches. *Scott Brown's Textbook of Otorhinolaryngology*, 6th edn.; 1997; 1-21.
9. Bradley PJ, Kochaar A, Quraishi MS: Pharyngeal pouch carcinoma: real or imaginary risks? *Ann Otol Rhinol Laryngol*; 1999; 108: 1027-32.
10. Bowdler DA, Stell PM: Carcinoma arising in posterior pharyngeal pulsion diverticulum (Zenker's diverticulum). *Br J Surg*; 1987; 74: 561-3.
11. Ummels C, Konsten J, Janzing H, et al.: Classical operative therapy for Zenker's diverticulum. *Acta Chir Belg*; 2007; 107: 557-9.

12. Narne S, Bonavina L, Guido E, et al.: Treatment of Zenker's diverticulum by endoscopic stapling. *Endosurgery*; 1993; 1: 118-20.
13. Rabenstein T, May A, Michel J, et al.: Argon plasma coagulation for flexible endoscopic Zenker's diverticulotomy. *Endoscopy*; 2007; 39: 141-5.
14. Christiaens P, De Roock W, Van Olmen A, et al.: Treatment of Zenker's diverticulum through a flexible endoscope with a transparent oblique-end hood attached to the tip and a monopolar forceps. *Endoscopy*; 2007; 39: 137-40.
15. Vogelsang A, Preiss C, Neuhaus H, et al.: Endotherapy of Zenker's diverticulum using the needle-knife technique: long term follow-up. *Endoscopy*; 2007; 39: 131-6.
16. Hashiba K, de Paula AL, da Silva JG, et al.: Endoscopic treatment of Zenker's diverticulum. *Gastrointest Endosc*; 2001; 54: 760-3.
17. McLean TR and Haller TC: Stapled diverticulectomy and myotomy for symptomatic Zenker's diverticulum. *Am J Surg*; 2006; 192: 28-31.
18. Ferreira LE, Simmons DT, Baron TH: Zenker's diverticula: pathophysiology, clinical presentation, and flexible endoscopic management. *Dis Esophagus*; 2008; 21: 1-8.
19. Bonavina L, Bona D, Abraham M, et al.: Long-term results of endosurgical and open surgical approach for Zenker diverticulum. *World J Gastroenterol*; 2007; 13: 2586-9.
20. Rizzetto C, Zaninotto G, Costantini M, et al.: Zenker's diverticula: Feasibility of a tailored approach based on diverticulum size. *J Gastrointest Surg*. 2008; 12: 2057-65.
21. Visosky AM, Parke RB, Donovan DT: Endoscopic management of Zenker's diverticulum: factors predictive of success or failure. *Ann Otol Rhinol Laryngol*; 2008; 117: 531-7.

**Author Information**

**Negar M. Salehomoum, M.D.**

Department of Surgery, UMDNJ-Robert Wood Johnson Medical School

**Eric I. Chang, M.D.**

Department of Surgery, UMDNJ-Robert Wood Johnson Medical School

**Steven P. Kahn, M.D.**

Department of Surgery, University Medical Center at Princeton