

Recurring abdominal wall wounds and cutaneous sinus tract formations secondary to spilled gallstones

D Brown, A Wagner, M Aronis, A Isenberg

Citation

D Brown, A Wagner, M Aronis, A Isenberg. *Recurring abdominal wall wounds and cutaneous sinus tract formations secondary to spilled gallstones*. The Internet Journal of Surgery. 2008 Volume 21 Number 1.

Abstract

Introduction: Perforation of an inflamed, gangrenous gallbladder during laparoscopic cholecystectomy inevitably leads to intraoperative spillage of bilious contents and possibly gallstones. In rare cases, spilled gallstones that escape detection during laparoscopic surgical field washout can predispose to multiple types of complications, which are documented in the surgical literature, in the months to years following surgery. **Results and Discussion:** Spilled gallstones can embed within the abdominal wall musculature in the months following laparoscopic cholecystectomy and serve as a nidus for inflammation and infection. This case demonstrates an instance of simultaneous development of chronically draining wounds and complex cutaneous sinus tracts in both the right flank and periumbilical area secondary to spilled gallstones. These complications began one year after laparoscopic cholecystectomy. **Conclusion:** Surgical removal of spilled gallstones is necessary to avoid the rare instances where they produce complications of infection, inflammation, and cutaneous sinus tract formations.

A 70-year-old female patient presented to our service for evaluation of two separate chronically draining abdominal wall wounds refractory to treatment that developed one year after undergoing a laparoscopic cholecystectomy. After several surgical interventions provided only temporary resolution with eventual recurrence of drainage from the wounds, retained gallstones were discovered as the underlying problem. Overall occurrence of gallstone spillage is documented as occurring in 5%-40% of laparoscopic cholecystectomy cases but sequelae of spilled gallstones are quite rare, appearing in only 0.08%-0.3% of patients.¹

CASE REPORT

Seventeen months after undergoing a laparoscopic cholecystectomy with no immediate postoperative complications a 70-year-old female presented to our service for evaluation and treatment of a pair of draining wounds, one at her umbilicus and the other in her right flank.

The wounds were failing to resolve despite an incision and drainage performed by her primary care physician plus a course of antibiotics five months previously. History taking at this time revealed that the patient was not having any fever or chills, but the persistently purulent draining wounds were causing some pain. The rest of the work-up was unremarkable other than the known fact that perforation of a

distended, gangrenous gallbladder had occurred during her laparoscopic cholecystectomy, and the resulting gallbladder content spillage was managed with vigorous warm saline washout. This information appeared to rule out previous operative issues as the source of the current symptomatology, so we proceeded with a repeat incision and drainage of both wounds. The patient tolerated the procedure well and was placed on outpatient wound care.

Two months later the patient presented with near complete resolution of the periumbilical wound but ongoing failure of the right flank wound to heal. Physical examination revealed a sinus tract in the right flank near the twelfth rib measuring four centimeters in length draining purulent material. Since two previous incision and drainage attempts had failed, we proceeded with a surgical exploration under general anesthesia. The exploration revealed several blind sinus tracts that ended at the depth of the chest and abdominal wall musculature. These tracts were opened widely and surrounding chronically inflamed fibrous tissue was debrided. Upon completion of the procedure the wound was packed with saline gauze and a dry dressing was applied. The patient tolerated the procedure well and continued her outpatient wound care.

Four months post right-flank wound exploration and

debridement, the patient returned to the surgical department since her periumbilical wound had acutely worsened. Both the amount of purulent drainage and size of the wound cavity were increasing. During physical examination a sinus tract five centimeters in depth draining purulent material was identified. A surgical exploration under general anesthesia ensued. During the procedure there was an unexpected finding of a 1.1 x 1.0 x 0.8 cm green-black irregular calculus deep within the chronically inflamed tissue debrided. This “foreign body” turned out to be a gallstone that apparently escaped detection when the spilled contents of the perforated gallbladder were aspirated during her prior laparoscopic cholecystectomy. No further calculi were discovered during additional exploration of the wound so it was packed with saline gauze and the patient again began a course of local wound care.

Three months following the periumbilical wound exploration that led to the finding of a spilled gallstone, the patient returned once more for re-evaluation of the right-flank wound which had been surgically explored and debrided seven months previously. Formation of another purulent-draining cutaneous sinus tract four centimeters in depth and with the width of a cotton tip applicator head was found on physical examination. With the suspicion of additional spilled gallstones as the etiology, a computerized tomography scan of the abdomen was ordered. The CT scan confirmed our beliefs, positively identifying two 7-8 millimeter, spherical, calcified densities within the abdominal wall musculature near the right liver edge surrounded by perihepatic fluid and chronic inflammation (Figure 1). In addition to the CT scan, a sinogram of the right flank wound was performed to assess the depth and extent of the sinus tract, as well as the possibility of a biliary-cutaneous fistula. The sinogram showed that the fistulous tract had no connection with the liver, biliary tract, or intra-abdominal cavity (Figure 2).

Figure 1

Figure 1: (A) Axial CT image showing clear visualization of one of two gallstones seeded in the right-flank abdominal musculature. Lateral to the gallstone the right-flank abdominal wound is apparent. The gallstone is surrounded by chronic inflammation/infection and a small amount of associated perihepatic fluid. (B) Axial CT image depicting two spilled gallstones appearing side by side as calcific densities in the right flank.

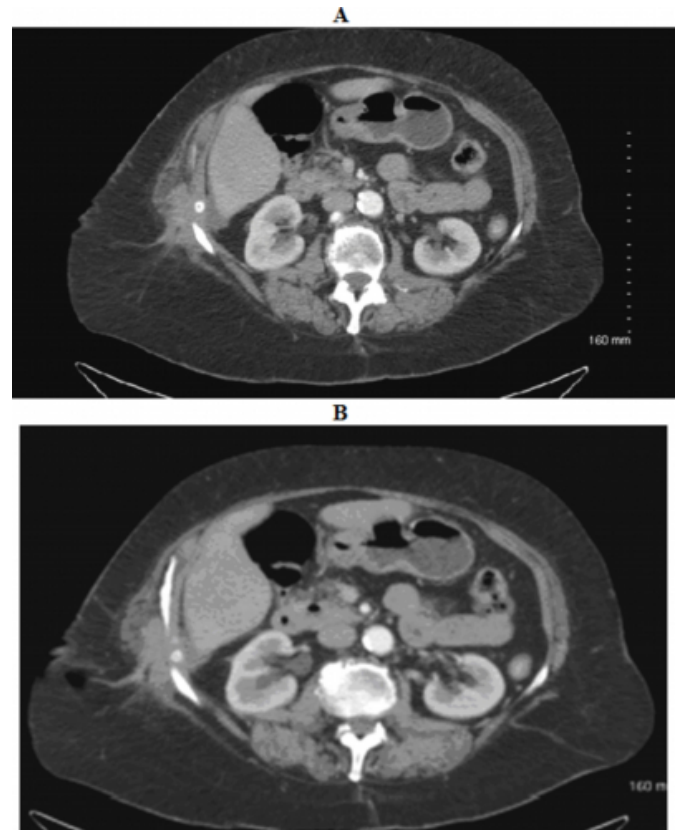
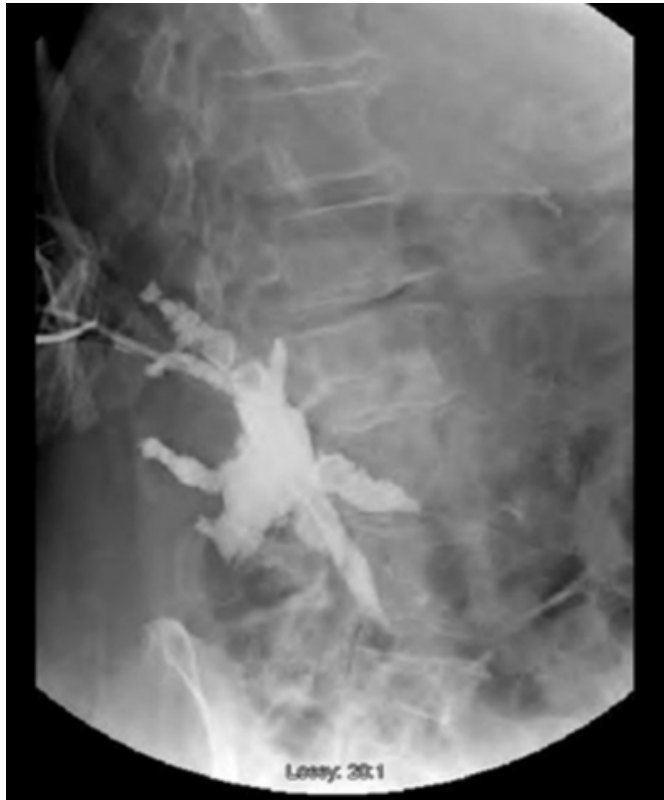

Figure 2

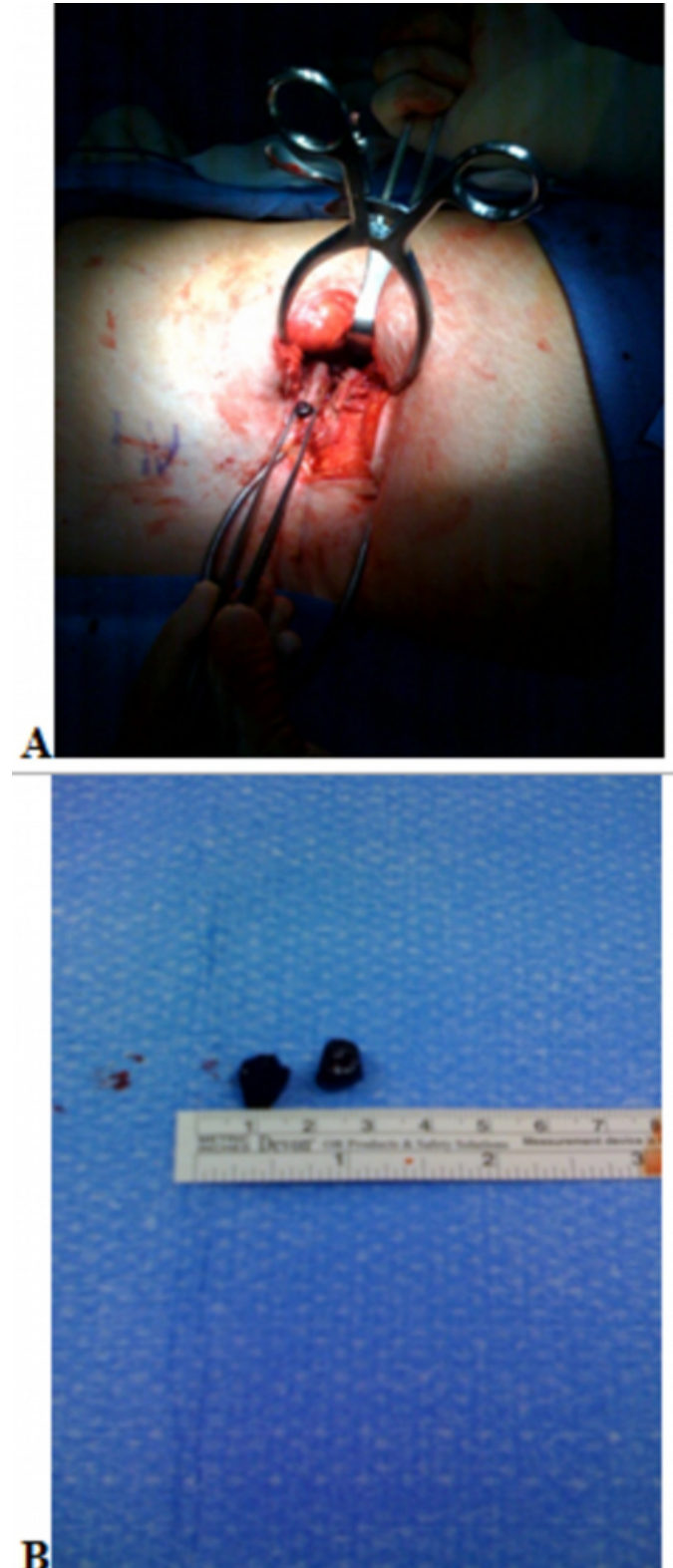
Figure 2: Pre-operative sinogram of right flank showing a complex, stellate shaped sinus below the skin. The contrast material did not enter the intra-abdominal cavity or communicate with any intra-abdominal structures.



Based on the imaging findings, we proceeded to surgically explore the sinus tracts and the cavity containing the embedded gallstones via a right lateral approach. Intraoperatively, a cavity containing two black gallstones, 0.8-1.0 centimeters in size, was located deep to the tip of the twelfth rib (Figure 3). The gallstones were retrieved, chronic scar tissue was debrided, and the fistulous tracts were opened widely to allow for adequate drainage. A negative pressure wound therapy device was applied to aid in post-operative healing. The patient tolerated the operation well and was discharged home from the hospital the following day. Office follow-ups showed the wound to be resolving adequately without evidence of ongoing infection.

Figure 3

Figure 3: () First of two gallstones extracted during surgical exploration of right-flank wound with patient in left lateral decubitus position. () Surgical specimens: Two gallstones that were removed from the right-flank wound.



DISCUSSION

Review of the literature discloses ample discussion pertaining to the benefits of the laparoscopic approach to cholecystectomy as well as the drawbacks, specifically the increased difficulty in locating and retrieving spilled gallstones when a perforated gallbladder is encountered.^{2 4} Gallbladder perforation during laparoscopic cholecystectomy is reported to occur in the range of 10%-40% of cases with subsequent gallstone spillage resulting slightly less frequently.¹

This case proved to be unique in the sense that it involved an uncommon presentation of a rare complication of spilled gallstones when two separate purulent draining abdominal wounds simultaneously formed twelve months post laparoscopic cholecystectomy. Prior to formation of these wounds the patient had a completely uneventful post-operative course. Surgical management of the patient's wounds proved unsuccessful until the spilled gallstones were identified as the source of the problem.

The rarity of this complication along with the lengthy duration between the intraoperative spillage of gallstones and its presentation prolonged the time it took to determine the true etiology of the patient's abdominal wounds failure to heal. The decision to surgically explore the periumbilical wound led to the finding of one spilled gallstone and the logical next step of ordering a CT scan to assess the possibility of other stones causing the right-flank problems. Beyond the finding of two gallstones, the CT scan was also noteworthy since it raised the possibility of another complication of unretrieved gallstones, a biliary-cutaneous fistula. This type of fistula is known to occur when spilled gallstones and accompanying inflammation are found to be

in close proximity to the right liver edge.³ Fortunately, this complication was ruled out by the sinogram study that followed.

CONCLUSION

In general, patients with a history of recent or even remote laparoscopic cholecystectomy who present with unusual abdominal complaints should raise the suspicion of a complication of that surgery. Such postoperative complications include those that present early including bile leakage, hemorrhage, sub-hepatic abscess, and retained bile duct stones, or the more rare complications related to gallstone spillage such as those presented here.^{5 6} Such complications are known to arise days, months, or even years after a laparoscopic cholecystectomy when gallstones have gone unretrieved in the abdominal cavity.

References

1. Sathesh-Kumar T, Saklani AP, Vinayagam, et al. Spilled gall stones during laparoscopic cholecystectomy: a review of the literature. *Postgrad Med J.* 2004;80:77-79.
2. A. Ziya Anadol, Kadir Kilic, Zafer Ferahkoese: One patient with two potential complications of stone spillage during laparoscopic cholecystectomy: The Internet Journal of Surgery. 2006; Volume 7, Number 2.
3. Lau Maurice W, Hall Charles, Brown Timothy. Biliary-cutaneous fistula: an uncommon complication of retained gallstones following laparoscopic cholecystectomy. *Surgical Laparoscopy & Endoscopy.* 1996;6:150-151.
4. Rothlin MA, Schab O, Schlumpf R, et al. Stones spilled during cholecystectomy: a long term liability for the patient. *Surgical Laparoscopy & Endoscopy.* 1997;7:432-4.
5. Yao CC, Wong HH, Yang CC, et al. Abdominal wall abscess secondary to spilled gallstones: late complication of laparoscopic cholecystectomy and preventive measures. *Laparoendosc Adv Surg tech A.* 2001;11:47-51.
6. Duca S, Bala O, Al-Hajjar N, et al. Laparoscopic cholecystectomy: incidents and complications. A retrospective analysis of 9542 consecutive laparoscopic operations. *The Official Journal of the International Hepato-Pancreato-Biliary Association.* 2003;5:152-158.

Author Information

Daniel Brown, B.A.

Medical Student III, Department of General Surgery, Wilson Regional Medical Center, New York College of Osteopathic Medicine

Alan Wagner, M.D.

Clinical Assistant Professor of Radiology at SUNY Upstate Medical University, Department of Diagnostic Imaging, Wilson Regional Medical Center

Michael Aronis, M.D., F.A.C.S.

Attending Physician, Department of General Surgery, Wilson Regional Medical Center

Andrew Isenberg, M.D., F.A.C.S.

Clinical Assistant Professor of Surgery at SUNY Upstate Medical University, Department of General Surgery, Wilson Regional Medical Center