Bone Transport In Chronic Infected Non-Union Using AO External Fixator

G Kazemian, S Kokly, D Adybeik

Citation

G Kazemian, S Kokly, D Adybeik. *Bone Transport In Chronic Infected Non-Union Using AO External Fixator*. The Internet Journal of Orthopedic Surgery. 2003 Volume 2 Number 1.

Abstract

We used AO external fixator for bone transport in 4 patients with chronic osteomyelitis after trauma including 2 cases with femoral shaft fracture (type I and III A), one femoral supracondylar fracture (type III B) and one case with fracture of the proximal of tibia (plateau) type III B. The mean age of the patients was 34.7 years (24-46 years). All fractures were open because of car accident. Internal fixation had been initially carried out for the patients with femoral fracture and calcaneal pin traction for the patient with plateau fracture. The mean time between fracture and the onset of bone transport external fixation was 85 days (24-180 days). All the patients were culture-positive, identified the gram negative bacteria including Pseudomona, E-coli and Enterobacter as the causative pathogens.

The mean of bone defects was 10.2 centimeters (7-14 centimeters).The mean duration of bone transport was 134 days (77-210 days). The total duration of treatment from placing AO external fixator until bringing out the device was 11-25 months (mean, 19.2 months). According to our experience when bone transport carried out by AO external fixator and with use of a five-to-seven day latency period and a rate of distraction of one millimeter per day, approximately 1.9 month treatment (including time for distraction and healing) was required per each centimeter bone defect which is less than the duration of treatment using Ilizarov technique for bone transport requiring 2 to 3 months treatment per centimeter. In our experience major intercalary defects in femur and also tibia have been bridged and new bone has formed in the defect with concomitant restoration of the osseous integrity and alignment of the limb.

INTRODUCTION

Infected non-union is one of the most problematic complications of long bone fractures requiring extensive reconstructive surgery in many cases. The conventional treatment includes extensive debridement, external fixation, bone graft and soft tissue coverage. Radical resection of necrotic bone and bone transport is an alternative treatment ([1], [2]). In this method, bone defects are closed from within sliding a bone fragment internally, producing distraction osteogenesis behind it until the defect is bridged. In most of previous studies regarding bone transport, the Ilizarov technique has been used especially in chronic osteomyelitis of tibia and average bone defects of 6-8 centimeters approximately ([3],[4],[5],[6],[7],[8],[9],[10],[11],[12],[13],[14]). In previous studies, using Ilizarov technique for bone transport has been reported to have good outcomes regarding the management of infection but with considerable soft tissue injuries in large osseous defects particularly in femur. Schmidt, Wittek, Faschingbauer, et al reported high rate of soft tissue injuries using Ilizarov technique bone transport in femur and recommended to use AO external fixator with arc of 90 or 120 degree([14]). There is a paucity of literature regarding the use of AO external fixator for bone transport especially in femoral bony defects due to osteomyelitis. In this study the authors report 4 patients suffering from chronic osteomyelitis successfully treated using AO external fixator for bone transport in Imam Hossein Medical Center.

MATERIAL AND METHODS

We used AO external fixator for bone transport in 4 patients with chronic osteomyelitis after trauma. The primary lab tests including CBC, ESR, CRP were requested for all the patients and then were treated by empiric antibiotic therapy. In cases with hemoglobin less than 10 g/dl blood was transfused in order to reach hemoglobin to more than 10 g/dl. All were prescribed high protein regimen, and then after 1 week we carried out sequestrectomy and bone

transport.

Technique of surgery: After adequate blood reservation and with regard to plain radiography, methylen blue injection the day before surgery and the appearance of bone during operation, i.e., hemorrhage while osteotomy, we defined the extent of bone resection. We tried to spare the adjacent soft tissue as well as the periosteum of proximal and distal bone ends. All the granulation tissue from skin down to the deepest part of the involved area was considered to be infective and was excised. At this time culture from the endosteum of sequester was obtained. Curettage and reaming of proximal and distal bone ends were carried out when necessary. Finally we irrigated bone ends and medulla of proximal and distal bone ends with 10 liter of normal saline and culture was obtained again. The patient was prepared and draped again and the operation set. Then we installed the AO external fixator-unilateral biplane (arc: 80-90 degree). Three shanz of 5 to 6 millimeters in proximal part and three shanz in distal part in one plane were placed and in the other plane two shanz in proximal part and two shanz in distal part and two shanz in the portable assumptive part were placed. In two cases, because of the proximity to the knee, there was a need for knee span. We closed the wound edges together and filled out with sterile gauzes and left it open. All the patients underwent empiric antibiotic therapy after surgery. In next days considering the wound status we started to close the wound gradually. After 10 to 14 days osteotomy with preservation of periosteum and by drill and osteotom was carried out and then a five-to-seven day latency period before applying distraction was allowed. The rate of distraction was 1 millimeter per day (0.5 millimeter in day and 0.5 millimeter in night). A few days after operation toe touch with crutches was commenced. After reaching the free bone fragment to the end of defect, bone graft for docking site was carried out if necessary. Then PWB (partial weight bearing) was started. After bone canalization FWB (full weight bearing) was started and then the device was brought out. The criteria for bone canalization was observation of three cortex in two plane X-ray ([15]).

RESULTS

We evaluated 3 males and one female including two cases with femoral shaft fracture (type I and III A), one femoral supracondylar fracture (type III B) and one case with fracture of the proximal of tibia (plateau) type III B (See table-1). The mean age of the patients was 34.7 years (24-46 years). All fractures were open because of the car accident. Internal fixation had been initially carried out for the 3 cases of femoral fracture and calcaneal pin traction for the case with plateau fracture. All the patients were anemic and three were cachectic. ESR before operation was high and CRP was positive (2-3+) in all the patients. The mean time between fracture and the initial fixation was 26.7 days (16-40 days). The mean time between fracture and the onset of bone transport external fixation was 85 days (24-180 days). All the patients were culture-positive, identified the gram negative bacteria including Pseudomona, E-coli and Enterobacter as the causative pathogens. The culture results after operation were negative in all cases. The direction of bone transport in two cases was proximal to distal and in the other two cases, distal to proximal. The mean of bone defects was 10.2 centimeters (7-14 centimeters) and in patients with femoral fracture the mean of bone defect was 11.3 centimeters. The mean duration of bone transport was 134 days (77-210 days). The total duration of treatment from placing AO external fixator until bringing out the device was 11-25 months (mean, 19.2 months). The mean of duration of treatment (including time for distraction and healing) was 1.9 months per one centimeter defect.

Figure 1

Table 1: Summary of the patients

	Patient No.1	Patient No.2	Patient No.3	Patient No.4
Age	30	46	24	39
Type of fracture (Gustilo classification)	Femoral shaft (III A)	Supracondylar of femur (III B)	Femoral shaft (I)	Plateau of tibia (III B)
Initial fixation device	Plate	Plate	IMN* + Wire	Calcaneal pin traction
Time between fracture and installing AO external fixator	180 days	55 days	80 days	24 days
Sequester	7 cm	13 cm	14 cm	7 cm
Duration of treatment	18 months	25 months	23 months	11 months
Bone graft of docking site	+	+	-	-
Complications:				
Re-infection	-	-	-	-
Superficial infection of shanz	+	+	+	-
Loosening of shanz	+	+	-	-
Premature consolidation	+	-	+	-
Re-fracture	+	-	-	-
Mal-alignment	-	+	-	-
Neurovascular injury	-	-	-	-
Preoperative problems	Addict, Anemic Cachectic	Anemic Cachectic	Anemic Cachectic	Anemic

*IMN=Intra Medullary Nailing

DISCUSSION

AO external fixator, if using unilateral biplane, is more stable in comparison with using unilateral monoplane; and there is no need to use Ilizarov apparatus which is certainly suitable for mechanical correction of deformities such as angulation and rotation. Moreover in bone transport using AO external fixator, unlike Ilizarov technique, there is not a

high rate of soft tissue injuries ([14]). In our study the extent of bone defect (mean: 10.2 centimeters in four cases and mean of 11.3 in cases with femoral fracture) was relatively more extensive in comparison with previous studies. Previous studies using Ilizarov technique for bone transport were mostly about chronic osteomyelitis of tibia. Bone transport using AO external fixator appears to be an efficacious technique in the treatment of large defects including those in femur. In our experience, major intercalary defects in femur and also tibia have been bridged and new bone has formed in the defect with concomitant restoration of the osseous integrity and alignment of the limb. (See figure 1, 2 and 3).

Figure 2

Figure 1: Patient No.3. A: Chronic osteomyelitis before reconstruction. B: After radical resection and before osteotomy. C: Two weeks after osteotomy. D: Free bone fragment in progress.



Figure 3

Figure 2: Patient No.3. A & B: Docking site and distraction osteogenesis behind it.

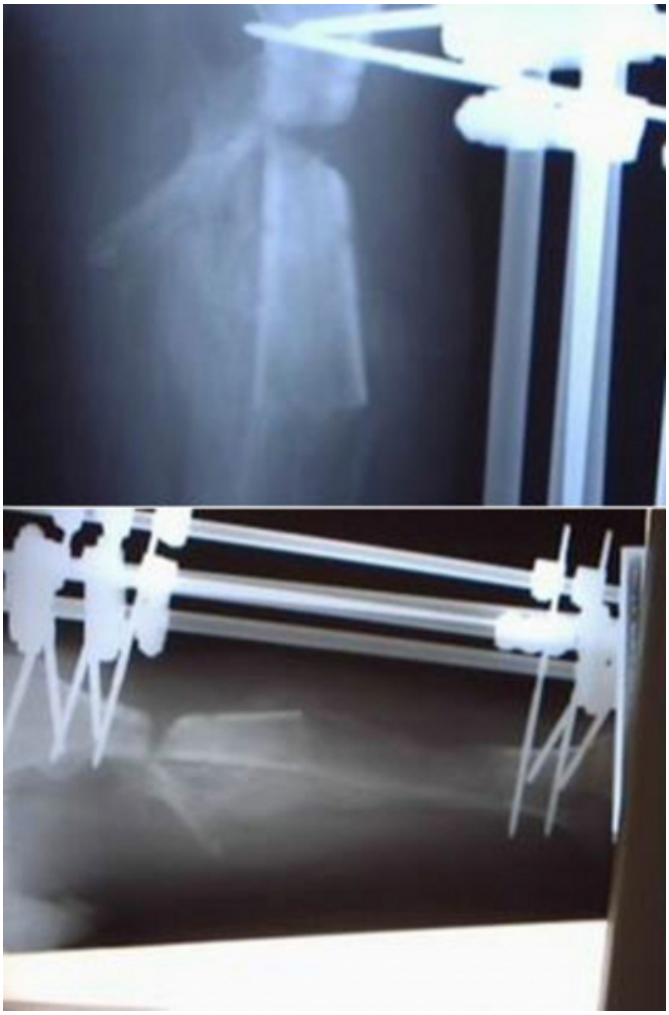

Figure 4

Figure 3: Patient No.4. A: Skin condition after reconstruction. B: The patient condition after reconstruction and skin graft.

According to our experience when bone transport carried out by AO external fixator and with use of a five-to-seven day latency period and a rate of distraction of one millimeter per day, approximately 1.9 month treatment (including time for distraction and healing) was required per each centimeter bone defect which is less than the duration of treatment using Ilizarov technique for bone transport requiring 2 to 3 months treatment per centimeter ([16]). It seems that the less time between fracture and using AO external fixator for bone transport the better treatment outcomes and less complication. Interestingly, in cases where internal fixation was not used as the initial treatment, the result of treatment was remarkably better. Generally, the better general condition before operation, the better treatment outcomes. Bone graft in docking site was carried out in 2 cases; however, it is suggested to be done prophylactically in order to decrease the duration of treatment ([16]). In addition, in our experience there was neither any re-infection nor a need for amputation in any of the cases. Bone transport using AO external fixator is an alternative treatment in the salvage of limbs with infected non-union that may otherwise have been amputated, and it returns disabled patients to normal life and a productive level of activity.

Considering our experience and previous studies, it is recommended to diagnose and treat post-trauma infection as soon as possible since otherwise if treatment is delayed, as unfortunately is often the case, the progressive soft tissue and bone destruction will occur and aggressive surgical intervention might incur ([2]). We also suggest that regarding the paucity of existing literature using AO external fixator for bone transport and also the small number of our studied patients, more studies have to be conducted about this method.

References

1. Prokuski LJ, Marsh JL. Segmental bone deficiency after acute trauma: The role of bone transport. Orthop Clin North Am. 1994 Oct; 25(4): 753-63.
2. Bucholz RW, Heckman JD. Rockwood and Green's Fractures in Adults, Fifth edition, Lippincott Williams & Wilkins; 2002 page: 1988
3. Cattaneo R, Catagni M, Johnson EE. The treatment of infected nonunions and segmental defects of the tibia by the methods of Ilizarov. Clin Orthop. 1992 Jul; (280): 143-52.
4. Carballedo J, Schmauch M, Langa J, Miralles RC. Type III-B open tibial fractures in Mozambique. A prospective study of 50 cases. Int Orthop. 1996; 20(5): 300-4.
5. Dendrinos GK, Kontos S, Lyritsis E. Use of the Ilizarov technique for treatment of non-union of the tibia associated with infection. J Bone Joint Surg Am. 1995 Jun; 77(6): 835-46.
6. Golyakhovsky V, Frankel VH. Ilizarov bone transport in large bone loss and in severe osteomyelitis. Bull Hosp Jt Dis Orthop Inst. 1991 Spring; 51(1): 63-73.
7. Green SA. Osteomyelitis. The Ilizarov perspective. Orthop Clin North Am. 1991 Jul; 22(3): 515-21.
8. Green SA, Jackson JM, Wall DM, Marinow H, Ishkanian J. Management of segmental defects by the Ilizarov intercalary bone transport method. Clin Orthop. 1992 Jul; (280): 136-42.
9. Paley D, Catagni MA, Argnani F, Villa A, Benedetti GB, Cattaneo R. Ilizarov treatment of tibial nonunions with bone loss. Clin Orthop. 1989 Apr;(241):146-65.
10. Smrke D, Arnez ZM. Treatment of extensive bone and soft tissue defects of the lower limb by traction and free-flap transfer. Injury. 2000 Apr; 31(3): 153-62.
11. Song HR, Cho SH, Koo KH, Jeong ST, Park YJ, Ko JH. Tibial bone defects treated by internal bone transport using the Ilizarov method. Int Orthop. 1998; 22(5): 293-7.
12. Theis JC, Simpson H, Kenwright J. Correction of complex lower limb deformities by the Ilizarov technique: An audit of complications. J Orthop Surg (Hong Kong). 2000 Jun; 8(1): 67-71.
13. Prochaska VJ ,Lindgren JU. Treatment of chronic tibial osteomyelitis, segmental bone loss, soft tissue damage by bone transport. Nebr Med J. 1994 Oct,79(10): 349-52

14. Schmidt HG, Wittek F, Faschingbauer M, Fink B. [Treatment of chronic osteitis of the femur] Unfallchirurg. 1992 Nov; 95(11): 562-5.
15. Morrissy RT, Weinstein SL, Lovell and Winters Pediatric Orthopedics, 5th Ed.; William and Wilkins; 2001 p: 1136-45
16. Aronson J, Rock L: Current concepts review-limb lengthening, skeletal reconstruction and bone transport with Ilizarov method, J BJ S, 79: 1243-58

Author Information

Gholamhossein Kazemian, M.D.
Assistant Professor, Department of Orthopaedic Surgery, Imam Hossein Medical Center, Shahid Beheshti University of Medical Sciences

Saeed Kokly, M.D.
Chief resident of Orthopaedic Surgery, Department of Orthopaedic Surgery, Imam Hossein Medical Center, Shahid Beheshti University of Medical Sciences

Dariush Adybeik, M.D.
Clinical Researcher, Department of Orthopaedic Surgery, Imam Hossein Medical Center, Shahid Beheshti University of Medical Sciences