

Long term survival with a metallic mitral valve prosthesis on no anticoagulation or antiplatelet therapy. A case presentation.

J Perez-Zaldivar, L Orjiako, S Tutunovic

Citation

J Perez-Zaldivar, L Orjiako, S Tutunovic. *Long term survival with a metallic mitral valve prosthesis on no anticoagulation or antiplatelet therapy. A case presentation.*. The Internet Journal of Cardiology. 2009 Volume 9 Number 1.

Abstract

Adequate anticoagulation is extremely important in patients with cardiac valve prosthesis because of the permanent risk of embolism or thrombosis of the valve. We present a curious case of a patient that never took any kind of anticoagulant for ten years after a mitral valve prosthesis, St Jude type, was implanted; and only after a decade presented with an embolism to the cerebellum. We highlight both: the possibility of long term survival and the permanent risk of thromboembolism without proper anticoagulation.

INTRODUCTION

More than 50 years have past since the first artificial cardiac valve was implanted¹, since the very early models it was evident that thrombosis and embolism were serious complications, therefore anticoagulation was a long-life need, creating a new problem: excessive anticoagulation and bleeding². An artificial valve exposes a large surface of a foreign material to the blood provoking activation of the coagulation cascade and thrombus formation. Although survival without anticoagulation has been reported before³, it is extraordinary that a patient with a metallic mitral valve without any anticoagulation experienced his first embolic episode only ten years after the device was implanted.

CASE PRESENTATION

A 26-year-old male patient, from a rural area of northern South Africa, with a past medical history of a "heart operation" ten years prior admission, presented to ED complaining of impossibility to stand and walk of one day duration. The patient underwent a cardiac operation when he was 16 year-old but he didn't know any detail about it; after being discharged he felt so well that never came for follow-up or took medication of any kind. The day of admission he developed dizziness, unstable gait of sudden onset, and later inability to walk, felt "like being drunk". No headache, vomiting or tremor was reported.

On examination he was found to have a truncal ataxia,

diminished tone of the right limbs and dysmetria and intention tremor of the right upper limb. No nystagmus or motor deficit was found. Cardiovascular examination revealed a midsternal surgical scar, and a metallic click better heard at the apex. The pulse was regular at 88 per minute and the BP 142/71 mmHg.

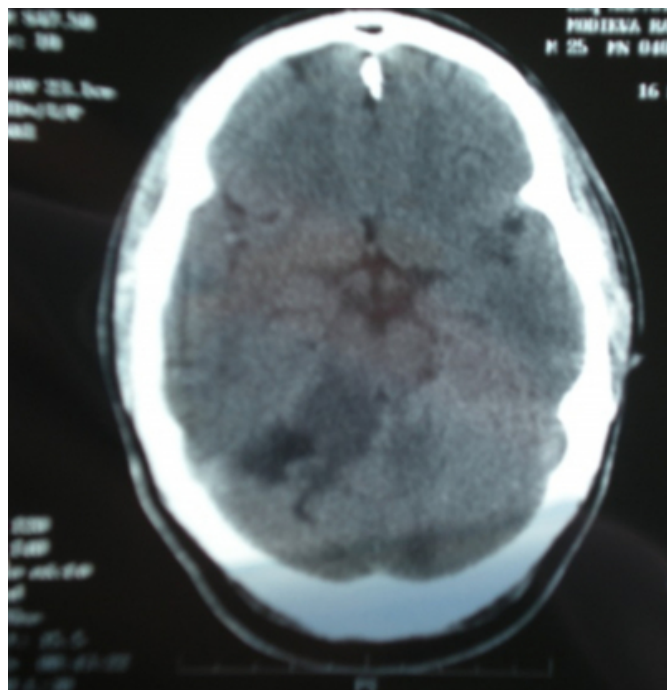
EKG showed a sinus rhythm, QRS axis at 30°, no signs of atrial or ventricular enlargement. A chest x ray showed a cardiac silhouette of normal size, a typical ring of valve prosthesis could be seen at mitral position and no signs of lung congestion.

An echocardiogram showed a mechanical valve prosthesis in mitral position, mildly dilated left atrium, good contractility, EF: 50% and no intracavitary clot. INR:1.1, rest of clotting profile, full blood count, liver function test and renal function were normal. A Brain CT disclosed a cerebellar infarct affecting mainly the anterior vermis and almost half of the right cerebellar hemisphere. Fig 1. The patient was anticoagulated and discharged, when seen after four weeks all neurologic signs had disappeared; since then he remains asymptomatic.

According with a thoracic surgeon this patient received a St Jude mitral valve prosthesis in 1998.

Figure 1

Figure 1



DISCUSSION

This is a curious case of a patient who went on without any anticoagulation, not even antiplatelet medication, after a mechanical mitral valve prosthesis implant for more than ten years without any complication, until he finally suffered and embolism to the cerebellum. Although it had a happy ending it also highlights the importance of proper anticoagulation in patients with metallic valve prosthesis despite the great technical improvements achieved in the last decade in artificial valve technology.

The long survival of patients with mechanical valve prosthesis has been documented before by seminal studies^{2,3}. It has been reported that prosthesis in aortic position has much better chances of surviving without embolic episodes than those in mitral², but in any case there is always the possibility of major embolic episodes or, even worse, valve thrombosis that carries a high mortality and a need for urgent surgical intervention. Andersen and Alstrup reported an

incidence of 5.2 % of thromboembolic episodes/year in patients on no anticoagulant after aortic prosthesis²; similar figures, 5.1 %, were reported by Horstkotte et al in patients receiving coumarinics but including valves in the two main positions, mitral and aortic, plus double valve replacement, indicating the considerable much higher risk when the mitral valve is involved⁴, already calculated to be twice in comparison with prosthesis in aortic position⁴. The St Jude type of prosthesis has shown the best performance in mitral position with an incidence of only 0.7 to 1.5 %/year of thromboembolic events^{5,6}, which we think contributed to the “good luck” of our patient.

This case shows two apparently contradictory facts: first that with a metallic valve prosthesis, even in a mitral position, and no anticoagulation at all a long term survival free of thromboembolism or valvular thrombosis is still possible, especially if a St Jude type of valve has been used; on the other hand many years without complications despite not being taking anticoagulation do not rule out any life-threatening event at any time.

References

1. Rose JC, Hufnagel CA, Freis ED, et al. The hemodynamic alterations produced by a plastic valvular prosthesis for aortic insufficiency in man. *J Clin Invest.* 1954 June; 33(6): 891–900
2. Andersen, PV and Alstrup, P. Long-term survival and complications in patients with mechanical aortic valves without anticoagulation. A follow-up study from 1 to 15 years. *European Journal of Cardio-Thoracic Surgery* 1992; 6: 62-65
3. Pass HI, Sade RM, Crawford FA and Hohn AR. Cardiac valve prostheses in children without anticoagulation. *Journal of Thoracic and Cardiovascular Surgery* 1984;87:832-835
4. Horstkotte D, Schulte H, Bircks W, Strauer B. Unexpected findings concerning thromboembolic complications and anticoagulation after complete 10 year follow up of patients with St. Jude Medical prostheses. *J Heart Valve Dis.*1992;2(3):291-301
5. Arom KV, Nicoloff DM, Kersten TE, Northrup 3d WF, Lindsay WG and Emery RW. Ten years' experience with the St. Jude Medical valve prosthesis. *Annals of Thoracic Surgery*, 1989,47:831-37
6. Remad JP, Baron O, Roussel C et al. Isolated Mitral Valve Replacement With St Jude Medical Prosthesis Long-Term Results: A Follow-Up of 19 Years. *Circulation* 2001; 103; 1542-1545

Author Information

Jose Ignacio Perez-Zaldivar, MD

Department of Internal Medicine, Polokwane-Mankweng Hospital, South Africa.

Livinus Obiora Orjiako, MBChB

Department of Internal Medicine, Polokwane-Mankweng Hospital, South Africa.

S. Tutunovic, MD

Department of Internal Medicine, Polokwane-Mankweng Hospital South Africa.