

Intradural Extramedullary Spinal Cord Tumors: A Retrospective Study of Tumor Types, Locations, and Surgical Outcomes

S Stawicki, J Guarnaschelli

Citation

S Stawicki, J Guarnaschelli. *Intradural Extramedullary Spinal Cord Tumors: A Retrospective Study of Tumor Types, Locations, and Surgical Outcomes*. The Internet Journal of Neurosurgery. 2006 Volume 4 Number 2.

Abstract

Introduction: Intradural extramedullary spinal cord tumors (IESCT) account for approximately two thirds of all intraspinal neoplasms. The purpose of this report was to determine short- and long-term outcomes of surgical patients with IESCT, and to examine clinical features that could be helpful in management of patients with these lesions.

Methods: A retrospective review of 67 operative IESCT cases between 1974 and 2001 was performed. Outcomes were scored at one month and at mean follow-up of 8.5 months postoperatively. In addition, patient demographics, tumor types and locations were also collected. Statistical analysis was conducted utilizing Chi-square and Student's t-tests.

Results: There were 31 men and 36 women (mean age 48 y/o, range 18-87 y/o). Men presented at a younger age than women (44 vs 53 y/o, $P < 0.02$). Fifty-seven (85%) patients presented with severe radiculopathy and/or myelopathy. The remaining 10 (15%) had symptoms typical of disc herniation. Mean duration of symptoms prior to diagnosis was 11 months. Schwannomas (36 patients) had the longest mean duration of symptoms (14.9 months), followed by meningiomas (21 patients, 8.4 months), and ependymomas (10 patients, 2 months). Sixty-three (94%) of patients demonstrated significant improvement at one-month and 62 (92%) at 8.5-month mean follow-up as compared to the index exam. Only 13/67 (19.4%) patients had residual focal deficits on long term follow-up.

Conclusions: Surgery for IESCT should be expected to produce significant and dramatic improvement in great majority of patients. Demographic, tumor-specific and anatomic considerations may be clinically useful when approaching IESCT.

INTRODUCTION

Spinal tumors account for only approximately 5-15% of the nervous system neoplasms (1, 2). Intradural extramedullary spinal cord tumors (IESCT) constitute approximately two thirds of these tumors (2, 3). Relatively few published reports have sufficient sample sizes to adequately analyze surgical outcomes, demographics, symptoms, and data on tumor types and locations (3,4,5,6). The most commonly encountered types of IESCT are schwannomas and meningiomas, with myxopapillary ependymomas encountered less frequently. The primary objective of this study was to examine surgical outcomes following procedures for IESCT in a large retrospective cohort of patients. Secondary goals included examination of clinical data pertaining to demographics, symptoms, tumor location and type that could be helpful in clinical decision making.

MATERIALS AND METHODS

This is a retrospective study of 67 surgical patients who underwent operative removal of IESCT between September 1974 and May 2001. Parameters recorded include patient demographics, symptoms (severity and duration), tumor characteristics (anatomic and pathologic), postoperative follow-up and surgical outcomes.

Surgical intervention was indicated by a combination of presenting symptoms (radiculopathy and/or myelopathy) and radiographic findings of magnetic resonance imaging (MRI), and computed tomographic (CT)-myelography. The neuroimaging procedure of choice was contrast-enhanced MRI. CT-myelography was used in selected patients. Angiography was helpful in cervical dumbbell-shaped lesions.

Patient charts were reviewed by one of the authors (SPS or JJG) and pertinent chart data was recorded in a computerized database (Microsoft Excel, Redmond, WA, USA). Surgical outcomes were scored at 1 month and then at the mean follow-up period. The mean follow-up was calculated from the interval between surgery and the last complete clinical examination in the patient chart (in this study, 8.5 months). Patient records were carefully reviewed and surgical outcomes were scored strictly according to the modified criteria of Odom, et al (Table 1) (7).

While recognizing the shortcomings of the Odom's criteria as a 'rough' outcome and morbidity assessment scale, we chose to use this method because of the uniform and standardized recording of these criteria in all of our patient charts.

Statistical analysis was conducted using the SPSS software (SPSS, Inc., Chicago, IL, USA). Descriptive statistics, Chi-square test and Student's t-test were utilized for data analysis. Statistical significance was set at alpha = 0.05.

Figure 1

Table 1: Modified Criteria of Odom, et al (7).

<i>Excellent</i>	complete relief of pain and other symptoms*, return to full activity
<i>Good</i>	partial relief of pain, complete relief of other symptoms*, return to full activity
<i>Fair</i>	improvement with persistent limitation of activities
<i>Poor</i>	no improvement or further deterioration

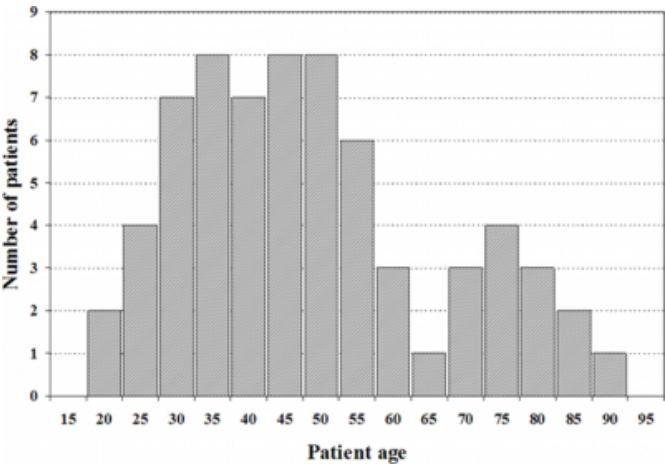
*note other symptoms = paresthesias, paresis, sensory loss

RESULTS

There were 36 women and 31 men (mean age 48.81±16.46 y/o, median 45.5 y/o, range 18-87 y/o). Overall, men presented at a younger age than women (44.1 vs 53.5 y/o, P<0.02). The age distribution was bimodal with a major peak around 40 y/o and a minor peak at approximately 70 y/o (Figure 1).

Figure 2

Figure 1: The bimodal age distribution of intradural extramedullary spinal cord tumors in our series. The second peak around age 70 represents predominantly older meningioma patients, whereas the peak around age 40 represents most schwannoma and ependymoma patients.



There were three primary tumor types: schwannomas (36/67), meningiomas (21), and myxopapillary ependymomas (10/67) (Table 2A). Schwannomas were noted to be more common in men, meningiomas more common in women, and ependymomas distributed equally (Table 2A). Patients with meningiomas tended to be older (57.5 y/o) than those with schwannomas (45.0 y/o) and ependymomas (40.5 y/o, P<0.01) (Table 2B). Tumor locations varied between the three tumor types in a predictable fashion (Table 2C). While schwannomas were distributed fairly evenly among the three anatomic regions (cervical, thoracic, and lumbosacral), meningiomas predominated in the cervical and thoracic locations and ependymomas were predictably localized to the lumbar region. Of note, the ratio of Schwannomas to Meningiomas to Ependymomas was approximately 4:2:1 in this study (actual ratio 36:21:10).

The mean duration of symptoms before diagnosis was 11.3 months. Schwannomas had a statistically longer duration of symptoms (14.9 months) than did meningiomas (8.4 months, P<0.05) for cervical and thoracic tumors. Ependymomas had shorter duration of symptoms (2.0 months) than schwannomas (10.8 months, P<0.05) for lumbosacral tumors.

Out of 67 patients, 63 (94.0%) had Excellent or Good results at one month, and 62 (92.5%) had Excellent or Good results at 8.5 months postoperatively (the mean follow-up, range 1.5 to 36 months). At the one month follow-up, 37.3% (25/67)

patients had Excellent results, 56.7% (38/67) had Good results, 4.5% (3/67) had Fair results, and 1.5% (1/67) had Poor result. The patient with a Poor result at one month follow-up had very severe presenting symptoms, had little immediate post-surgical improvement, but was upgraded to the Fair result upon subsequent follow-up.

At mean follow-up of 8.5 months (range 1.5 to 36 months), overall outcomes improved significantly. Forty-one patients (61.2%) had Excellent results, 32.8% (22/67) had Good results, and 6.0% (4/67) had Fair results. Although at the 8.5 months mean follow-up the number of patients with Fair results increased by 1, none of the patients had Poor results. The number of patients with Excellent results increased by 64% and the number of patients with Good results decreased by 42% (largely upgrades to Excellent). Only one patient with a previously Good result was downgraded to a Fair result. Only 13/67 (19.4%) patients had residual focal deficits on long term follow-up.

Three patients had multiple IESCT, all of which were schwannomas. Two of these patients were NF-II positive. Four patients developed recurrence of their IESCT. Three of these were schwannomas and one was an ependymoma. Two patients with recurrent dumbbell-shaped schwannomas within the soft tissues of the neck underwent surgical treatment with acceptable results (one patient returned with new symptoms 5 years after initial tumor excision while another patient re-presented 15 years after the initial surgical resection). One patient with recurrent ependymoma at 4 years following initial surgery underwent a successful course of radiotherapy, and one patient with schwannoma underwent non-operative semi-annual observation for a localized radiographic recurrence.

While no metastases were noted during the 8.5-month mean followup period (range 1.5 to 36 months), this study did not specifically examine whether metastatic disease did appear at a later time. No mortality was noted in this series, and the only complications included a superficial wound infection and self-limited hoarseness in one patient each.

Figure 3

Table 2: Histologic, demographic, and anatomic considerations for IESCT

A. Distribution of tumors by histologic type and patient gender in this series			
Patient gender	Total	Men	Women
Schwannoma	36 (53.7%)	22	14
Meningioma	21 (31.3%)	4	17
Ependymoma	10 (14.9%)	5	5
Total	67	31	36
B. Tumor incidence by age group			
Age	<40	40-60	>60
Schwannoma	15	15	6
Meningioma	1	12	8
Ependymoma	5	2	3
Total	21	29	17
C. Tumor incidence by anatomic location			
Location	Cervical	Thoracic	Lumbar
Schwannoma	10	12	14
Meningioma	6	15	0
Ependymoma	0	0	10
Total	16	27	24

DISCUSSION

Surgery for IESCT is the best treatment option producing excellent overall results, with complete microsurgical excision being the modality of choice (6, 8). Modern techniques enable good surgical outcomes with minimal morbidity and mortality (2,3, 6, 9). The current series corroborates this contention in that mostly Excellent or Good results were achieved with few complications. In fact, no Poor results were noted in this study at the mean 8.5-month follow-up. Our findings agree with those of others, with majority of clinical improvement noted either immediately or within 6 months of the operative intervention, with less notable clinical change after this initial period (3). Other studies reported that duration of preoperative symptoms appears to correlate with postoperative improvement, and that successful complete microsurgical tumor excision is of utmost importance (2, 10,11). In terms of mortality, our result correlate well with other series, with a reported range between 0-4.4% (2, 5, 12,13).

Approximately 20% of patients in this study experienced residual focal deficits, none of which were disabling. Others report similar outcomes among patients with similarities to

our patient sample, with significant improvement in 62-88% of cases and clinical worsening in only a minority of patients (1-5%) (2,3). Some of the patient outcomes and functional scores on discharge and/or follow-up may differ across studies because of different assessment tools being used by different authors (2,3).

The demographics in this series are similar to those in previous studies (2, 6). We found that while schwannomas affected younger male patients, meningiomas tended to occur in women and older patients. Patients with myxopapillary ependymomas were younger than patients with schwannomas. A brief discussion of each of the three tumor types, as it pertains to findings of this study, follows.

Reported frequencies of schwannomas among IESCT vary from 43% to 67% in other studies (53.7% in this series) (2, 6, 14,15). Schwannomas tend to produce localized pain, radiculopathy, and cauda equina syndrome. Most report schwannomas to be solitary, with a 2.5% malignancy rate, which carries a poor prognosis (16). In this study, schwannomas were the only group of tumors without a predominant location of occurrence, and constituted 75% of recurrent tumors.

In this series, patients with meningiomas were older than those with other tumor types. Findings in this series agree with the literature in that meningiomas are the second most common IESCT, with approximately 80% localized to the thoracic region (71% in this series) (6, 10, 16,17). Between 75% to 85% of patients with meningiomas are women (81% in this series), who tend to be older than patients with schwannomas or ependymomas (6, 10, 16). Consistent with previous reports, we found meningiomas to be more aggressive in younger patients, with the higher incidence of myelopathy likely due to predilection of meningiomas for the thoracic region (18). Others describe higher operative morbidity associated with IESCT located in the thoracic region (6). Meningiomas tend to produce the “dural tail” sign on MRI scans in sagittal, axial, and coronal planes, and it is recommended that all three planes of visualization be used (19). We follow this recommendation because as many as 10% of meningiomas can be both intradural and extradural (20).

Myxopapillary ependymomas constitute 14.9 % of IESCT in this study, and although in this study ependymomas had equal distribution among men and women, another series reported twice as many men as women (21). In this series, the

mean age of the ependymoma group was lower than the mean age of patients with meningioma or schwannoma. Symptomatically, ependymomas tended to produce cauda equina syndrome, localized pain, and radiculopathy.

A 4:2:1 ratio of schwannomas to meningiomas to ependymomas was observed in this series. Although not specifically described by others, similar ratio of tumor types can be noted in previous reports (2, 6, 15).

Limitations of this study include its retrospective nature, lack of patient followup data beyond the 8.5-month mean followup period, lack of complete data on recurrences or metastases beyond the end of the study period, and the drawbacks of the Odom's modified criteria as a measurement tool for morbidity. The authors acknowledge that the Odom's modified scale is a very 'rough' instrument of outcome assessment and does not have the capacity to truly delineate actual morbidity. The Odom's scale was chosen for this study because of standard and uniform reporting of this scale on our patient charts. Although the use of scales such as SF-36 or Nurick grading would greatly enhance this study, the long period of this study as well as the difficulty of assigning these scales in a retrospective fashion to every patient in this series, make their applicability impractical (22, 23).

CONCLUSIONS

Surgery for IESCT, with goal of complete tumor removal, is a safe and effective option. At the 8.5-month mean follow-up, majority of patients had complete or near complete relief of symptoms and return to full activity. In others, symptoms stopped progressing, and none of the 67 patients worsened. Schwannomas and ependymomas were the only histologic types to recur. Demographic, tumor-specific and anatomic considerations may be clinically useful when approaching IESCT.

CORRESPONDENCE TO

S. Peter Stawicki, MD 304 Monroe Blvd King of Prussia, PA 19406 Phone: (215) 588-5153 E-mail: stawicki_ace@yahoo.com

References

1. Porchet F, Sajadi A, Villemure JG. Spinal tumors: clinical aspects, classification and surgical treatment. *Schweiz Rundsch Med Prax.* 2003;92:1897-1905.
2. Hufana V, Tan JSH, Tan KK. Microsurgical treatment for spinal tumors. *Singapore med J.* 2005;46:74-77.
3. Albanese V, Platania N. Spinal intradural extramedullary tumors. Personal experience. *J Neurosurg Sci.*

- 2002;46:18-24.
4. Slin'ko EI, Al-Qashqish II. Intradural ventral and ventrolateral tumors of the spinal cord: surgical treatment and results. *Neurosurg Focus*. 2004;15:ECP2.
5. Peker S, Cerci A, Ozgen S, Isik N, Kalelioglu M, Pamir MN. Spinal meningiomas: evaluation of 41 patients. *J Neurosurg Sci*. 2005;49:7-11.
6. Prevedello DM, Koerbel A, Tatsui CE, Truite L, Grande CV, Ditzel LF, Araujo JC. Prognostic factors in the treatment of the intradural extramedullary tumors: a study of 44 cases. *Arq Neuropsiquiatr*. 2003;61:241-247.
7. Odom GL, Finney W, Woodhall B. Cervical disk lesions. *JAMA*. 1958;166:23-28.
8. Yasargil MG, DeLong WB, Guarnaschelli JJ: Complete microsurgical excision of cervical extramedullary and intramedullary vascular malformations. *Surg Neurol*. 1975;4:211-24.
9. Schaller B. Spinal meningioma: relationship between histological subtypes and surgical outcome? 2005;75:157-161.
10. Gelabert-Gonzalez M. Primary spinal cord tumors. An analysis of a series of 168 patients. *Rev Neurol*. 2007;44:269-274.
11. Sandalcioğlu IE, Gasser T, Asgari S, Lazorisak A, Engelhorn T, Egelhof T, Stolke D, Wiedemayer H. Functional outcome after surgical treatment of intramedullary spinal cord tumors: experience with 78 patients. *Spinal Cord*. 2005;43:34-41.
12. Allen JC, Aviner S, Yates AJ, Boyett JM, Cherlow JM, Turski PA, et al. Treatment of high-grade spinal cord astrocytoma of children with "8 in 1" chemotherapy and radiotherapy: a pilot study of CCG-945. *Children's Cancer Group. J Neurosurg*. 1998;88:215-220.
13. Cohen AR, Wisoff JH, Allen JC, Epstein F. Malignant astrocytomas of the spinal cord. *J Neurosurg*. 1989;70:50-54.
14. el-Mahdy W, Kane PJ, Powell MP, Crockard HA: Spinal intradural tumors: Part I - Extramedullary. *Br J Neurosurg*. 1999;13:550-557.
15. Garrido P, Laher-Mooncey S, Murphree NL, Jonker N, Levy LF, and Makarawo S. Neoplasms involving the spinal cord in Zimbabweans: an analysis of 262 cases. *Cent Afr J Med*. 1994;40:201-204.
16. Fromme K, Miltner FO, Klawki P, Friedrich M. Spinal cord monitoring during intraspinal extramedullary tumor operations (peroneal nerve evoked responses). *Neurosurg Rev*. 1990;13:195-9.
17. Gelabert-Gonzalez M, Garcia-Allut A, Martinez-Rumbo R. Spinal meningiomas. *Neurocirurgia (Astur)*. 2006;17:125-131.
18. Cohen-Gadol AA, Zikel OM, Koch CA, Scheithauer BW, Krauss WE. Spinal meningiomas in patients younger than 50 years of age: a 21-year experience. *J Neurosurg*. 2003;98:258-63.
19. Queckel LG, Versteeg CW. The "dural tail sign" in MRI of spinal meningiomas. *J Comput Assist Tomogr*. 1995;19:890-2.
20. Souweidane MM, Benjamin V. Spinal cord meningiomas. *Neurosurg Clin North Am*. 1994;5:283-291.
21. Wippold FJ 2nd, Smirniotopoulos JG, Moran CJ, Suojanen JN, Vollmer DG. MR imaging of myxopapillary ependymoma: findings and value to determine extent of tumor and its relation to intraspinal structures. *AJR Am J Roentgenol*. 1995;165:1263-7.
22. Brazier JE, Harper R, Jones NM, O'Cathain A, Thomas KJ, Usherwood T, Westlake L. Validating the SF-36 health survey questionnaire: new outcome measure for primary care. *BMJ* 1992;305:160-4.
23. Nurick S. The pathogenesis of the spinal cord disorder associated with cervical spondylosis. *Brain* 1972; 95:87-100.

Author Information

S. Peter Stawicki, M.D.

OPUS 12 Foundation

John J. Guarnaschelli, M.D.

Neurosurgical Group of Greater Louisville