

# Undiagnosed DiGeorge anomaly in a child with recurrent chest infections: An Autopsy Report With Brief Review Of Literature

Y Kumar, R Gupta, A Bhatia, N Kakkar, R Vasishta

## Citation

Y Kumar, R Gupta, A Bhatia, N Kakkar, R Vasishta. *Undiagnosed DiGeorge anomaly in a child with recurrent chest infections: An Autopsy Report With Brief Review Of Literature*. The Internet Journal of Pathology. 2007 Volume 7 Number 1.

## Abstract

We report a case of 3 year old female child who remained a diagnostic dilemma for the clinicians during her life. The cause of recurrent chest infections in this child could not be found ante mortem which ultimately led to delayed specific treatment and demise of the patient. Autopsy revealed classical features of DiGeorge anomaly in the form of rudimentary thymus, ventricular septal defect, bronchopneumonia and T cell deficiency. DiGeorge anomaly is a rare disorder but it should always be considered in a pediatric patient presenting with recurrent infections. This may help in early diagnosis and avoid fatal outcome of the disorder.

## INTRODUCTION

The child with recurrent chest infections presents the clinician with a difficult diagnostic challenge. Disorders presenting this way include cystic fibrosis, congenital abnormalities of the respiratory tract, bronchial asthma, bronchiectasis following acute pneumonia and sometimes inhalation of food or a foreign body. Rarely an immune defect may also be responsible for severe, recurrent respiratory infections unresponsive to conventional treatment. Immune defects are either primary (congenital) or secondary (acquired). Secondary causes are usually in the form of malignancy, immunosuppressive therapy, measles, malnutrition or HIV infection. Primary immunodeficiency may be due to defect of antibodies, T-lymphocytes, phagocytes or the complement system. <sup>1</sup> DiGeorge anomaly is the one with deficiency of T Cells. In this condition there is often a delay of years between the onset of symptoms and the diagnosis being made. The delay might increase the risk of irreversible lung damage occurring before appropriate treatment is given. <sup>2</sup> Besides common causes of immunodeficiency i.e., acquired immunodeficiency syndrome, X-linked agammaglobulinemia etc, a possibility of rare DiGeorge anomaly therefore should always be considered in a young child presenting with recurrent respiratory infections specially if accompanied with congenital heart disease and abnormal facies. Autopsy findings in DiGeorge anomaly are rarely described in the

literature. <sup>3</sup> Moreover aim of this report is to describe the approach to pathological diagnosis of a clinically unsuspected DiGeorge anomaly.

## CASE REPORT

A three year old female child born of full term vaginal delivery presented pediatric out patient department with fever, cough and rapid breathing since 1 week. She also had episodes of seizures and altered sensorium for three days. There was past history of recurrent chest infections since the age of two months which responded to medical treatment.

On examination the patient had abnormal facies in the form of microcephaly, low set ears and a flat nasal bridge. Cardiovascular examination revealed acyanotic heart disease with apex in the 5th intercostal space in left mid-clavicular line, pre-cordial bulge, epigastric pulsations and parasternal thrill. S1 was normal however S2 was loud with palpable P2, gallop rhythm and grade IV pansystolic murmur. Biochemical investigations were performed which revealed deranged calcium levels, the lowest value being 5.6 mg%. Due to difficulty to reach a definite diagnosis based on clinical and biochemical findings a chromosomal study was planned but before this the child succumbed to her illness. A complete autopsy including brain examination was performed after an informed consent from the parents.

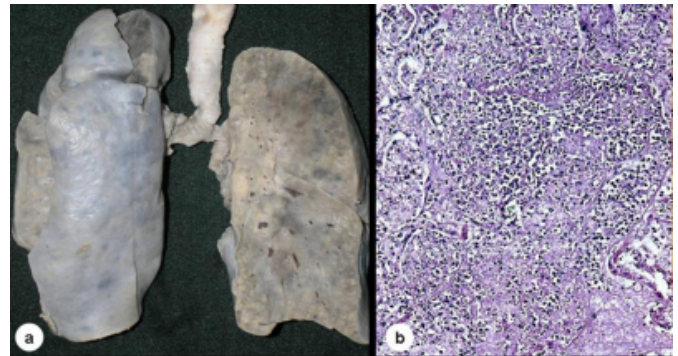
Autopsy Findings: All the visceral organs were studied. The

lungs weighed 215gms against the normal average weight of 120gms for the age. The pleural surface of both the lungs was discolored and cut surface showed areas of hemorrhage and consolidation. Multiple sections were studied which revealed confluent necrotizing bronchopneumonia (figure 1), hemorrhage, edema and grade I pulmonary artery hypertension. No fungal profiles were seen thereby excluding the possibility of any fungal infection. The heart weighed 64gms and on opening revealed right ventricular hypertrophy, the wall thickness being 9mm. The interventricular septum showed a large peri-membranous septal defect measuring 8 mm in diameter with sclerosed free edge (figure 2). The great vessels were normal. Liver and spleen showed foci of extra medullary haematopoiesis. Gastrointestinal tract also did not contain any focus of infection. The brain, grossly as well as microscopically did not show any lesions except for the terminal hypoxic changes. Both the kidneys were normal. All these findings could not reveal the cause of respiratory infection.

Thereafter efforts were made and all the organs were further reviewed. In view of clinical history, a rare cause “the DiGeorge anomaly” was considered and search was made to identify thymus and parathyroid glands. Grossly, no thymic or parathyroid tissue could be identified and thus most of the tissue anterior to the trachea and in the region of parathyroid glands was blocked and processed. Only a small microscopic focus of normal thymic tissue was discovered surrounded by connective tissue, nerves and tiny lymph nodes (figure 3). Parathyroid glands could not be seen even on microscopic examination. Immunodeficiency was confirmed when many of the lymph nodes sampled showed predominance of cortical lymphoid follicles with depleted paracortical (T-cell rich) areas (figure 4). Immunostains CD19 and CD3 (B and T-cell markers respectively), were performed which confirmed the same. Sections from gastrointestinal tract were re-examined and showed poorly developed lymphoid tissue. Spleen was also deficient in peri-arteriolar T cells. Both clinical and pathological findings were then correlated and a final autopsy diagnosis of DiGeorge anomaly was made.

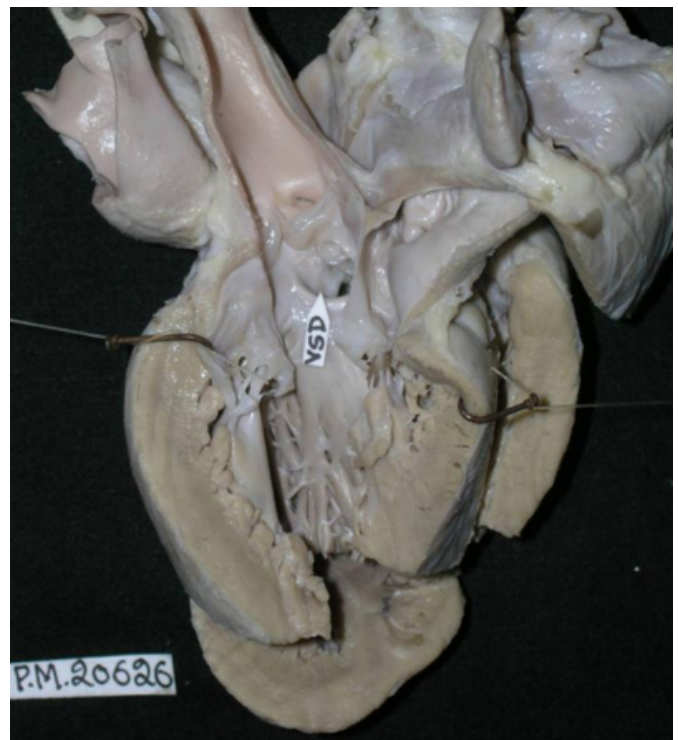
**Figure 1**

Figure 1: (a) Gross photograph of both the lungs shows discolored pleura and hemorrhagic consolidation (b) Microscopy of the lung revealing necrotizing bronchopneumonia with dense acute inflammatory infiltrate.



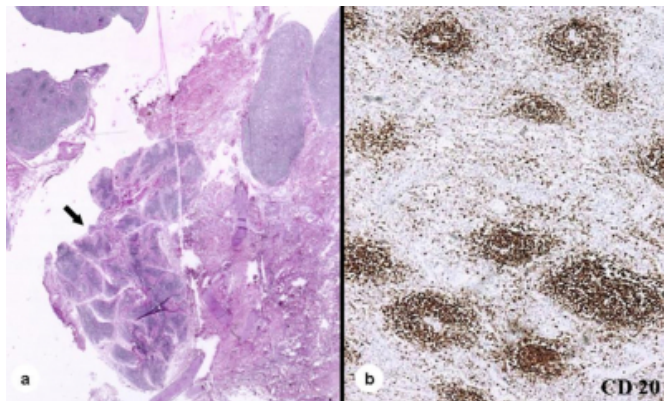
**Figure 2**

Figure 2: Left outflow tract of the heart with a large peri-membranous ventricular septal defect.



### Figure 3

Figure 3: (a) Rudimentary but morphologically normal thymus (arrow) embedded within the soft tissue of the neck along with small lymph nodes. (b) Photomicrograph from the section of a peritoneal lymph node showing CD20 positive prominent lymphoid follicles and paracortical T-cell depletion.



### DISCUSSION

DiGeorge anomaly, also called DiGeorge syndrome, congenital thymic hypoplasia or third and fourth pharyngeal pouch syndrome, is a rare congenital immune disorder, first reported by Angelo DiGeorge in 1965. <sup>4</sup> Since then near 200 cases have been documented in literature but still diagnosis is generally delayed because of its variable presentations. DiGeorge anomaly belongs to the group of disorders that share a chromosome deletion resulting in monosomy 22q11. These disorders include velo-cardio-facial syndrome (Shprintzen syndrome), thymic aplasia or hypoplasia, hypocalcaemia syndrome, conotruncal anomaly face syndrome and DiGeorge anomaly. The acronym CATCH 22 has been suggested for this group of anomalies since it describes the findings of cardiac anomalies, abnormal facies, thymic hypoplasia, cleft palate, and hypocalcemia on chromosome 22. The primary defect involves fourth branchial arch and derivatives of 3rd and 4th branchial pouches. It is postulated that either premature involution of thyroidea ima artery which is the principal source of supply for 3<sup>rd</sup> and 4<sup>th</sup> pharyngeal pouches or defective migration of the neural crest cells may be the critical event in the embryogenesis of these anomalies. <sup>3,4</sup>

Recurrent infections usually present in patients older than 3-6 months after defective immune development. Severity of these infections vary and depend on the degree of thymic deficiency which may be minimal with spontaneous acquisition of normal T cell function to so severe that B cell deficiency is also present. <sup>5</sup> The histology of thymus is

essentially normal but it is hypoplastic (at least 5% reduction in its normal weight). <sup>6</sup> Cardiac defects are seen in 49-90% of patients and may be in the form of right aortic arch, interrupted aortic arch, tetralogy of Fallot, aberrant subclavian artery, right infundibular stenosis and ventricular septal defect. Renal abnormalities associated with DiGeorge anomaly include absent, dysplastic or multicystic kidneys, obstructive anomalies, vesico-ureteric reflux and nephrocalcinosis. <sup>7</sup>

No racial, ethnic or sex predisposition has been identified. Age of presentation depends largely on the severity and nature of the defect, thus those with more serious cardiac defects observed in classic DiGeorge anomaly are diagnosed in the neonatal period. The other frequently noted problems are low calcium levels due to abnormality of the parathyroid glands, cleft palate, short stature, learning difficulties, and characteristic facial appearance with unusually small head, small mouth and prominent nose. <sup>8</sup> The immune system is affected in demonstrably 80% of the patients making them prone to multiple infections.

Associations described with DiGeorge anomaly are diabetes in the mother and fetal alcohol syndrome (a pattern of birth defects, and learning and behavioral problems affecting individuals with history of alcohol consumption in mother during pregnancy). <sup>9</sup>

Antenatal diagnosis of DiGeorge anomaly is usually made by ultrasound examination around the eighteenth week of pregnancy or fluorescence in situ hybridization performed on cell samples obtained by amniocentesis as early as the fourteenth week of pregnancy. It confirms about 95% of cases of DiGeorge anomaly. Postnatal diagnosis is sometimes suggested by the child's facial features at birth and can be confirmed by blood tests for calcium, phosphorus and parathyroid hormone levels, by the sheep cell test for immune function and by detection of associated cardiovascular abnormality. Specific treatment depends on the symptoms and the system involved. Prognosis of these patients is variable and ultimately depends upon the severity of the heart defects, partial presence of the thymus gland and degree of T cell failure.

In our case a final diagnosis of DiGeorge anomaly could be made only after postmortem examination after an extensive search to find the cause for recurrent respiratory infections. Though the child had classical features of DiGeorge anomaly both clinically and histopathologically, life of the

patient could not be saved due to failure of its early detection. Therefore it may be useful if both pathologists and clinicians keep this entity in mind whenever they deal with a pediatric patient presenting with recurrent infections and cardiac abnormality specially if associated with abnormal facies.

## **CORRESPONDENCE TO**

Yashwant Kumar The Pines, Near Ashiana Regency, Chhota Shimla, Shimla (HP) India – 171002 E-mail:

yashwantk74@yahoo.com Phone: 91+9996006515 Fax:

0091-172-2744401

## **References**

1. Couriel J. Assessment of the child with recurrent chest infections. *BM Bull* 2002; 61:115-132.
2. Haeney M. The detection and management of primary immunodeficiency. In: David TJ. (ed) *Recent Advances in*

*Paediatrics*, vol 9. Edinburgh: Churchill Livingstone, 1990; 21-40.

3. Sane SY: DiGeorge syndrome with multiple infections (an autopsy report). *J Postgrad Med* 1989; 35 (2): 114-5

4. Hong, R.: Immunity allergy and related diseases. In, "Nelson Textbook of Pediatrics. Editors: Nelson, Vaughan, McKay and Behrman". W. B. Saunders Co. Philadelphia, pp. 594.

5. Haynes, R. Jr.: DiGeorge or the III and IV pharyngeal pouch syndrome. "Perspectives in Pediatric Pathology". Vol. II Editors: Rosenberg and Bolande. Year Book Med. Pub. 1975, pp. 173.

6. Thymic hypoplasia. In "Pediatric pathology". Vol. II Editor: J. Thomas Stocker. 2nd edition. pp 117-1120.

7. Ryan AK, Goodship JA, Wilson DI. Spectrum of clinical features associated with interstitial chromosome 22q11 deletions: a European collaborative study. *J med Genet* 1997; 34:798-804

8. Richard Hong: The DiGeorge Anomaly. Clinical reviews in allergy and Immunology. 2001; Vol.20 (1): pp. 43-60.

9. Ammann AJ, Wara DW, Cowan MJ. The DiGeorge syndrome and the fetal alcohol syndrome. *Am J Dis Child* 1982 Oct; 136(10): 906-8.

**Author Information**

**Yashwant Kumar, MD, DNB**

Senior Resident, Department of Histopathology, Postgraduate Institute of Medical Education and Research

**Ruchi Gupta, MD**

Senior Resident, Department of Histopathology, Postgraduate Institute of Medical Education and Research

**Alka Bhatia, MD**

Senior Resident, Department of Histopathology, Postgraduate Institute of Medical Education and Research

**Nandita Kakkar, MD**

Associate professor, Department of Histopathology, Postgraduate Institute of Medical Education and Research

**R.K. Vasishta, MD, FRC Pathol**

Professor, Department of Histopathology, Postgraduate Institute of Medical Education and Research