

Fallopian tube flaps (FTFs) for repairing high vesico-vaginal fistulas (VVF) – a new surgical technique

R Singh, S Dalal, S Nanda, P Dahiya

Citation

R Singh, S Dalal, S Nanda, P Dahiya. *Fallopian tube flaps (FTFs) for repairing high vesico-vaginal fistulas (VVF) – a new surgical technique*. The Internet Journal of Gynecology and Obstetrics. 2008 Volume 11 Number 1.

Abstract

Present technique was carried out to evaluate the role of fallopian tube flaps (FTFs) in prevention of re-fistulizations following repairs of high vesico-vaginal fistulas (VVF). Between June and August 2007, three patients presented with high VVF following life saving sub-total hysterectomy for ruptured uterus due to prolonged obstructed labour of more than 24 hours resulting in stillbirth. A combined transabdominal-transvesical approach (Swift-Joly technique) was used for defining, dissection and closure of VVF. The fallopian tube of either side was mobilized on its vascular pedicle (ovarian vessels), and split opened up in whole of its length at its anti-mesenteric boarder (fallopian tube flap). The fallopian tube flap was brought down and interposed between the bladder and the vagina and was sutured all round the closed vaginal vault. All the three patients had smooth post-operative outcome. At 3 months of follow-up, each patient could hold 200 cc of urine without having incontinence, discomfort, urgency or increased frequency.

INTRODUCTION

Simple closures of VVF are prone to recurrences. Different flaps have been used for re-enforcement of the closed VVF to prevent their re-fistulizations.^{1,2,3,4}

PATIENTS AND TECHNIQUE

CASE NO. 1

A 35 year old female, presented with 3 months history of continuous dribbling of urine per-vaginum that she noticed in the immediate post-operative period following sub-total hysterectomy for still birth in a ruptured uterus due to prolonged obstructed labour of more than 24 hours. Her hematological, bio-chemical and radiological investigations were normal. Cystoscopic examination revealed a 2 cm vesico-vaginal fistula (VVF) located in the trigonal area within the safe zone, i.e., her both the ureteric openings were placed more than 1 cm away from the fistulous margins.

CASE NO. 2

A 30 year old female presented with 4 months history of urinary incontinence following sub-total hysterectomy for the same reasons as mentioned above. She had 1.5 cm VVF located in the trigonal area in risky zone, i.e., her left ureteric opening was placed within 1 cm of the left margin of the fistula and required re-implantation of left ureter.

CASE NO. 3

A 40 year old female, presented with 1 year history of continuous leakage of urine per-vaginum that she experienced in the immediate post-operative period following sub- total hysterectomy for similar reasons. Cystoscopic examination demonstrated a 3 cm VVF located in trigonal area within the risky zone, i.e., her both ureteric openings were abutting the left and right margins of the fistula and required bilateral ureteric re-implantation.

TECHNIQUE

All the three VVF were defined, dissected and closed using a combined transabdominal- transvesical approach (Swift Joly technique).⁵ The cervical stumps were removed and the bladder and the vagina were closed at right angle to each other (bladder vertically and vaginal vault transversally) in two layers (inner continuous and outer interrupted) using 2 0 vicryl on round body needle. The right fallopian tube was held with a pair of Bab-cock forceps near its fimbrial and medial ligated end. The serosal covering of its mesentery was incised keeping 1 cm fringe of the serosa on both sides of the fallopian tube. The tube was mobilized till its vascular pedicle (Fig.1) and was split open at its anti-mesenteric border in its whole length from fimbrial end to the blind medial ligated end (fallopian tube flap). Its mucosal lining was excised after infiltration with 1:200,000 adrenaline

solution in the sub-mucosa. The flap measured approximately 5-7 cm in length and 3-5 cm in width. The fallopian tube flap was brought down and its front margin was sutured with the anterior wall of the vagina, approximately 1 cm away from the suture line of the vaginal vault, taking partial thickness suture bites of continuous 2-0 vicryl on round-body needle (Fig.2). In all three patients following tubes were used, a) intra-abdominal pelvic drain (24 F), b) infant feeding tubes for cannulation of transplanted ureters (8 F), c) suprapubic cystostomy tube (28 F), and d) Foley's catheter (18 F) for following purposes: (a) to prevent pelvic collection and haematoma, (b) for renal decompression, (c) to provide an alternate route for free drainage of urine in case the Foley's catheter is blocked, and (d) to ascertain continuous bladder decompression, and all these tubings were removed on 5th, 10th, 15th, and 20th post-operative day, respectively.

The associated pelvic displacement of the ovary was tagged with silk sutures and recorded for its future identification/localization.

OBSERVATIONS

Fallopian tube was easy in harvesting; had adequate length and breadth; could be brought down to be kept in the region of the fistula without any tension on its vascular pedicle; had good vascularity; provided all round mechanical and biological re-enforcement to the closed vaginal vault; and functioned as an effective interposition flap by way of its position sandwiched between the widely separated and independently right angle closed bladder and the vagina.

RESULTS

All the patients had uneventful post-operative recovery. At 3 months of follow-up, each one could hold 200 cc of urine without any discomfort or urgency. None had increased frequency or incontinence.

Figure 1

Figure 1: Line diagram showing post subtotal hysterectomy VVF and fallopian tube mobilized on vascular pedicle (fallopian tube flap).

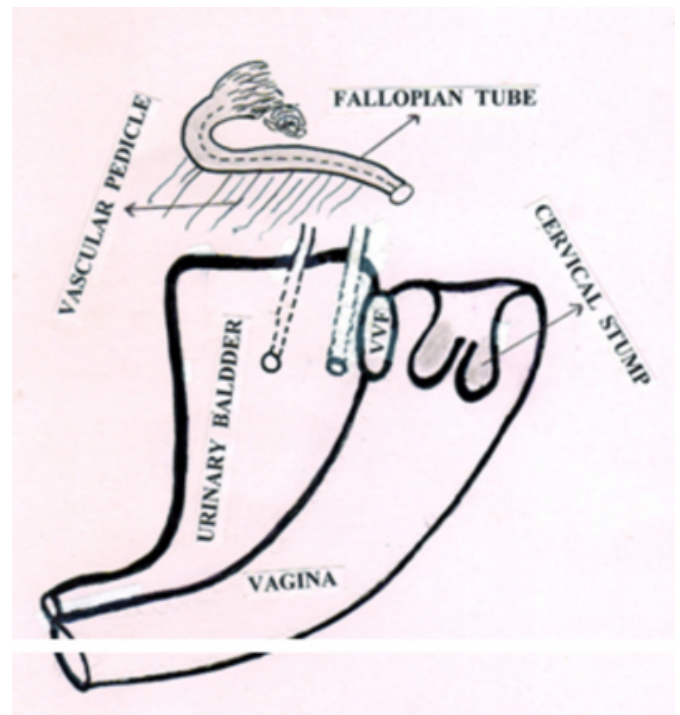
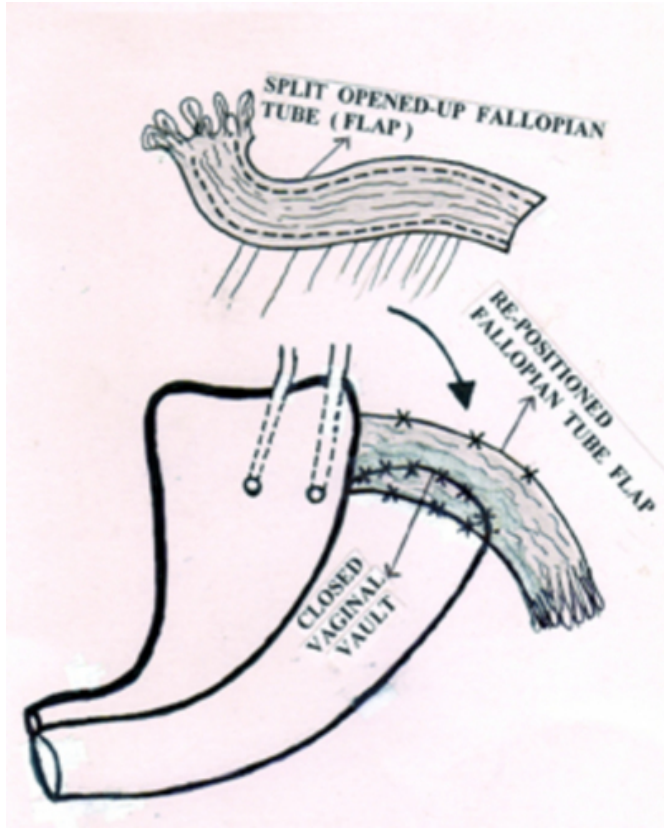


Figure 2

Figure 2: Split opened up fallopian tube, fallopian tube flap repositioned to cover the closed vaginal vault.



DISCUSSION

Surgical repair of VVF had been a great challenge for the operating surgeon. Various flaps like omental flap, rectus abdominis muscle flap, sartorius muscle flap, adductor magnus muscle flap, gracilis muscle flap, have been used for reinforcement of the closed VVFs to prevent refistulisations.^{1,2,3,4,5} Unlike other re-enforcement flaps, the harvesting of fallopian tube flap was simple, quick, reliable and produced negligible blood loss, and was directly sutured

1 cm away on either sides of the suture line of the closed vaginal vault. The fallopian tube flap is highly vascular and pedicled, and could be mobilized and brought down to be interposed between the suture lines of the closed bladder and the vaginal vault to provide them a wide and tension free all round mechanical and biological barrier against re-fistulizations.

CONCLUSION

The technique is simple, quick and reliable, and produced neither blood loss nor any internal or external disfigurements. It makes healthy use of vestigial fallopian tubes by providing a mechanical and biological barrier between the suture lines of the right angled closed bladder and vagina, thus successfully preventing re-fistulizations.

CORRESPONDENCE TO

Dr. Satish Dalal 9J/54, Medical Campus, PGIMS,
Rohtak-124001 (Haryana) INDIA Tel. No.
+91-1262-213459, Mobile : 09315326802 E-mail :
drsatishtdalal@rediffmail.com

References

1. Fitzpatrick C, Elkins TE. Plastic surgical techniques in the repair of vesicovaginal fistulas: a review. *Int Urogynecol J* 1993; 4: 287-95
2. Thompson JD. Vesicovaginal and urethrovaginal fistulas. In: Rock AJ, Thompson JD, eds. *Te Linde's Operative Gynecology*. Philadelphia: Lippincott-Raven Publishers. 1997; 1175-205.
3. Singh RB, Pavithran NM, Nanda S. Plastic reconstruction of a mega vesicovaginal fistula using broad ligament flaps – a new technique. *Int Urogynecol J* 2003; 14: 62-63.
4. Singh RB, Pavithran NM, Khatri HL, Nanda S. Technical aspects in the management of complex vesicovaginal fistulae. *Tropical Doctor* 2005; 35: 40-41.
5. Hudson CN, Setchell ME. Genital fistula. In: Hudson CN, Setchell ME, eds. *Shaw's Textbook of Operative Gynaecology*. 6th Ed. New Delhi: Elsevier. A division of Reed Elsevier India Private Limited. 2006; 237 69

Author Information

R.B. Singh, MS, MCh.

Professor, Department of Plastic Surgery and Hypospadias & VVFs Clinic, Pt. B.D. Sharma Postgraduate Institute of Medical Sciences (PGIMS)

S. Dalal, MS

Assistant Professor, Department of General Surgery, Pt. B.D. Sharma Postgraduate Institute of Medical Sciences (PGIMS)

S. Nanda, MD

Professor, Department of and Gynecology, Pt. B.D. Sharma Postgraduate Institute of Medical Sciences (PGIMS)

P. Dahiya, MD

Professor, Department of and Gynecology, Pt. B.D. Sharma Postgraduate Institute of Medical Sciences (PGIMS)