

Lunate and Perilunate Dislocations: Our Experience

J Ogunlusi, S St. Rose, T Davids

Citation

J Ogunlusi, S St. Rose, T Davids. *Lunate and Perilunate Dislocations: Our Experience*. The Internet Journal of Orthopedic Surgery. 2007 Volume 8 Number 1.

Abstract

Purpose: Lunate and perilunate dislocations are uncommon dislocations and diagnosis could be delayed or missed resulting to chronic disability. This study is to document the pattern in our institution.

Methods: This was a ten month prospective study, eight patients were studied and information on biodata, mechanism of injury, X-ray findings, duration between injury treatment, treatment and associated injuries were obtained. Four patients with lunate dislocation had open reduction which was through the anterior approach with simultaneous carpal tunnel release. The anterior carpal ligaments sutured were repaired. A below elbow plaster cast was applied with the wrist in about 20 degree of flexion for four weeks. Reduction was by manipulation in three patients with perilunate dislocation. The seven patients treated had physiotherapy for 9-14 weeks except for one that presented 6 weeks after injury. One patient with lunate dislocation left our care when offered open reduction; he presented two weeks after injury.

Results: The patients were aged between 26-62 years. The mean \pm SD age was 39.50 \pm 10.95 years. The ratio of Right: Left wrist was 1.7:1. Mechanism of injury was due to high energy traumas from Motor vehicular accident 4/8, fall from height 3/8 and heavy object falling on the wrist.

Conclusions: It was noted that lunate and prelunate dislocations were seen mostly in young males and early manipulation or open reduction and subsequent immobilization in plaster of Paris with the wrist in about 20 degree flexion position for four weeks give good functional outcome in these dislocations. Thus prompt diagnosis of these dislocations should be made and appropriate treatment instituted.

INTRODUCTION

Hand injuries are devastating injuries. This is not only because of the loss of one's ability to perform everyday personal functions but also because of the inability to perform occupational skills that directly affects self-worth and livelihood. Lunate and perilunate dislocations are not very common¹. The injury may be subtle clinically and radiologically and the diagnosis is frequently delayed¹. The diagnosis could also be missed out rightly. Emergency medicine practitioners need to be vigilant for both lunate and perilunate dislocations because when left unrecognized and untreated, these injuries lead to a high incidence of long-term functional disability and chronic pain². Missed diagnosis has been reported to be up to 25% in a multicenter study by Herzberg et.al³. Unreduced lunate, perilunate, and transscaphoid perilunate dislocations present a difficult and challenging surgical problem⁴. The management of carpal dislocation after a late diagnosis is difficult. When left

unrecognized and untreated, these injuries lead to a high incidence of long-term functional disability and chronic pain^{2,5}. Thus high index of suspicion is important to make the right diagnosis and institute prompt management. This pathology is made worse by swelling and pain. The adoptions of metacarpophalangeal (MCP) joint in extension, interphalangeal joint in flexion and the collateral ligaments contracture leads to finger stiffness.

METHOD

This is a prospective study of eight patients with lunate and perilunate dislocations seen within ten months in our hospital. Information on age, sex, mechanism of injury, X-ray findings, treatment offered, the duration between injury and treatment and associated injuries. Patients were treated by either manipulation under anesthesia or open reduction. Four patients with lunate dislocation had open reduction and this was basically through the anterior approach with

simultaneous carpal tunnel release. The anterior carpal ligaments sutured with chromic catgut. A below elbow strong back slab plaster cast was applied with the wrist in about 20 degree of flexion for four weeks. Three patients perilunate dislocation had reduction by manipulation. All the seven patients treated had physiotherapy steadfastly for 9-14 weeks except for the patient that presented 6 weeks after initial injury. She defaulted from the physiotherapy unit and the out patient clinic because she felt that the nerve injury and the wrist stiffness are not recovering fast enough. One patient with lunate dislocation absconded when offered open reduction when he presented two weeks after injury. The other seven patients were followed up for 8 months.

RESULT

Eight patients were studied and all were males except one. The patients were aged between 26 and 46 years except one that was 62 years. The mean SD age was 39.50 10.95 years. The ratio of Right: Left wrist was 1.7:1. All the patients had dominant right hand.

Mechanism of injury was due to high energy traumas from Motor vehicular accident 4/8, fall from height 3/8 and heavy object falling on the wrist. The information on boidata, X-ray findings, associated injuries, treatments and the outcome is tabulated below in Tables 1 and Table 11.

Figure 1

Table 1: Lunate Dislocations

Case no.	Age(years)/ Sex/Side	Mechanism of injury	Clinical features	Radiological findings	Injury to treatment duration	Treatment	Associated injury	Functional Outcome
1	34/F/R	Motor vehicular accident	Pain, volar fullness, numbness 3 medial fingers	Lunate dislocation	6 weeks	Open reduction and physiotherapy	Nil	Poor
2	46/M/R	Fall from height landed on outstretched hand	Painful volar fullness deformity	Lunate and elbow dislocations	2 weeks	MUA failed at 2 weeks, open reduction and physiotherapy	Posterior elbow dislocation	Good
3	40/M/R	Fall on outstretched hand	Painful volar fullness	Lunate dislocation	2 weeks	Planned for surgery but absconded	Nil	Discontinued treatment with us
4	62/M/R	Hit by a car off his motorcycle	Open wrist injury	Lunate, Triquetrum and Hamate dislocations, Bennett fracture 1 st metacarpal	30 minutes	ORIF with K-wires and Physiotherapy	Multiple carpal bone dislocations and Bennett fracture	Fair
5	31/M/L	Motor vehicular accident	volar fullness, and deformed	lunate dislocation	10 days	MUA failed, open reduction and physiotherapy	Nil	Good

Figure 2

Table 2: Perilunate Dislocations

Case no.	Age(years)/ Sex/Side	Mechanism of injury	Clinical Features	Radiological findings	Injury to treatment duration	Treatment	Associated injury	Functional Outcome
1	31/M/L	Heavy box of glass fell on his wrist	wrist deformity and dorsal fullness	Perilunate dislocation	45 minutes	MUA, plaster cast, and physiotherapy	Nil	Very Good
2	40/M/R	Fell from 15feet on the dorsum of the wrist	Painful, swollen and deformed wrist	Perilunate dislocation	30 minutes	MUA, plaster cast, and physiotherapy	Nil	Very Good
3	37/M/L	Motor vehicular accident	Swollen and deformed wrist	perilunate dislocation	6 days	MUA, plaster cast, and physiotherapy	R femoral shaft fracture	Good

NB: M-Male, F-Female, R-Right, L-Left and MUA-Manipulation under anaesthesia

Figures below 1, 2 and 3 show the X-rays of one of the patients with lunate dislocation at presentation, post open reduction and immobilization and at four months post injury respectively.

Figure 3

Figure 1: Lunate dislocation at presentation

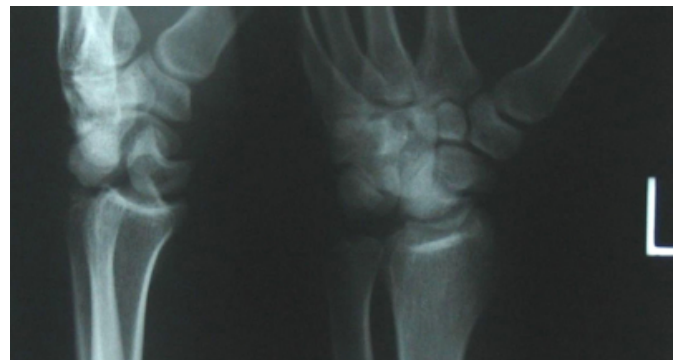


Figure 4

Figure 2: X-ray for post open reduction and immobilization

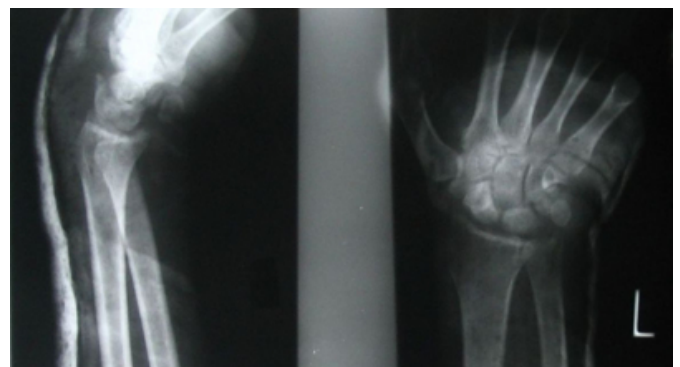
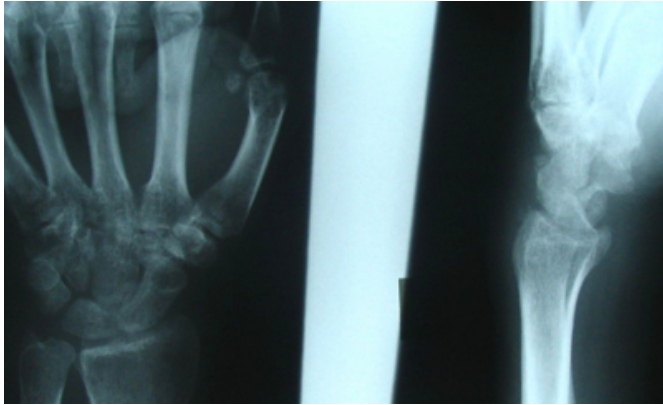


Figure 5

Figure 3: X-ray at 4 months post injury



DISCUSSION

Eight patients with lunate, perilunate dislocation or combination of the two presented within ten months at our hospital. The number of patients seen may seem small but the injuries are quite significant to the individuals involved especially when it affects their livelihood because of inability to use the hands.

Some important observations were noted. All the patients were right handed with all having right hand injury except one and with mean SD age of 39.50 10.95 years, these would have lead to significant lost of productivity in these productive age group. Seven of the patients were males, showing that males are predominantly injured just like many other traumas. High energy injuries were responsible for the injuries, it is thus important to critically evaluate X-rays of patents that sustained high energy injuries to the wrist and hand in order not to miss the diagnosis.

One of the patients had bipolar dislocation of the forearm similar to the one reported by Masmejean et al ⁶. It is important to examine the wrist and elbow of patients who fell from height in order not to miss the carpal and elbow injuries that would have occurred simultaneously.

Early and prompt diagnosis of the injury by the medical health provider especially those working in the emergency department will make the management and outcome favourable. Painful volar fullness was a common feature of the patients with lunate dislocation. The median nerve is quite vulnerable to injury by the dislocated lunate and when the diagnosis is missed the normal function of the hand is lost because of the dislocation and the associated nerve injury. One of our patients had median nerve compression for 6 weeks undetected. It has been reported that pain as well as sensory and motor dysfunction in the distribution on the

median nerve is associated with chronic anterior dislocation of the lunate⁷. It is thus important to examine the neurological status of the hand where there are hand injuries especially where there is evidence of volar fullness.

We noticed that reduction by manipulation under anesthesia is easy and give good result when the patient present early especially within hours of injury but there is failure of manipulation after on week of injury. It was also noted that the manipulation under anesthesia was more successful in patients with perilunate dislocation, this might be due to early presentation in these patients and the fact that the whole of the wrist and hand bones are dislocated as entity in perilunate compare with the lunate where only the lunate bone is dislocated. Manipulation under anesthesia is not likely to be successful when there are multiple carpal bone injuries like one of our patients, thus open reduction and internal fixation will be more rewarding in this type of patients.

The open reduction was by anterior approach and the anterior carpal ligaments sutured with chromic catgut. Strong back slab POP was applied for four weeks in 20 degree flexion to allow adequate time for the anterior carpal ligaments to heal well. Some authors have shown that a combined dorsal and volar approach with an intraosseous wiring technique can restore effectively normal intercarpal relationships, providing acceptable pain relief, functional motion, and grip strength. ^{8, 9} Open reduction, arthroscopic, and fluoroscopically aided percutaneous techniques can be used to successfully treat carpal dislocations.¹ Treatment of chronic dislocations could be difficult, unrewarding and might involve radical procedures like proximal row carpectomy, lunate excision, total wrist arthrodesis and wrist arthroplasty ^{10,11}.

It was noted that early manipulation or open reduction and subsequent immobilization with strong back slab plaster of Paris with the wrist in about 20 degree flexion position for four weeks give good functional outcome in five of our patients.

Even though the number of patients seen are few we recommend the perilunate dislocation should be reduced by manipulation. We are also recommending that patients with wrist and hand injuries should be examined clinically, assessed radiologically and institute prompt and appropriate treatment. This will lead to avoidance of the chronic disability and the radical corrective surgery that may not be very rewarding.

CORRESPONDENCE TO

Johnson Dare Ogunlusi Consultant Accident and Emergency
/ Orthopaedic Surgeon & Traumatologist, Victoria Hospital,
Castries. St Lucia. West Indies. E mail:
gbemidare@yahoo.com

References

1. Weil WM, Slade JF 3rd, Trumble TE. Open and arthroscopic treatment of perilunate injuries. *Clin Orthop Relat Res.* 2006;445:120-32.
2. Perron AD, Brady WJ, Keats TE, Hersh RE. Orthopedic pitfalls in the ED: lunate and perilunate injuries. *Am J Emerg Med.* 2001;19(2):157-62.
3. Herzberg G, Comtet JJ, Linscheid RL, Amadio PC, Cooney WP, Stalder J. Perilunate dislocations and fracture-dislocations: a multicenter study. *J Hand Surg [Am].* 1993;18(5):768-79.
4. Howard FM, Dell PC. The unreduced carpal dislocation. A method of treatment. *Clin Orthop Relat Res.* 1986;(202):112-6.
5. Vegter J. Late reduction of the dislocated lunate. A method using distraction by an external fixator. *J Bone Joint Surg Br.* 1987;69(5):734-6
6. Masmejean E, Cognet JM. Bipolar dislocation of the forearm: elbow and perilunate dislocation. *Rev Chir Orthop Reparatrice Appar Mot.* 2001 Sep;87(5):499-502.
7. Chen WS. Median- nerve neuropathy associated with chronic anterior dislocation of lunate. *J Bone Joint Surg Am.* 1995;77(12):1853-7
8. Trumble T, Verheyden J. Treatment of isolated perilunate and lunate dislocations with combined dorsal and volar approach and intraosseous cerclage wire. *J Hand Surg [Am].* 2004 ;29(3):412-7.
9. Melone CP Jr, Murphy MS, Raskin KB. Perilunate injuries. Repair by dual dorsal and volar approaches. *Hand Clin.* 2000;16(3):439-48.
10. Diao E, Andrews A, Beall M. Proximal row carpectomy. *Hand Clin.* 2005 ;21(4):553-9
11. Inoue G, Shionoya K. Late treatment of unreduced perilunate dislocations. *J Hand Surg [Br].* 1999;24(2):221-5

Author Information

Johnson D. Ogunlusi, FMCS (Ortho)

Consultant Accident and Emergency / Orthopaedic Surgeon & Traumatologist, Victoria Hospital

St George B.R. St. Rose, FRCS (Edin)

Consultant Orthopaedic Surgeon, Victoria Hospital

Tamunotoyen Davids

House Officer, Victoria Hospital