

Life-Threatening Lower Gastrointestinal Haemorrhage From An Aneurysm Of The Right Hepatic Artery: A Rare Case Presentation Due To Delayed Rupture

R Mohil, N Narayan, A Narayan, Z Kerketta, S Jain, D Bhatnagar

Citation

R Mohil, N Narayan, A Narayan, Z Kerketta, S Jain, D Bhatnagar. *Life-Threatening Lower Gastrointestinal Haemorrhage From An Aneurysm Of The Right Hepatic Artery: A Rare Case Presentation Due To Delayed Rupture*. The Internet Journal of Surgery. 2009 Volume 24 Number 1.

Abstract

Post-traumatic hepatic artery aneurysm (HAA) leading to massive lower gastrointestinal bleeding is rare. It should be suspected whenever there is hepatic injury with an infected collection leading to delayed upper or lower gastrointestinal bleeding. We report a case of a 35-year-old male who presented in emergency with pain in the right upper abdomen, fever, persistent cough, weight loss and fecal discharge mixed with blood from an abdominal wound. Four months earlier, the patient had undergone multiple laparotomies with perihepatic packing for blunt abdominal trauma with liver laceration. Twelve days after admission, he developed lower GI bleeding, CT angiography for which revealed HAA in a branch of the right hepatic artery with pooling of contrast into colon. On the day prior to therapeutic embolisation, the patient developed massive lower GI bleeding which did not respond to resuscitation. Emergency exploration with evacuation of a right sub-diaphragmatic collection, ligation of the bleeding aneurysmal vessel, repair of colonic fistula and end ileostomy were done. The patient recovered uneventfully with repeat postoperative CT at four weeks being normal. The case illustrates the rare occurrence of delayed lower GI bleeding due to rupture of HAA into colon after liver trauma. Different modalities such as embolisation and use of stent give promising results, ligation of aneurysm and repair of communication can also be done.

BACKGROUND

Visceral aneurysms are rare (0.2%), but 50% of these are hepatic artery aneurysms with an equal percentage of them being pseudoaneurysms. These are being diagnosed with greater frequency nowadays due to increase use of CT-scan after blunt abdominal trauma. These aneurysms can remain asymptomatic or lead to a sudden hemorrhage into the biliary tract, peritoneal cavity or portal vein due to degeneration and weakness of the hepatic arterial wall, secondary to a trauma (accidental or iatrogenic) or an inflammation of the biliary tract.[1, 2, 3]

We report an unusual case of aneurysm of the right hepatic artery branch, which developed following trauma to the liver with an infected collection in the area. This resulted in catastrophic lower gastrointestinal bleeding due to erosion into colon requiring urgent laparotomy.

CASE PRESENTATION

A 35-year-old male presented in the emergency department with pain in his right upper abdomen, fever, cough with

haemoptysis, weight loss and fecal discharge mixed with blood from the right lower abdomen. From the available records and history, the patient had undergone multiple exploratory laparotomies outside this hospital for blunt abdominal trauma four months back. On initial exploration, a liver laceration with small bowel injury was noted for which peri-hepatic packing along with repair of gut injury was done. The packing was removed after 48 hours but due to persistent bleeding a re-packing was required. Following the last surgery, the patient developed fecal discharge mixed with occasional blood from the drain site in the right lower abdomen for which he was referred to this hospital for further management. On presentation there was a controlled fecal fistula in the right iliac fossa with a healed lower midline laparotomy wound. Investigations revealed low haemoglobin (7g%), with the rest of the blood investigations being normal. Abdominal ultrasound showed a large loculated right sub-diaphragmatic collection measuring 11x12x9cm (678 cc) with moderate splenomegaly. Contrast-enhanced CT with CT angiography of the abdomen done outside showed an air-fluid level in the right sub-

Life-Threatening Lower Gastrointestinal Haemorrhage From An Aneurysm Of The Right Hepatic Artery: A Rare Case Presentation Due To Delayed Rupture

diaphragmatic area compressing the superior surface of the liver, a 4cm laceration in segment VIII, a hetero-echoic lesion in segment V and right pleural effusion, the rest of the organs being normal. CT angiography done simultaneously showed slight pooling of contrast with no other gross abnormality. [Figures 1 and 2]

Figure 1

Figure 1: Abdominal CECT done outside showing an air-fluid level and compressed superior surface of liver.

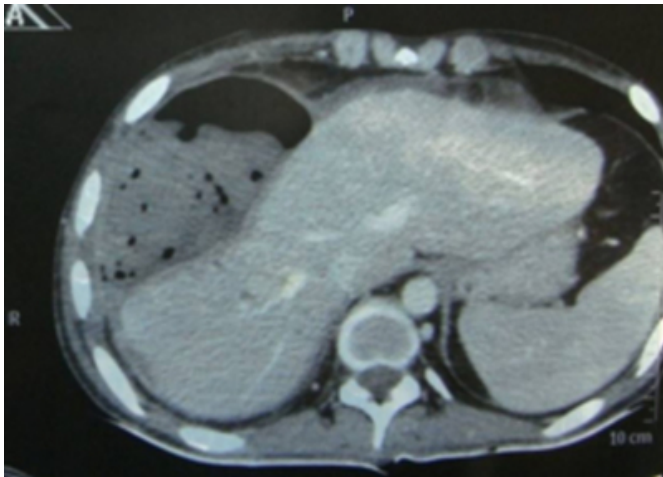
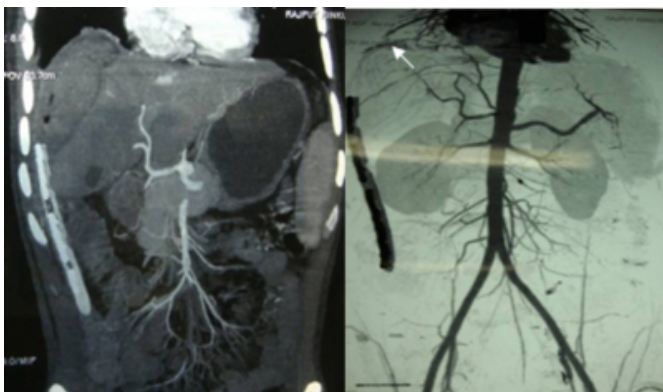


Figure 2

Figure 2: Initial CT angiography (before admission) shows grossly normal vessels with pooling of contrast (white arrow) in relation to the sub-diaphragmatic area.



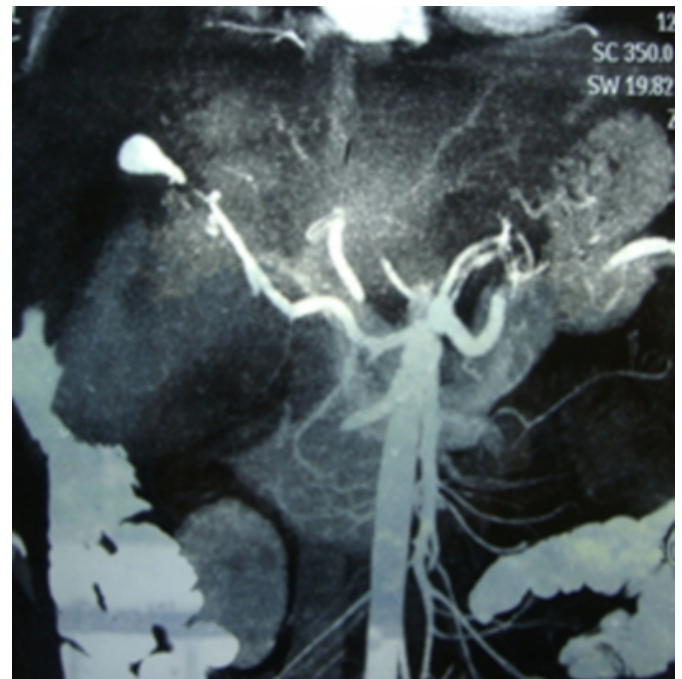The chest x-ray also revealed right basal effusion with suspicious Koch's lesion on the right side, sputum exam for which showed no AFB. The above imaging findings and history were suspicious of a retained sponge.

On 12th day of admission, the patient suddenly developed shock with melena and was immediately resuscitated with intravenous fluids, blood transfusions and other appropriate methods. A naso-gastric tube placed in the stomach to rule

out upper GI bleeding showed clear aspirate. Bleeding stopped on conservative treatment and the patient stabilised by 24 hours. Urgent CT angiography showed an aneurysmal dilatation in one of the branches of the right hepatic artery bordering the collection with free flow of contrast into colon – possibly due to a fistulous communication.

Figure 3

Figure 3: Repeat CT angiography (after admission) shows the aneurysm in a branch of the right hepatic artery (white arrow) with leakage of contrast into the colon (red arrow).

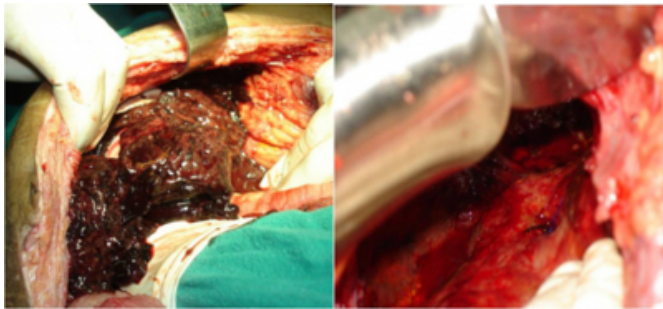


The patient was evaluated by an interventional radiologist for therapeutic embolisation of the aneurysm. On the day prior to embolisation the patient again developed massive lower GI bleeding with shock and passage of >1.5-2 L of fresh blood mixed with clots per rectum. As the shock was not responding to intravenous fluids and other resuscitative measures, the patient was taken up for emergency laparotomy.

On exploration there was a large collection of old clots mixed with fresh clots in the right sub-diaphragmatic space with an active bleeder from the upper surface of the liver. The bleeding aneurysmal vessel was under-run, following which haemostasis was achieved.

Figure 4

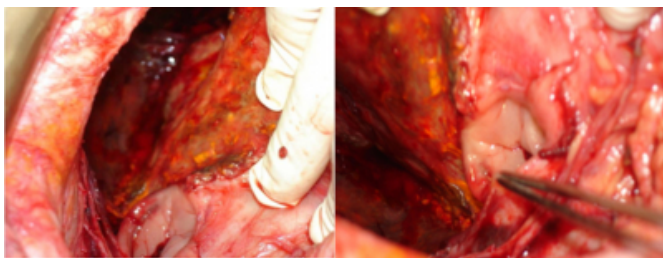
Figure 4: Operative photographs showing (a) the sub-diaphragmatic collection (b) suture ligation of the bleeding vessel



After complete evacuation, the hematoma was found to be communicating with the hepatic flexure.

Figure 5

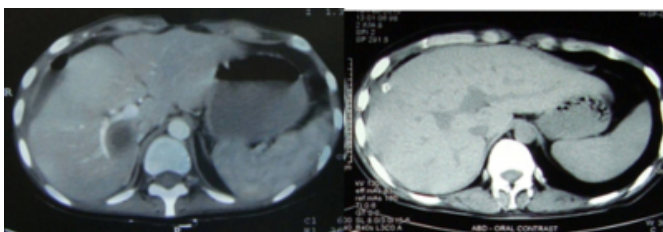
Figure 5: Colonic rent with cleared cavity and adequate haemostasis.



No foreign body or other solid organ injury was noted. The colonic rent was repaired with diverting end ileostomy. The patient was stable post-operatively and discharged 2 weeks after surgery. Repeat CT scan at 4 weeks and 7 months revealed a mild collection in the area with no aneurysmal vessel or leakage of contrast.

Figure 6

Figure 6: Postoperative CT scan showing minimal collection.



Subsequent ileostomy closure was done and the patient recovered completely.

DISCUSSION

Hepatic artery aneurysms (HAA) represent approximately

20% of all visceral aneurysms with true and pseudo-aneurysms occurring with equal frequency. [2] Eighty percent of HAAs are extrahepatic and 20% are intrahepatic. Sixty three percent of HAAs involve the common hepatic artery, 28% involve the right hepatic artery, 5% involve the left hepatic artery, and 4% both the left and right hepatic arteries. [1-4]

True aneurysms are segmental or diffuse dilations of the wall of an artery, while pseudoaneurysms are dilations of an artery that do not involve all layers of the wall. [5] True aneurysms occur 4 times more frequently in the extrahepatic arteries, usually involve the common hepatic artery, and are associated mainly with arteriosclerosis and acquired medial degeneration. [6-8] Pseudo-aneurysms arise as a consequence of visceral inflammation adjacent to the arterial wall, which damages to the adventitia and leads to thrombosis of the vasa vasorum resulting in localised weakness of the vessel wall. HAA can result from abdominal trauma, transhepatic procedures, such as transjugular intrahepatic portosystemic shunts, pancreatitis, liver transplantation, abdominal trauma, percutaneous biopsy, choledochal cysts and laparoscopic cholecystectomy. [5, 9-12]

Most patients with hepatic artery aneurysm (HAA) are asymptomatic, although some present with upper quadrant pain that radiates to the back, jaundice, pulsatile swelling or symptoms associated with rupture. The risk of rupture is high — about 80% and associated with a mortality rate of up to 50%. [9, 13, 14] Rupture directly into an adjacent viscus (stomach, duodenum and colon), peritoneal/ retroperitoneal cavity or biliary tract leads to hypovolemic shock, GI hemorrhage, biliary colic, hemobilia, or obstructive jaundice. [1,2, 14 -17]

Complications of liver trauma can occur in approximately 20% of patients, including delayed rupture of haematoma (very rare), hemobilia, arterio-venous fistula, pseudo-aneurysm, biloma and abscess formation. [18] Occasionally, patients with blunt abdominal trauma do well initially, but subsequently develop a liver abscess, presumably due to unrecognized liver damage. [18-20] In the present case, the patient had a blunt abdominal trauma with liver laceration which was managed by packing and repeated surgeries. He subsequently developed an infected collection in the area which eroded into the hepatic flexure. The fecal contents then leaked through the drain tract causing an enterocutaneous fistula. Both these factors, i.e. presence of

fecal matter along with abscess, caused destruction and aneurysm formation in a branch of the right hepatic artery exposed due to liver trauma. Rupture of this aneurysm into the cavity communicating with the colon led to massive lower GI bleeding. This is a very rare presentation of erosion and rupture of hepatic artery aneurysm into large gut presenting as massive lower GI bleeding. [21, 22]

HAA are better depicted by spiral or multisection CT because of the ability to image during peak contrast enhancement. [19,20] A dynamic angiographic study may demonstrate the site of active bleeding and the sac of pseudoaneurysms. Once an aneurysm is identified, treatment is indicated regardless of bleeding. [14] Percutaneous transcatheter embolization is the gold standard treatment for intrahepatic HAA, with success rates of 80%-100%. [23-26] In the present case, the initial CT scan done outside did not reveal any aneurysm or fistula formation. However, subsequent CT angiography following a massive episode of lower GI bleeding revealed the aneurysm with leakage of contrast into the large gut. Unfortunately, we did not suspect any vascular pathology or aneurysm at the time of admission either based on clinical history or CT angiography. The patient did give a history of sentinel bleeding as altered blood mixed with fecal matter from the drain site and pooling of contrast in the right sub-diaphragmatic area on initial CT angiography, both of which were ignored. [Figure 2]

Although required in the present case, primary surgery has largely been supplanted by selective angiographic embolisation of intrahepatic aneurysm as the first choice, with surgery reserved for extrahepatic HAA >2cm and embolisation failure. [2,4,13,25, 27] Embolisation should be performed both proximal and distal to the origin of the aneurysm rather than embolisation of the cavity. [12] In the present case, embolisation was planned and fixed on priority in the nearby super-speciality hospital as the same was not available at our hospital. Unfortunately, on the day prior to the planned embolisation the patient developed a second episode of massive lower GI bleeding necessitating emergency exploration. Surgical ligation carries a 20%-29% complication rate and a mortality rate of up to 50% in unstable patients, such as those in shock. [27, 28] The surgical approach involving ligation of hepatic artery distal to celiac axis in patients with delayed haemorrhage is preferred. This preserves hepatic circulation and ensures haemostasis. Proximal control of the hepatic artery should be

attempted first. In the present case, due to dense adhesions in the porta, superficial location and easy access of aneurysm, this was not required. Postoperatively, liver functions should be closely monitored and serial ultrasonography done to check liver perfusion. [28 -30]

CONCLUSION

In conclusion, hepatic artery aneurysms are uncommon lesions that have varied clinical presentations. They should always be suspected after any abdominal trauma with liver injury and infected collection. The natural tendency of these lesions is to erode and rupture either into the peritoneal cavity or into any neighbouring structure like portal vein, stomach, duodenum, biliary tract or colon. High index of suspicion and prompt embolisation can not only save the patient but also avoid surgery which has a high mortality and morbidity in emergency settings. Our case is notable because rupture of HAA into colon leading to massive lower GI bleeding is very rare with very few reported cases in the literature.

References

1. Okuno A, Miyazaki M, Ito H, Ambiru S, Yoshidome H, Shimizu H, Nakagawa K, Shimizu Y, Nukui Y, Nakajima N: Nonsurgical management of ruptured pseudoaneurysm in patients with hepatobiliary pancreatic diseases. *Am J Gastroenterol*; 2001; 96: 1067- 1071.
2. Pasha SF, Gloviczki P, Stanson AW, Kamath PS: Splanchnic artery aneurysms. *Mayo Clin Proc*; 2007; 82:472-479
3. Green MH, Duell RM, Johnson CD, Jamieson NV: Haemobilia. *Br J Surg*; 2001; 88: 773-786.
4. Abbas MA, Fowl RJ, Stone WM, Panneton JM, Oldenburg WA, Bower TC: Hepatic artery aneurysm: factors that predict complications. *J Vasc Surg*; 2003; 38:41-45.
5. Enns R, Schmidt N, Harrison P, Chipperfield P, Skarsgaard P, Brown JA: Endoscopic Diagnosis of a Right Hepatic Artery Pseudoaneurysm. *Endoscopy*; 2002;34(4):337-340.
6. Kibbler CC, Cohen DL, Cruickshank JK, Kushwaha SS, Morgan MY, Dick RD: Use of CAT scanning in the diagnosis and management of hepatic artery aneurysm. *Gut*; 1985;26:752-756.
7. Shanley CJ, Shah NL, Messina LM: Common splanchnic artery aneurysms: splenic, hepatic, and celiac. *Ann Vasc Surg*; 1996;10(3):315-322.
8. Stanley JC, Wakefield TW, Graham LM, Whitehouse WM, Jr, Zelenock GB, Lindenauer SM: Clinical importance and management of splanchnic artery aneurysms. *J Vasc Surg*; 1986;3:836-840.
9. Poon RT, Tuen H, Yeung C: GI hemorrhage from fistula between right hepatic artery pseudoaneurysm and the duodenum secondary to acute cholecystitis. *Gastrointest Endosc*; 2000; 51:491-493.
10. Finley DS, Hinojosa MW, Paya M, Imagawa DK: Hepatic artery pseudoaneurysm: A report of seven cases and a review of the literature. *Surg Today*; 2005, 35(7):543-547.
11. Saluja SS, Ray S, Gulati MS, Pal S, Sahni P, Chattopadhyay TK: Acute cholecystitis with massive upper

Life-Threatening Lower Gastrointestinal Haemorrhage From An Aneurysm Of The Right Hepatic Artery: A Rare Case Presentation Due To Delayed Rupture

gastrointestinal bleed: a case report and review of the literature. *BMC Gastroenterol*; 2007; 7:12.

12. Briceño J, Naranjo A, Ciria R, Sánchez-Hidalgo JM, Zurera L, López-Cillero P: Late hepatic artery pseudoaneurysm: a rare complication after resection of hilar cholangiocarcinoma. *World J Gastroenterol*; 2008; 14:5920-3.

13. Dolapci M, Ersoz S, Kama NA: Hepatic Artery Aneurysm. *Ann Vasc Surg*; 2003;17: 214-216.

14. Reber PU, Baer HU, Patel AG, Wildi S, Triller J, Büchler MW: Superselective microcoil embolization: treatment of choice in high-risk patients with extrahepatic pseudoaneurysms of the hepatic arteries. *J Am Coll Surg*; 1998; 186:325-330.

15. Clay RP, Farnell MB, Farnell, Lancaster JR: Hemosuccus pancreaticus. *Ann Surg*; 1985;202:75-79.

16. Wagner WH, Allins AD, Treiman RL, Cohen JL, Foran RF, Levin PM, Cossman DV: Ruptured visceral artery aneurysms. *Ann Vasc Surg*; 1997;11(4):342-347.

17. Zachary K, Geier S, Pellicchia C, Irwin G: Jaundice secondary to hepatic artery aneurysm: radiological appearance and clinical features. *Am J Gastroenterol*; 1986;81:295-298

18. Gopanallikar A, Rathi P, Sawant P, Gupta R, Dhadphale S, Deshmukh HL: Hepatic artery pseudoaneurysm associated with amebic liver abscess presenting as upper GI hemorrhage. *Am J Gastroenterol*; 1997; 92: 1391-1393.

19. Hsieh CH: Comparison of hepatic abscess after operative and nonoperative management of isolated blunt liver trauma. *Int Surg*; 2002; 87: 178-184.

20. Szentkereszty Z, Peter M, Erdelyi G, Sapy P: Results of surgical treatment of liver abscess, with special emphasis of percutaneous and drainage. *Magy Seb*; 2000; 53: 259-262.

21. Balthazar EJ: "Hemobilia: Calcified hepatic artery aneurysm presenting with massive gastrointestinal bleeding. *Gastrointest Radiol*; 1977 Aug 18;2(1):71-4.

22. H S Narula ,A Kotru, A Nejm: Hepatic artery aneurysm: an unusual cause for gastrointestinal haemorrhage. *Emerg*

Med J; 2005;22:302.

23. Romano L, Giovine S, Guidi G, Tortora G, Cinque T, Romano S: Hepatic trauma: CT findings and considerations based on our experience in emergency diagnostic imaging. *Eur J Radiol*; 2004; 50: 59-66.

24. Jaeckle T, Stuber G, Hoffmann MH, Jeltsch M, Schmitz BL, Aschoff AJ: Detection and localization of acute upper and lower gastrointestinal (GI) bleeding with arterial phase multi-detector row helical CT. *Eur Radiol*; 2008; 18(7):1406-1413.

25. Sasaki K, Ueda K, Nishiyama A, Yoshida K, Sako A, Sato M, Okumura M: Successful utilization of coronary covered stents to treat a common hepatic artery pseudoaneurysm secondary to pancreatic fistula after Whipple's procedure: report of a case. *Surg Today*; 2009; 39:68-71.

26. Kim SY, Kim KW, Kim MJ, Shin YM, Lee MG, Lee SG: Multidetector row CT of various hepatic artery complications after living donor liver transplantation. *Abdom Imaging*; 2007; 32:635-43.

27. Moore E, Matthews MR, Minion DJ, Quick R, Schwarcz TH, Loh FK, Endean ED: Surgical management of peripancreatic arterial aneurysms. *J Vasc Surg*; 2004; 40:247-53.

28. Bender JS, Bouwman DL, Levison MA: Pseudocysts and pseudoaneurysms: Surgical strategy. *Pancreas*; 1995;10:143-147.

29. de Castro SM, Kuhlmann KF, Busch OR, van Delden OM, Laméris JS, van Gulik TM, Obertop H, Gouma DJ: Delayed massive hemorrhage after pancreatic and biliary surgery: embolization or surgery? *Ann Surg*;2005; 241(1):85-91.

30. Miura F, Asano T, Amano H, Yoshida M, Toyota N, Wada K, Kato K, Yamazaki E, Kadowaki S, Shibuya M, Maeno S, Furui S, Takeshita K, Kotake Y, Takada T: Management of postoperative arterial hemorrhage after pancreatobiliary surgery according to the site of bleeding: re-laparotomy or interventional radiology. *J Hepatobiliary Pancreat Surg*; 2009; 16(1):56- 63.

Author Information

Ravindra Singh Mohil

Department of Surgery, V.M. Medical College and Safdarjang Hospital

Nitisha Narayan

Department of Surgery, V.M. Medical College and Safdarjang Hospital

Alakh Narayan

Department of Surgery, V.M. Medical College and Safdarjang Hospital

Zenith Harsh Kerketta

Department of Surgery, V.M. Medical College and Safdarjang Hospital

Siddharth Jain

Department of Surgery, V.M. Medical College and Safdarjang Hospital

Dinesh Bhatnagar

Department of Surgery, V.M. Medical College and Safdarjang Hospital