

# Endotracheal Tube Positioning Using A Flexible Fiberoptic Bronchoscope During Tracheoesophageal Fistula Repair

M Greenberg, G Cheng, B Lassasso, D Collins, K Vanderwall

## Citation

M Greenberg, G Cheng, B Lassasso, D Collins, K Vanderwall. *Endotracheal Tube Positioning Using A Flexible Fiberoptic Bronchoscope During Tracheoesophageal Fistula Repair*. The Internet Journal of Anesthesiology. 2006 Volume 12 Number 1.

## Abstract

We report the use of flexible fiberoptic bronchoscopy to accurately position the endotracheal tube prior to TEF repair.

## INTRODUCTION

Tracheoesophageal fistula (TEF) repair in newborns can be challenging to the anesthesiologist because of the anatomic derangements that can lead to severe cardio-pulmonary compromise. Knowledge of the exact location of the fistulae is key to preventing untoward outcomes such as gastric distention and respiratory compromise. We report the use of a flexible fiberoptic bronchoscope (FOB) to accurately position the endotracheal tube prior to TEF repair.

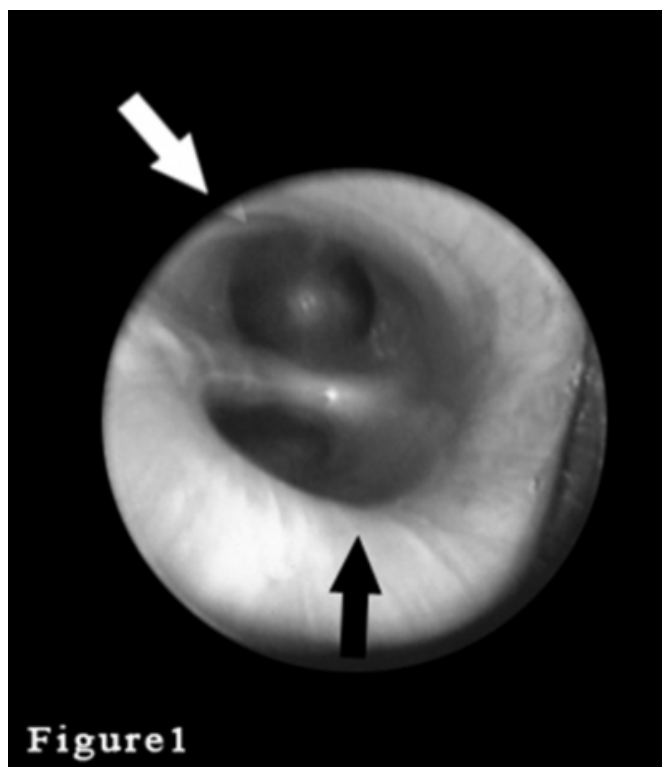
## CASE REPORT

A 2.5 kilogram female with trisomy 21, TEF and endocardial cushion defect was scheduled for TEF repair. She was also noted to have a coarctation of the aorta and was on a PgE1 infusion, to maintain patency of the ductus arteriosus. Prior to the operation, the baby was hemodynamically stable and breathing unassisted with an FiO<sub>2</sub> of 0.21. Anesthesia was induced with sevoflurane and oxygen while maintaining spontaneous ventilation. After the larynx was anesthetized with topical lidocaine, a 3.0 mm rigid bronchoscope was inserted into the trachea under direct vision. A large TEF was noted in the posterior trachea approximately 3 cm above the carina (figure 1). Subsequently, under direct laryngoscopy with a Miller 0 blade, a cuffed 3.0 (Mallinckrodt) endotracheal tube (ETT) was placed into the trachea. Immediately following the insertion of the ETT, a 2.5 mm FOB was inserted into the ETT, and the ETT was advanced under direct vision to just above the carina but distal to the fistula. At this point the cuff on the ETT was inflated and positive pressure ventilation started. There were equal breath sounds bilaterally on auscultation without gastric distention. A chest

radiograph was taken which showed the ETT in the trachea just above the carina. The patient underwent gastrostomy placement followed by successful closure of the TEF via a right thoracotomy.

## Figure 1

Figure 1: Photograph of TEF, from rigid bronchoscope. Black arrow denotes TEF and white arrow denotes carina



## DISCUSSION

The most common type of TEF, type C, consists of esophageal atresia with a fistula between the distal esophagus and distal trachea. Since there is no direct

connection between the oral cavity and the stomach, gas entrained in the stomach during respiration, cannot be expelled leading to gastric distention and respiratory compromise. Knowledge of the exact location of the fistula is crucial to proper endotracheal tube positioning and prevention of these problems. Rigid bronchoscopy prior to thoracotomy provides excellent information as to the location of the fistulae and has been recommended <sup>(1,2,3,4,5,6)</sup>.

When the anatomy is favorable as in this case, where the fistula is proximal to the carina, exclusion of the fistula is possible and highly desired. Exact placement of the endotracheal tube after bronchoscopy becomes critical. Because the smallest FOB can fit through a 2.5 mm ETT, it becomes a very useful tool for ETT positioning in these situations. Although a clinical exam can also be used for tube positioning, it lacks the accuracy of direct visualization. In many cases the location of the fistulae is such that exclusion of the fistula is not possible. In these cases one can place a Fogarty catheter into the fistulae and inflate the balloon to prevent gastric distention <sup>(4,5,6,7)</sup>. Once the fistula is ligated, exact positioning of the ETT becomes less important, and the cuff on the ETT can be deflated if appropriate. Ventilation of the lungs during the flexible bronchoscopy procedure may be difficult due to the space occupied by the bronchoscope. Care should be taken to prevent over-inflation of the lungs due to air trapping by the scope <sup>(8)</sup>.

In conclusion, we present the case of a large TEF, in which the ETT could be positioned to exclude the esophageal fistulae. We believe both rigid and flexible bronchoscopy should be available for these cases with their use dependent on each patient's unique anatomy. In cases such as this one, a cuffed ETT may be accurately positioned to exclude the fistula allowing for an easier and safer operation.

## References

1. Templeton JM Jr, Templeton JJ, Schnauffer L, Bishop HC, Ziegler MM, O'Neill JA Jr. Management of esophageal atresia and tracheoesophageal fistula in the neonate with severe respiratory distress syndrome. *J Pediatr Surg*. 1985;20(4):394-7.
2. Pigna A, Gentili A, Landuzzi V, Lima M, Baroncini S. Bronchoscopy in newborns with esophageal atresia. *Pediatr Med Chir*. 2002;24(4):297-301.
3. Goyal A, Potter F, Losty PD. Transillumination of H-type tracheoesophageal fistula using flexible miniature bronchoscopy: an innovative technique for operative localization. *J Pediatr Surg*. 2005;40(6):e33-4.
4. Andropoulos DB, Rowe RW, Betts JM. Anaesthetic and surgical airway management during tracheo-oesophageal fistula repair. *Paed Anaesth* 1998; 8:313-319
5. Reeves ST, Burt N, Smith CD. Is it time to reevaluate the airway management of tracheoesophageal fistula? *Anesth Analg* 1995; 81:866-869.
6. Kosloske AM, Jewell PF, Cartwright KC. Crucial bronchoscopic findings in esophageal atresia and tracheoesophageal fistula. *J Pediatr Surg* 1988; 23:466-470
7. De Gabriele LC, Cooper MG, Singh S, Pitkin J. Intraoperative fibreoptic bronchoscopy during neonatal tracheo-oesophageal fistula ligation and oesophageal atresia repair. *Anaesth Intensive Care*. 2001 Jun;29(3):284-7.
8. Iannoli ED, Litman RS Tension pneumothorax during flexible fiberoptic bronchoscopy in a newborn. *Anesth Analg*. 2002 Mar;94(3):512-3

**Author Information**

**Mark Greenberg, M.D.**

Associate Professor of Anesthesiology, University of California San Diego (UCSD), Children's Hospital San Diego

**Gloria Cheng, M.D.**

Resident in Anesthesiology, University of California San Diego (UCSD), Children's Hospital San Diego

**Barry Lassasso, M.D.**

Director of Trauma Surgery, University of California San Diego (UCSD), Children's Hospital San Diego

**David Collins, M.D.**

Staff Surgeon, University of California San Diego (UCSD), Children's Hospital San Diego

**Karen Vanderwall, M.D.**

Staff Anesthesiologist, University of California San Diego (UCSD), Children's Hospital San Diego