

Unrecognized Massive Hydrothorax During Supracostal Approach For Percutaneous Nephrostolithotomy

S Çakmakaya, Z Salihoğlu, ? Demirel, Y Kose

Citation

S Çakmakaya, Z Salihoğlu, ? Demirel, Y Kose. *Unrecognized Massive Hydrothorax During Supracostal Approach For Percutaneous Nephrostolithotomy*. The Internet Journal of Anesthesiology. 2007 Volume 16 Number 1.

Abstract

In the last years percutaneous nephrolithotomy is very often used in the therapy of urinary calculi. Supracostal approach is favorable in the therapy of upper calices calculi, but the risk of pneumothorax and hydrothorax should be considered. In our case report; a hydrothorax complication of percutaneous nephrolithotomy performed via supracostal approach is presented.

INTRODUCTION

Percutaneous nephrolithotomy (PCNL) is a new method that has been used in the urinary calculi in the recent years (1). It is preferred to closed approach because of its many advantages compared to open approach but because of the technique used in these operations many complications are also observed. While hydrothorax, pneumothorax are of common complications; cardiac arrest, acute respiratory distress syndrome (ARDS) are observed rarely (2). Especially supracostal approach carries a higher risk of intrathoracic complications. (3)

Hydrothorax and pneumothorax can be hard to recognize in these patients mainly because of the prone position (2).

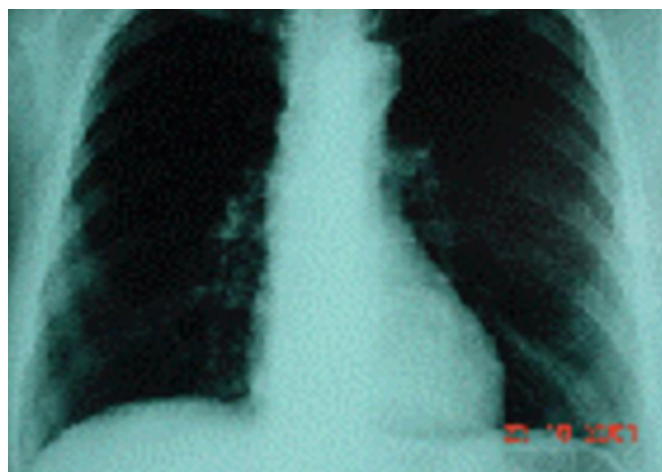
Here we aimed to report a complication of hydrothorax that was recognized only at the end of a PCNL operation with a supracostal approach.

CASE REPORT

A 48 year old female patient who was diagnosed with nephrolithiasis in the upper calix was planned to undergo PCNL operation. In the pre-operative evaluation only presence of smoking and hypertension that was under control with the treatment of beta blockers were observed. Systemic blood pressure and heart rate was observed as 130/70 mmHg and 75/min respectively. Preoperative X-ray of the lungs (picture 1) and ECG was normal.

Figure 1

Picture 1: preoperative X ray of the lungs



Electrocardiography (ECG), invasive arterial blood pressure, end tidal (EtCO₂) values were monitored during the surgery (Millennia, Orlando, USA). 2 mg kg⁻¹ propofol and 2 µg kg⁻¹ fentanyl were used for the induction of anesthesia and trachea was intubated after the administration of 0.2 mg kg⁻¹ cisatracurium. Mechanical ventilation was performed with a FiO₂ 50% and tidal volume of 10 ml kg⁻¹ and respiratory frequency of 12 min⁻¹. (Dräger Sula 808 V) Anesthesia was maintained with 1% isoflurane. 1 µg kg⁻¹ fentanyl and 0.03 mg kg⁻¹ cisatracurium doses were repeated with certain intervals.

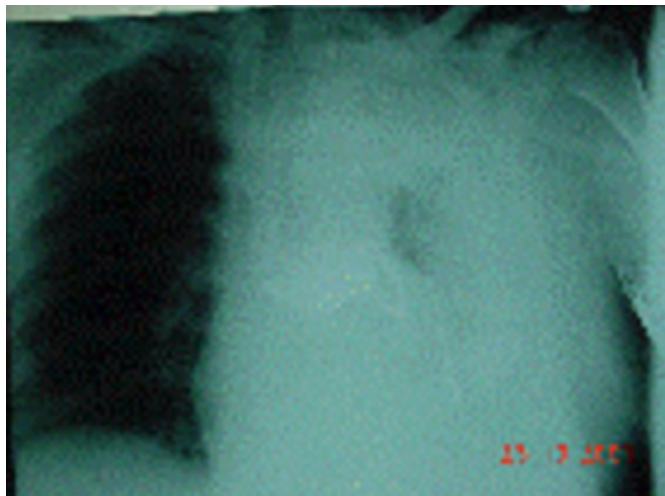
Following the induction, the operation started in prone position. During the operation heart beat, systolic and diastolic blood pressures were in normal limits. In the last quarter of the operation, while the mean arterial pressure

dropped from 90 mmHg to 53 mmHg rapidly no change was observed in the heart beat. The auscultation of the lungs showed that there was no significant difference among the two hemithorax. The arterial blood gas sample taken was as followed: pH: 7.35, PCO_2 : 35.2, PO_2 : 143, HCO_3^- : 24.9, BE: -1.9 SPO_2 : 96. As the surgery ended the mean arterial pressure was 75 mmHg. The patient was put back into supine position; the neuromuscular blockage was reversed by the administration of 0.01 mg kg^{-1} atropine and 0.02 mg kg^{-1} neostigmine and the trachea was extubated.

In the recovery room the patient started complaining about the respiratory distress he has. The auscultation showed a decrease sounds the left hemithorax. A new arterial blood gas sample was acquired and chest x-ray was taken. The arterial blood gas sample showed pH: 7.31, PCO_2 : 40.2, PO_2 : 44.3, HCO_3^- : 19.9, BE: -5.9 SPO_2 : 88% while the patient was breathing 50% oxygen with an ventury mask. The patient was diagnosed as left hydrothorax in light of the x-ray. (Picture 2).

Figure 2

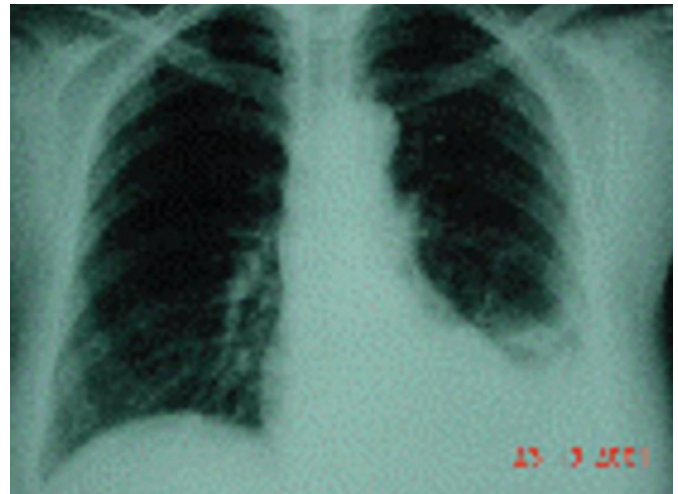
Picture 2: Massive hydrothorax



Thoracic tube was placed in to the left hemithorax rapidly and 800 cc irrigation fluid was drained. (Picture 3).

Figure 3

Picture 3: Postoperative lungs x-ray graphy



The patient was taken to ICU and the tube was taken out the next day and sent to his room when no additional fluid drainage was observed. The patient was released off from the hospital on the 3rd day of the operation.

DISCUSSION

Percutaneous nephrolithotomy (PCNL) is a new method that has been used in the urinary calculi in the recent years. Although it pretends a large incision and decrease the time of the stay in hospital it carries the risk of some unexpected complications.

Especially supracostal approach carries a higher risk of intrathoracic complications. Munver et al used supracostal approach to 98 patients out of 300 PCNL cases between 1993-1999 (4). They have recorded the complications they have observed as bleeding, haemathorax, hydrothorax, sepsis, atrial fibrillation, nephropleural fistula, pulmonary embolism, renal arterial pseudoaneurism , pneumothorax, subcapsuller heamatoma and stated that the rate of intrathoracic complications were 23 %. In our case where we have observed hydrothorax, the subcostal approach was used.

Prone position is required for PCNL. Munshi et al. (2) reported that they were also not able to recognize hydrothorax in a similar patient until the end of the operation and blamed the prone position. Hydrothorax was realized after the spontaneous ventilation was achieved and the patient was in supine position. The auscultation was normal during the operation but in the second hour of the operation it was noted that airway pressures had risen and thorax tube was placed and 1500 ml fluid was drained when

hydropneumothorax was seen in the X-ray. In our case the only symptom was a decrease in the mean arterial pressure. We were not able to diagnose the hydrothorax during the surgery for the auscultation and the blood gas samples were all normal. After the spontaneous ventilation was achieved and the patient was in supine position, the blood gas samples and the auscultation supported hydrothorax diagnosis so that it was realized. In our case supracostal approach was used in the last period of the surgery so that was when the irrigation fluid started to infiltrate to thorax and that was the reason we misinterpreted the auscultation.

As a result PCNL operations carry a risk of hydrothorax and it can be hard to diagnose because of the position of the patient. We also believe that any sign that is not expected in the intraoperative period must be evaluated carefully so that complications can be realized earlier.

CORRESPONDENCE TO

Dr. Ziya Salihoglu Address; 7-8 Kisim Ata sitesi Deniz 9 blok daire no: 67 34750 Ataköy-Istanbul/TURKEY
Telephone: 00902125732042 Fax Number:
00902125295600 E-Mail: zsalihoglu@yahoo.com

References

1. Pugach JL, Moore RG, Parra RO, Steinhardt GF. Massive hydrothorax and hydroabdomen complicating percutaneous nephrolithotomy. *The Journal of Urology* 1999; 162:2110-1.
2. Munshi CA, Bardeen-Henschel A. Hydropneumothorax after percutaneous nephrolithotomy. *Anesth. Analg* 1985; 64:840-2
3. Pearle MS, Nakada SY, Womack JS, Kryger JV. Outcomes of contemporary percutaneous nephrostolithotomy in morbidly obese patients. *The Journal of Urology* 1998;160:669-73.
4. Munver R, Delvecchio FC, Newman GE, Preminger GM. Critical analysis of supracostal access for percutaneous renal surgery. *The Journal of surgery* 2001;166:1242-6.

Author Information

Serpil Çakmakkaya, MD

Staff Anesthesiologist, Department of Anaesthesiology and Reanimation, Cerrahpasa Medical School, Istanbul University

Ziya Salihoğlu, MD

Asc. Professor, Department of Anaesthesiology and Reanimation, Cerrahpasa Medical School, Istanbul University

Şener Demirel, MD

Staff anaesthesiologist, Department of Anaesthesiology and Reanimation, Cerrahpasa Medical School, Istanbul University

Yildiz Kose, MD

Prof., Department of Anaesthesiology and Reanimation, Cerrahpasa Medical School, Istanbul University