

Intestinal malrotation mimicking superior mesenteric artery syndrome

V Agrawal, R Agrawal, V Raina, D Sharma

Citation

V Agrawal, R Agrawal, V Raina, D Sharma. *Intestinal malrotation mimicking superior mesenteric artery syndrome*. The Internet Journal of Surgery. 2008 Volume 18 Number 2.

Abstract

Intestinal malrotation can be confused with other causes of duodenal obstruction. We report a case of malrotation which, on investigations, mimicked superior mesenteric artery syndrome. A ten-year-old male presented with history of abdominal trauma followed by severe loss of weight and bilious vomiting. Radiological features were suggestive of superior mesenteric artery syndrome and were confirmed as case of malrotation on exploration.

INTRODUCTION

Intestinal malrotation can be confused with other causes of duodenal obstruction. We report a case of malrotation which, on investigations, mimicked superior mesenteric artery syndrome.

CASE REPORT

A ten-year-old male presented following blunt abdominal trauma after fifteen days of injury with recurrent bilious vomiting. The patient had a history of an exploratory laparotomy for liver tear followed by weight loss of 7 kg. Plain X-ray of the abdomen revealed a distended stomach with gasless abdomen. Ultrasound of the abdomen revealed a dilated duodenum up to the third part and thickening of duodenal wall (Figure I).

The superior mesenteric artery was on the left side of the corresponding vein, suggestive of normal relationship. The SMA-to-aorta angle was 35 degree. A contrast study showed dilated duodenum up to the third part, with abrupt longitudinal cutoff at the distal third part. There was no evidence of duodenal corkscrew sign or z-sign ruling out malrotation (Figure II).

Figure 1

Figure 1: USG showing dilated thick-walled duodenum

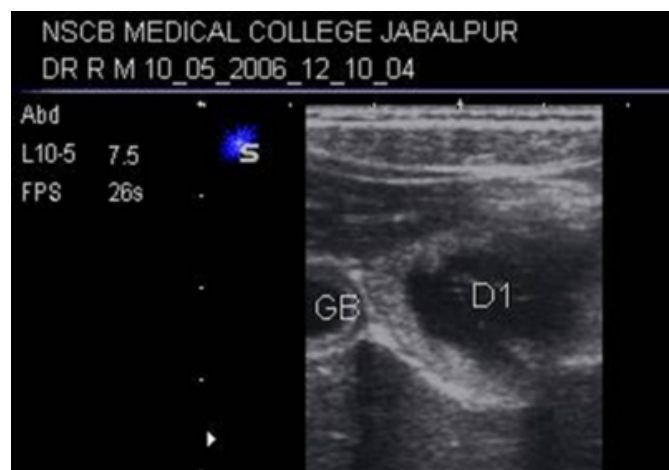
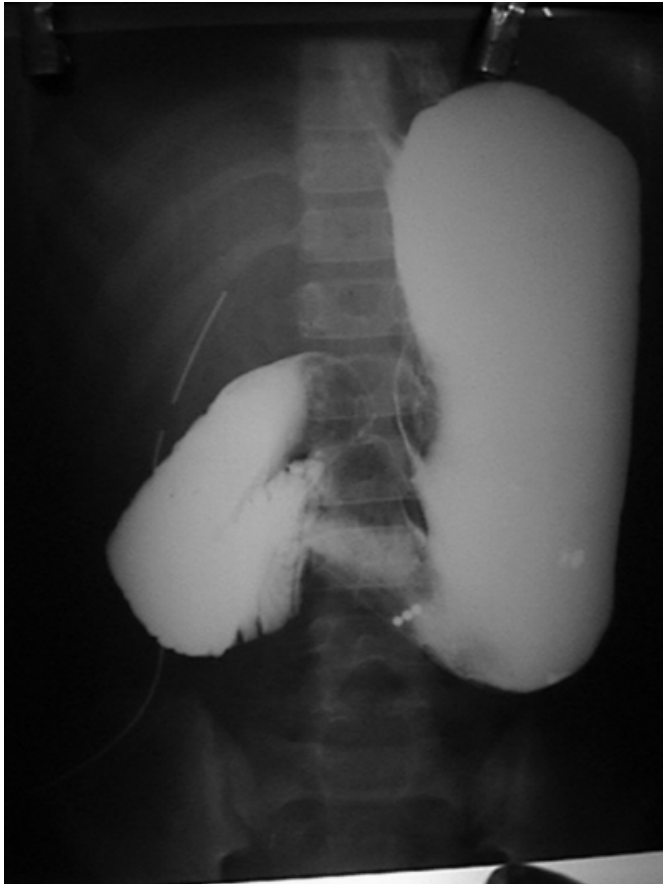


Figure 2

Figure 2: Upper gastrointestinal study showing abrupt cutoff in the third part of the duodenum



A diagnosis of superior mesenteric artery syndrome with a second possibility of adhesive intestinal obstruction was postulated.

The patient failed to respond to conservative treatment and was explored. Findings were suggestive of malrotation with Ladd's bands. A diagnosis of malrotation (incomplete rotation) was made and correction was done. The patient recovered well.

DISCUSSION

Malrotation of the intestines results when intestinal rotation and fixation fail to occur during pregnancy. The bowel rotates in place to the left of the SMA at the ligament of Treitz. Ultrasonography has been shown to be very sensitive (approximately 100%) in detecting malrotation. Sonographic features suggestive of malrotation include inversion of the SMA and the superior mesenteric vein (SMV) relationship, fixed midline bowel loops and duodenal dilation with distal tapering, and volvulus is highly probable if the SMV is shown to be coiling around the SMA with whirlpool sign. [1]

Upper GI series shows contrast ending abruptly at the second part of the duodenum or tapering in a corkscrew pattern at the duodenojejunal junction in the midline or to the right side. CT scanning is more often done nowadays and can be more informative but is not recommended as the principal diagnostic tool. [12]

Superior mesenteric artery (SMA) syndrome (Wilkie's syndrome) is an atypical cause of high intestinal obstruction, most frequently occurring in patients who have had rapid weight loss following abdominal trauma. Identification of this syndrome can be a diagnostic dilemma and is frequently made by exclusion. The most common cause is a reduction in the angle formed by the SMA and the abdominal aorta due to fat loss, which causes entrapment of the third portion of the duodenum. [3] The angle between these vessels usually is 45° , with a range between 38° and 60° . In SMA syndrome, the angle is sharply decreased, ranging from 6° to 25° . The aortomesenteric distance is also diminished. Normal distance is from 10 to 20mm, whereas in SMA syndrome it is reduced to 2 to 8mm. [34] USG and CT scan can provide this information. Upper GI series reveal dilated first, second and third portions of the duodenum, abrupt compression of the duodenal mucosal folds, to-and-fro movement of barium proximal to the obstruction, delay of 4 to 6 hours in gastroduodenal transit, and relief of the obstruction in the left lateral decubitus position. [4]

Intestinal malrotation is likely to be missed radiologically if it is incomplete rotation and the DJ flexure lies in the midline, hence SMA-SMV relationship may remain normal. Obstruction at the third part of the duodenum is unusual in malrotation as Ladd's bands cross the second part. The normal vascular relations, obstruction at the third part of the duodenum, a borderline SMA-aorta angle, and the corresponding history of trauma and weight loss were misleading to the diagnosis of superior mesenteric artery syndrome in this patient. Undoubtedly, CT may be more informative in such situations.

References

1. Torres AM, Ziegler MM. Malrotation of intestine. *World J Surg* 1993; 17: 326-31
2. Pickhardt PJ, Bhalla S. Intestinal malrotation in adolescents and adults: Spectrum of clinical and imaging features. *AJR* 2002; 179: 1429-35
3. Raissi B, Taylor B, Traves D: Recurrent superior mesenteric artery (Wilkie's) syndrome: a case report. *Can J Surg* 1996; 39: 410-416
4. Fromm S, Cash J: Superior mesenteric artery syndrome: an approach to the diagnosis and management of upper gastrointestinal obstruction of unclear etiology. *S D J Med* 1990; 43: 5-10

Author Information

Vikesh Agrawal

Associate Professor, Pediatric Surgery

Rekha Agrawal

Assistant Professor, Radiodiagnosis

V.K. Raina

Professor Pediatric, Surgery

D. Sharma

Professor, Surgery