

Deflation failure of Accura Balloon In Left Atrium During Balloon Mitral Valvuloplasty

P Bansal, M Gupta, R Yadave, D Agarwal

Citation

P Bansal, M Gupta, R Yadave, D Agarwal. *Deflation failure of Accura Balloon In Left Atrium During Balloon Mitral Valvuloplasty*. The Internet Journal of Cardiology. 2009 Volume 9 Number 1.

Abstract

Currently Percutaneous Balloon Mitral Valvuloplasty has established itself as a standard treatment for patients with severe mitral stenosis. A patient with severe mitral stenosis was posted for the above procedure. After dilatation of mitral valvular apparatus the Accura balloon failed to deflate on repeated aspirations, probably due to rupture of internal lumen. Finally, a guide wire was passed through the injection port which recanalized the lumen and dye was slowly aspirated after diluting with saline.

INTRODUCTION

Almost all mitral stenosis (MS) is rheumatic in etiology.¹ PBMV using the Accura or Inoue balloon catheter is now an established mode of therapy for suitable cases of mitral stenosis with a success rate of more than 90% in various studies.^{2,3}

Balloon valvuloplasty occasionally is associated with complications, including death in 0 to 1%, moderate or severe valvular regurgitation in 2 to 3%, and systemic embolization in 1 to 3%.^{1,2,4}

We hereby report an unusual complication of deflation failure of Accura balloon (Vascular Concepts Limited, China) after dilatation of the mitral valve inside the left atrium.

CASE REPORT

A 45 year male patient was admitted to hospital with chief complains of dyspnea on minimal exertion and palpitations. Laboratory investigations were within normal limits, Chest X-ray showed prominent pulmonary artery segment and hilar vessels while ECG showed P-wave duration of 0.16 sec in lead II (left atrial enlargement), right axis deviation with right ventricular hypertrophy. Echo-Doppler study revealed severe Mitral stenosis (MVOA 0.9cm²) with mild mitral regurgitation, severe Pulmonary Artery Hypertension, dilated left atrium and right ventricle and Ejection Fraction of 60%. Patient was posted for PBMV under monitored anaesthesia care.

In the cardiac catheterization laboratory monitors were attached and baseline data was recorded. As the patient was apprehensive, sedation was provided with midazolam 3 mg given in titrated doses. Accura balloon catheter sized 28 mm which had been used earlier and sterilized in 2% glutaraldehyde solution was checked for their integrity and functioning pre-procedurally. Right femoral vein was cannulated and balloon catheter was advanced in left atrium following transseptal puncture using the Brockenbrough technique.

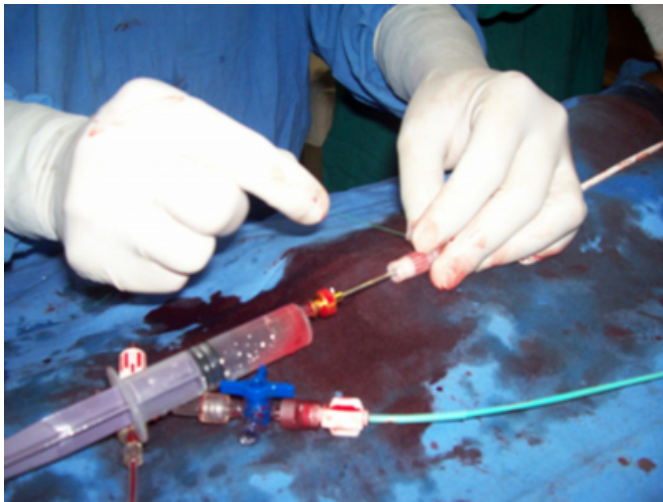
The hour-glass shaped balloon was placed in mitral orifice and inflated using Iohexol dye (1:4 dilutions in saline). Dilatation was done and the transmitral end-diastolic gradient was decreased to 6 mmHg with a mean left atrial pressure of 10mmHg. After dilatation of the tight waist in mitral orifice and achieving reductions in left atrial pressures, attempts made to deflate the balloon using 20 ml syringe failed. Continuous suctioning for next 10 minutes did not result in balloon deflation. Small volume of heparinised saline pushed through inflation lumen to restore its patency, moved in freely but failed to move out on negative aspiration. J-shaped stylet was passed through the central lumen which moved freely inside and ruled out kink in the shaft of catheter. As the shape of Accura balloon was uniform and circular a rupture of internal wall of balloon was suspected.

Finally, a BMW Percutaneous Transluminal Coronary Angiography (PTCA) wire Gauge 0.014 inch² and 190 cm in length (Abott Vascular, U.S.A) was passed through inflation

port in the lumen (Fig.1).

Figure 1

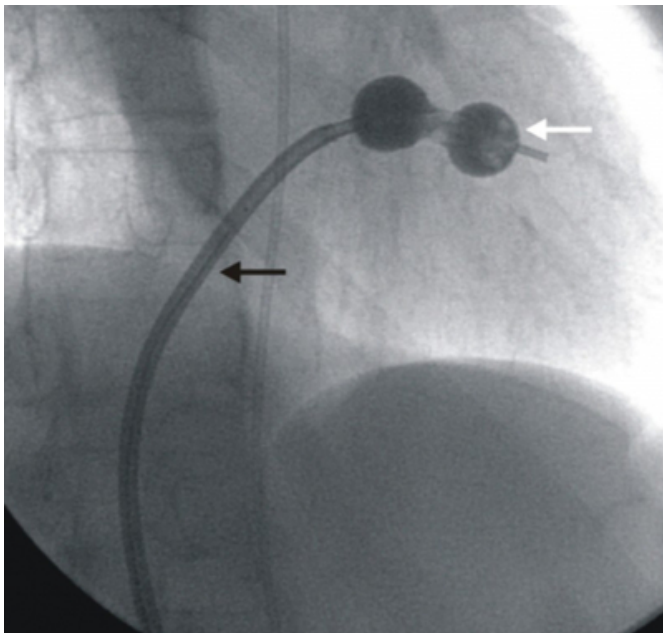
Fig. 1: PTCA wire passed through inflation port in the lumen



At the site of resistance gentle rotations were given to PTCA wire until it gradually passed beyond the damaged segment. After repeated probing with PTCA wire, slow aspiration with syringe resulted in retrieval of the dye and air (Fig.2).

Figure 2

Fig. 2: Partially deflated Accura balloon with some retained air (white arrow) and PTCA wire (black arrow) in vivo



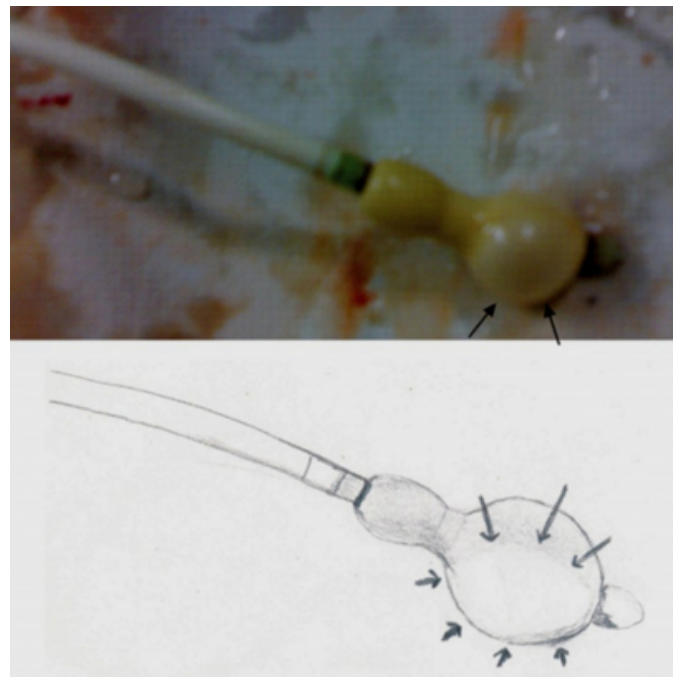
The assembly was removed and patient was shifted to Cardiac ICU for post-procedural monitoring. No adverse hemodynamic changes were observed during the procedural period.

Deflation failure of the balloon assembly was confirmed ex-

vivo (Fig. 3).

Figure 3

Fig. 3: Bulging weak and thin wall of damaged Accura balloon demonstrated ex-vivo and in sketch (arrows)



The valve area and mitral regurgitation were assessed by 2-D and color-flow Doppler echocardiography in post-operative period. The procedure was considered successful as final absolute mitral valve area increased to 1.8 cm² with minimal mitral regurgitation.

Patient was discharged after 2 days and was asymptomatic at 3 months follow up.

DISCUSSION

Failure of deflation of PBMV balloon is a rare complication having a strong association with reused balloons. Till date only four cases with a similar complication have been reported in literature, out of innumerable PBMV's performed worldwide.⁵

A similar case of non-deflation of Inoue balloon was reported where herniation occurred in walls of Inoue balloon and deflation was achieved with a risk of air embolism by puncturing the balloon using blunt end of spring guide wire, passed through inflation port.⁵

In one report, non-deflation of balloon catheter occurred in an infant with transposition of the great arteries (D-TGA) undergoing a Rashkind (atrial) septostomy. Deflation in that case was achieved with a fine-gauge needle introduced

percutaneously via a transhepatic approach.⁶

In our case, the probable mechanism of occlusion was rupture of inner layer of Accura balloon and sticking of its walls which acted as one-way valve, thereby opening on positive pressure during saline injection and collapsing on negative pressure during aspiration.

Sticking of luminal walls could also be attributed to the stickiness of highly viscous Iohexol dye.

Passing of PTCA wire through this damaged segment separated the adherent layers and restored the patency.

The technique of over inflation of balloon to the point of rupture has been an old practice for non-deflating Foley's catheter but was not recommended in this case as some air was also present in the balloon, which could have lead to embolization and devastating complications.⁷

Another method of deflating this balloon is by puncturing it with a transseptal needle, which was our next option if deflation had been unsuccessful.⁸

The above technique of recanalising inflation lumen with guide wire has not been described in literature but proved to be successful, else the patient would had undergone another transseptal puncture or been shifted for cardiac surgery with assembly in situ, for extraction of balloon.

In developing countries, the practice of sterilizing and reusing costly equipments is practiced frequently at many centers. Furthermore, there is no consensus on the number of times the PBMV catheter can be resterilized and reused, though the manufacturers recommend it for single use only. The reused assembly is more likely to damage intraoperatively, though checked for integrity pre-

procedurally, as was our case. In previous studies the incidence of balloon malfunction has been reported to be higher (20%) with reused balloons as compared to new balloons (<0.5%), which supports our claim.^{9,10}

The authors hereby recommend that reused PBMV balloons should be best avoided and our technique of Accura balloon deflation may be employed in an event of similar complication.

References

1. Jeffery J. Popma, Donald S. Baim, Frederic S. Resnic. Percutaneous coronary and valvular intervention; Braunwald's heart disease (8th edition); Philadelphia, Saunders, 2008: Ch. 55; 1646-1655
2. Fawzy ME. Percutaneous mitral balloon valvuloplasty; Catheter Cardiovasc Interv. 2007 Feb; 69(2): 313-21
3. S Mishra, R Narang, M Sharma, et al. Percutaneous Transseptal Mitral Commissurotomy in Pregnant Women with Critical Mitral Stenosis. Indian Heart J 2001; 53: 192-196
4. Hung, Jui-Sung; Lau, Kean-Wah; Lo, Ping-Han; Chern, Ming-Shyan; Wu, Jong-Jen. Complications of Inoue balloon mitral commissurotomy: Impact of operator experience and evolving technique; American Heart Journal. July 1999; 138(1):114-121
5. Charan P. Lanjewar, Pratap J. Nathani, Praffula G. Kerkar. Failure of deflation of an Inoue balloon during percutaneous balloon mitral valvuloplasty. Journal of Interventional Cardiology; 19(3) 2006: 280-282
6. Nigel J. Wilson, J. A. Gordon Culham, George G. S. Sandor .Successful treatment of a nondeflatable balloon atrial septostomy catheter;
7. Ta-Chong Lin, Hueh Long Shieh, Mao Sheng Lin, Chow Tse Chen, Chi Shiang Wu, Yi Ching Lin. An Alternative Technique for Deflation of a Non-deflating Balloon in a Small Caliber F8 Foley Catheter in Women; JTUA 20:32-3, 2009
8. Patel MT, Dani S. Unsuccessful deflation of a Bifoil balloon during percutaneous balloon mitral valvuloplasty. Cathet Cardiovasc Diagn 1996; 37: 290-292
9. Dev V, Shrivastava S. Balloon rupture during valvuloplasty. Am Heart J, 1990; 119: 1441-1442
10. Kerkar PG, Dalvi BV. Unusual tear in Inoue balloon during PTMV in a patient with calcific mitral stenosis. Cathet Cardiovasc Diagn, 1994;31:127-129

Author Information

Pranav Bansal, M.D.

Assistant Prof., Dept. of Anaesthesiology in Teerthanker Mahaveer Medical College, Moradabad (U.P.)

Mamtesh Gupta, M.D.

Senior Consultant, Dept. of Cardiology, Dhanvantri Jeevan Rekha Heart Care Hospital, Meerut (U.P.)

Ram Dev Yadave, M.D.

Senior Consultant, Dept. of cardiology, Batra Hospital and Medical research centre, New Delhi

Deepti Agarwal, M.D.

Associate Prof., Dept. of Pathology in Teerthanker Mahaveer Medical College, Moradabad (U.P.)