

# Surgical correction of the enlarged tongue

A Taher

## Citation

A Taher. *Surgical correction of the enlarged tongue*. The Internet Journal of Head and Neck Surgery. 2008 Volume 3 Number 1.

## Abstract

## INTRODUCTION

Macroglossia is tongue enlargement that leads to functional and cosmetic problems. Although this is a relatively uncommon disorder, it may cause significant morbidity. There is no clear definition of macroglossia and it may be defined in relative, functional, or structural terms. Clinical studies are limited by this lack of a clear definition.

Normal speech and swallowing require normal tongue anatomy and function. Swallowing begins as the tongue mixes food with saliva to form a food bolus, which is then propelled into the pharynx by the tongue. Articulation also depends on the tongue's ability to alter the impedance of air, and change the resonant characteristics of the upper airway. macroglossia, increased tongue bulk may impair these functions.

There are two types of enlarged tongue ,pseudomacroglossia and true macroglossia. [1234567891011121314]

The possible causes for the Pseudomacroglossia are:

- Habitual posturing of the tongue
- Enlarged tonsils and/or adenoids displacing tongue
- Low palate and decreased oral cavity volume displacing tongue
- Transverse, vertical, or anterior/posterior deficiency in the maxillary or mandibular arches displacing the tongue
- Severe mandibular deficiency (retrognathism)
- Neoplasms displacing the tongue
- Hypotonia of the tongue

True macroglossia can be subdivided into 2 main

subcategories: congenital causes and acquired causes.

### Congenital causes

- Idiopathic muscle hypertrophy
- Gland hyperplasia
- Hemangioma
- Lymphangioma
- Down syndrome
- Beckwith-Wiedemann syndrome
- Behmel syndrome
- Lingual thyroid
- Gargoylism
- Transient neonatal diabetes mellitus
- Trisomy 22
- Laband syndrome
- Lethal dwarfism of Blomstrand
- Mucopolysaccharidoses
- Skeletal dysplasia of Urbach
- Tollner syndrome
- Autosomal dominant inheritance
- Microcephaly and hamartoma of Wiedemann
- Ganglioside storage disease type I

Acquired causes (Categories have been assigned to simplify the list, but there can be overlap of a particular etiology into

more than one of these categories.)

- Metabolic/endocrine
- Hypothyroidism
- Cretinism
- Diabetes
- Inflammatory/infectious
- Syphilis
- Amebic dysentery
- Ludwig angina
- Pneumonia
- Pemphigus vulgaris
- Rheumatic fever
- Small pox
- Typhoid
- Tuberculosis
- Actinomycosis
- Giant cell arteritis
- Candidiasis
- Scurvy
- Pellagra
- Systemic/medical conditions (Hormonal and non hormonal factors)
- Uremia
- Myxedema
- Hypertrophy
- Acromegaly
- Neurofibromatosis
- Iatrogenic macroglossia
- Traumatic
- Surgery

- Hemorrhage
- Direct trauma (eg, biting)
- Intubation injury
- Radiation therapy
- Neoplastic
- Lingual thyroid
- Lymphangioma
- Hemangioma
- Carcinoma
- Plasmacytoma
- Infiltrative
- Amyloidosis
- Sarcoidosis

Macroglossia of either types may produce displacement of teeth and malocclusion because of the strength of the muscles involved the pressure exerted by the tongue on the teeth ,it is not uncommon to see crenation or scalloping of the lateral border of the tongue in this condition the tip of the scallops fitting into the inter proximal spaces between the teeth, and the tip of the tongue protruded causing an open bite.

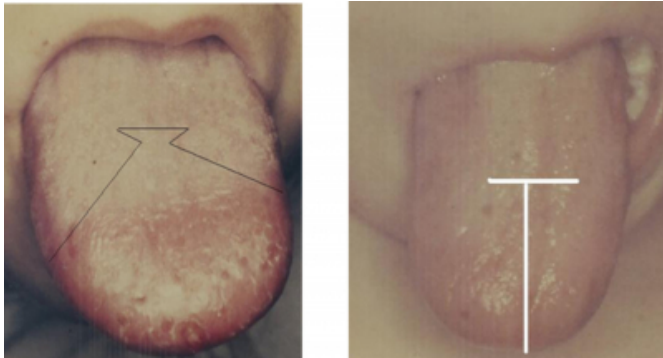
The majority of cases of macroglossia are treated surgically. Indications for surgery include airway obstruction, speech difficulties, dysphagia, and cosmetics. The procedure of choice is partial glossectomy. Surgical goals are to reduce the tongue size and produce improved function. Good airway management is important in the postoperative period. For small children and infants this may be done with tracheotomy, and in older children prolonged intubation may be adequate.

Different authors have advocated a number of different approaches for tongue reduction 3-6,14. Rather than using one approach, each case should be evaluated and the appropriate surgical approach chosen. Different resections provide reduction in different directions. Regardless of the approach taken the initial resection should be conservative to prevent permanent problems from overly aggressive resection. The technique used is an anterior wedge resection

with posterior key hole. The lateral incisions are beveled out to decrease tongue bulk. The tongue is then closed in a T shape closure. Fig 1,2

**Figure 1**

Figure 1 & : Surgical out line and the closure shape



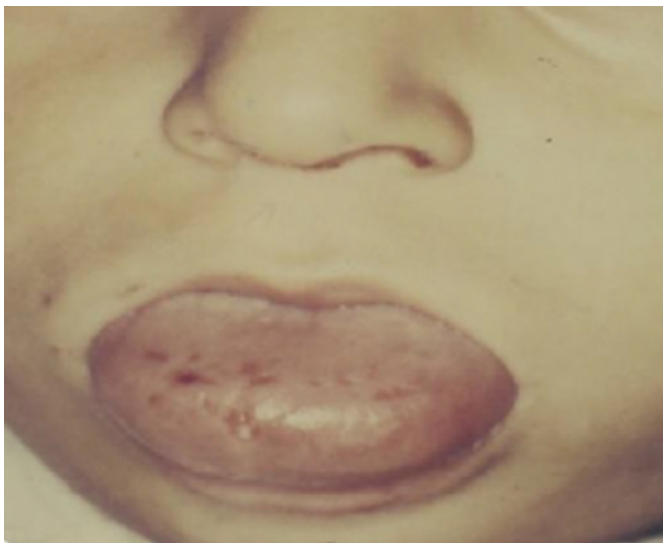Case presentation:

A four years child boy has been referred to our centre in Baqiet Ullah University Hospital ,Tehran, suffering from enlarged dry tongue, which was causing a difficulty in breathing, speech, swallowing, and chewing .His parent were very concern about his case. As the parent stated that the tongue increased gradually.

After careful examination clinically, there was enlarged tongue with dry anterior part. Because of the long term prolapsed tongue, placed between the upper and lower anterior teeth caused delayed growing of the jaws with anterior open bite. Fig 3, 4, 5

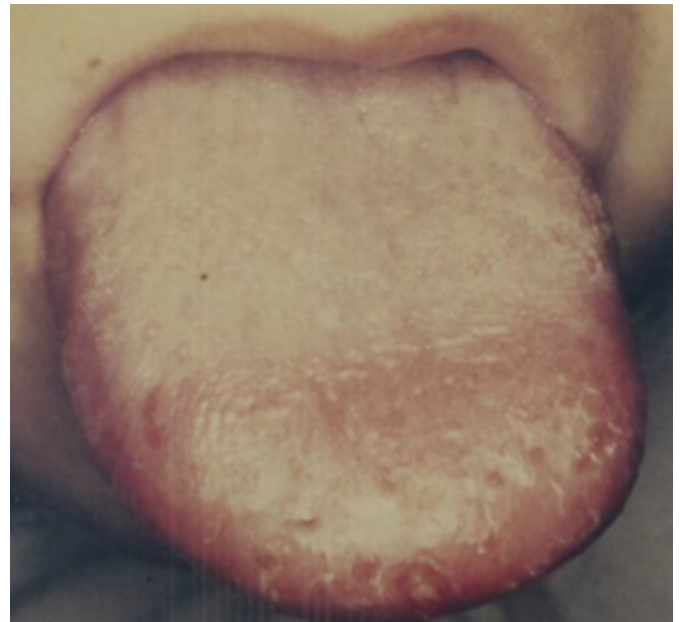**Figure 2**

Figure 3: Tongue in rest position, see the dry tip



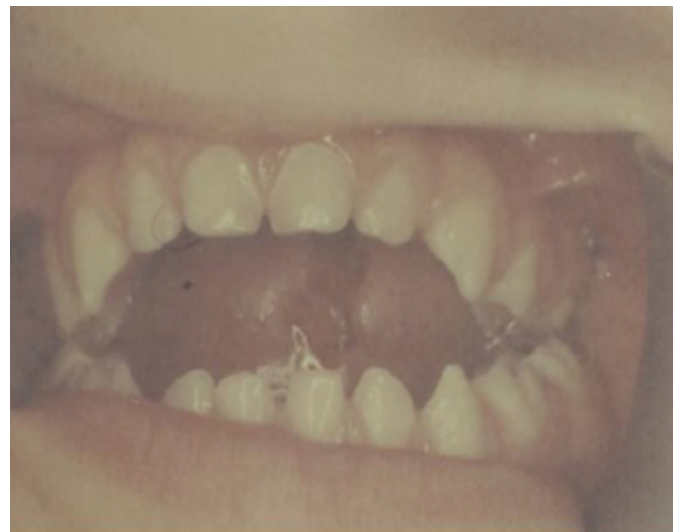**Figure 3**

Figure 4: protruded tongue



**Figure 4**

Figure 5: Anterior open bite



All relevant investigation were normal ,radiographic show the facial skeleton discrepancy .After long discussion with the parent about the child condition, a surgical correction option has been given to the parent.

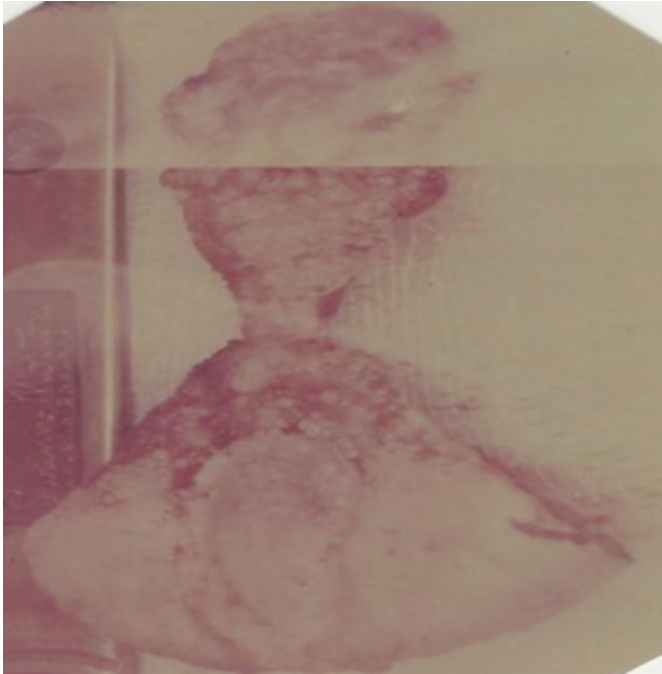
Under general anesthesia with tracheotomy intubation a partial glossectomy has been done and sutured in three layers with T-shape closure.

Post operative steroid and antibiotics was given, patient was recovered without any complications, A histopathological studies confirmed lymphoedema of the tongue .

The operation site has been healed without any complications; Figs 6-13

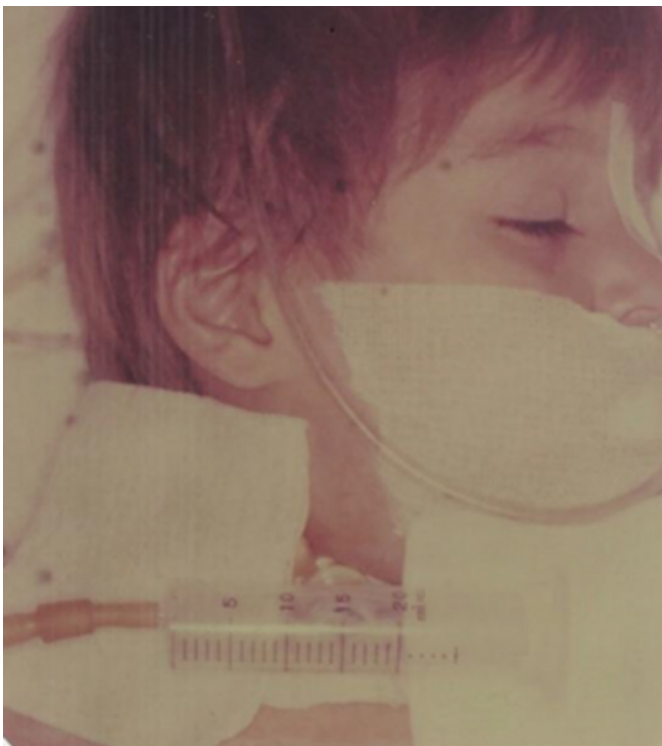### Figure 5

Figure 6: Excised sample



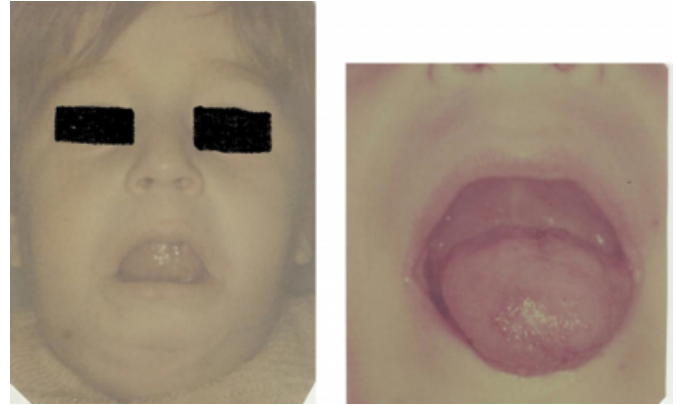### Figure 6

Figure 7: post operative view



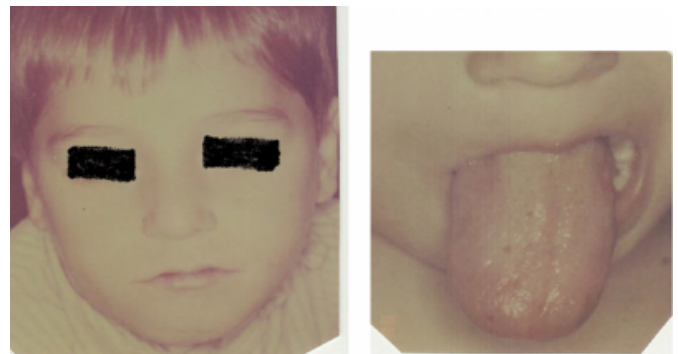### Figure 7

Figure 8 & 9: Two weeks post operative view



### Figure 8

Figure 12 & 13: One month post operative view



## DISCUSSION

Macroglossia is traditionally defined as a resting tongue that protrudes beyond the teeth or alveolar ridge. The diagnosis is usually based on this sign and comparison with an apparently normal tongue (objective measurements of size are unreliable). The term should be reserved for cases of long term painless enlargement of the tongue and is distinct from rapid growth of the tongue due to acute parenchymatous glossitis<sup>6</sup>

Maxillofacial abnormalities including anterior open bite, prognathism, and an increased angle between the ramus and body have been described. Noisy breathing, drooling, and the unsightly appearance of a protruberant tongue, particularly in children, can cause distress. Difficulties in swallowing due to limited movement of the enlarged tongue can lead to poor weight gain and failure to thrive. Problems with articulation occur, particularly the expression of consonants requiring the tip of the tongue to be in contact with the alveolar ridge or roof of the mouth. The most serious and life threatening complication is airway obstruction, which is more common in generalised or

posterior lingual enlargement than in anterior enlargement of the tongue.

The evaluation of a patient with macroglossia should begin with a thorough history and physical examination, which may allow the recognition of a syndrome of which the enlarged tongue is one component. Assessment of the tongue should include examination for masses and changes in colour and consistency, Thyroid function tests, isotopic imaging of the thyroid gland, chromosomal studies, and urinary mucopolysaccharide assay may be indicated. Patients with chronic airway obstruction should be assessed for pulmonary hypertension and cardiac decompensation with electrocardiography, chest radiography, arterial blood gas analysis, and Doppler echocardiography. Computed tomography and magnetic resonance imaging may be useful to delineate soft tissues and to show the extent of tumours and other masses. Microscopic examination of tongue tissue in primary macroglossia may be unhelpful, but biopsy is useful for localized lesions of the tongue that occur in chronic granulomatous and neoplastic disorders. Biopsy of other potentially affected tissue (rectum, skin, gums) is indicated to diagnose definitively amyloidosis. [67]

The successful management of macroglossia requires a multidisciplinary approach. Medical management may be sufficient if the enlargement of the tongue is due to systemic disease, but surgical reduction offers the best functional and cosmetic results and minimises morbidity. Airway obstruction demands prompt intervention; tracheostomy is occasionally necessary. Surgery is indicated in almost all cases of secondary macroglossia, when the tongue is affected with neoplastic disease. In primary macroglossia in infants, prevention of speech and orthodontic problems may require surgical reduction of the tongue at an early stage, preferably before 7 months of age. Early management helps rehabilitation and reduces the risk of permanent maxillofacial abnormalities and abnormalities of speech. [78]

Conservative methods of treating macroglossia are of limited value. Thyroxine in cases of hypothyroidism and bromocriptine in cases of acromegaly have obvious

therapeutic benefits. Corticosteroids can be life saving in acute airway obstruction and are useful postoperatively to reduce oedema. [2581214]

Surgical result have been good. Successful treatment require appropriate rehabilitation and long term follow up.

### **References**

1. Brodeur GM. Genetic and cytogenetic aspects of Wilms" tumor. In: Pochedly C, Baum ES (eds.): Wilms" Tumor: Clinical and Biological Manifestations. New York, Elsevier, 1984; 125-45.
2. Byrne PJ, Bernstein PE: The use of medicinal leeches to treat macroglossia secondary to blunt trauma. *Otolaryngol Head Neck Surg* 2001 Dec; 125(6): 649-50
3. Gadban H, Gilbey P, Talmon Y: Acute edema of the tongue: a life-threatening condition. *Ann Otol Rhinol Laryngol* 2003 Jul; 112(7): 651-3
4. Harada K, Enomoto S: A new method of tongue reduction for macroglossia. *J Oral Maxillofac Surg* 1995 Jan; 53(1): 91-2
5. Jian XC: Surgical management of lymphangiomatous or lymphangiohemangiomatous macroglossia. *J Oral Maxillofac Surg* 2005 Jan; 63(1): 15-9
6. Mixter RC, Ewanowski SJ, Carson LV: Central tongue reduction for macroglossia. *Plast Reconstr Surg* 1993 May; 91(6): 1159-62
7. Moura CG, Moura TG, Durlifes AR: Exuberant macroglossia in a patient with primary systemic amyloidosis. *Clin Exp Rheumatol* 2005 May-Jun; 23(3): 428
8. Moura CG, Moura TG, Durlifes AR: Exuberant macroglossia in a patient with primary systemic amyloidosis. *Clin Exp Rheumatol* 2005 May-Jun; 23(3): 428
9. Ring ME: The treatment of macroglossia before the 20th century. *Am J Otolaryngol* 1999 Jan-Feb; 20(1): 28-36
10. Rizer FM, Schechter GL, Richardson MA: Macroglossia: etiologic considerations and management techniques. *Int J Pediatr Otorhinolaryngol* 1985 Mar; 8(3): 225-36
11. Severtson M, Petruzzelli GJ: Macroglossia. *Otolaryngol Head Neck Surg* 1996 Mar; 114(3): 501-2
12. Siddiqui A, Pensler JM: The efficacy of tongue resection in treatment of symptomatic macroglossia in the child. *Ann Plast Surg* 1990 Jul; 25(1): 14-7
13. Tei E, Yamataka A, Komuro Y: Huge lymphangioma of the tongue: a case report. *Asian J Surg* 2003 Oct; 26(4): 228-30
14. Ueyama Y, Mano T, Nishiyama A, et al: Effects of surgical reduction of the tongue. *Br J Oral Maxillofac Surg* 1999 Dec; 37(6): 490-5
15. Wang J, Goodger NM, Pogrel MA: The role of tongue reduction. *Oral Surg Oral Med Oral Pathol Oral Radiol Endod* 2003 Mar; 95(3): 269-73
16. Wolford LM, Cottrell DA: Diagnosis of macroglossia and indications for reduction glossectomy. *Am J Orthod Dentofacial Orthop* 1996 Aug; 110(2): 170-7

**Author Information**

**Abbas Taher, BDS, DDS. DOMFS, LDSRCPS, MSc, FACOMS,FICS**  
OMF Surgeon in Private Practice