

Oral Chronic Graft Versus Host Disease With Non-Gingival Soft Tissue Growths: A Treatment Challenge

E Parisi, T Sollecito

Citation

E Parisi, T Sollecito. *Oral Chronic Graft Versus Host Disease With Non-Gingival Soft Tissue Growths: A Treatment Challenge*. The Internet Journal of Dermatology. 2002 Volume 2 Number 1.

Abstract

Patients that have an allogeneic hematopoietic cell transplant are susceptible to developing chronic graft versus host disease (cGvHD). Often the oral mucosal is significantly altered due to this process. Occasionally, non-gingival soft tissue growths (NGSTG) also complicate the clinical presentation. We describe a patient that had oral cGvHD and NGSTG and discuss the challenges to treatment.

INTRODUCTION

The immunologic mechanism of chronic graft-versus-host disease (cGvHD) has not been fully understood, although the process resembles naturally occurring autoimmune disease. Manifestations of cGvHD may have a vast array of clinical presentations in various organ systems that may include skin, liver, gastrointestinal tract, or lungs. Recipients of allogeneic hematopoietic cell transplant (HCT) often develop cGvHD approximately three months after transplantation. Although most develop some cutaneous symptoms, over 90% of these patients may have mucosal involvement. Among the oral clinical features are mucosal atrophy, erythema, ulcerations, lichenoid lesions, and xerostomia [1]. Additionally, non-gingival soft tissue growths (NGSTGs) have been reported in allogeneic HCT patients who have cGvHD and are receiving cyclosporin (CSA) [2,3]. We describe the case of a 38 year-old male with oral cGvHD and NGSTG and discuss the challenges to treatment.

CASE REPORT

Our patient is a 38 year-old Caucasian male with a past medical history of aplastic anemia treated in November 1999 with a human leukocyte antigen (HLA) matched allogeneic HCT from his sister. Approximately four months after the transplant, he developed symptoms of oral cGvHD that gradually worsened over several weeks. His medications at the time of his presentation included Prednisone, mycophenolate mofetil, Dapsone, CSA, Nifedipine, Acyclovir and fluconazole. Other than oral pain while eating, and xerostomia, his review of symptoms was

unremarkable. On physical exam, he was noted to have a cushingoid facial appearance and a mild papular rash on his skin. Intraorally his buccal mucosa was noted to have a lichenoid appearance, with areas of erythema and white hyperkeratotic striations [Figure 1]. He also had three exophytic masses in the buccal mucosa along the occlusal plane which were larger than 1cm³ [Figure 2]. The dorsal tongue also had a pseudomembranized ulceration and a smaller soft tissue mass [Figure 3].

Figure 1

Figure 1: Lichenoid appearance of buccal mucosa.

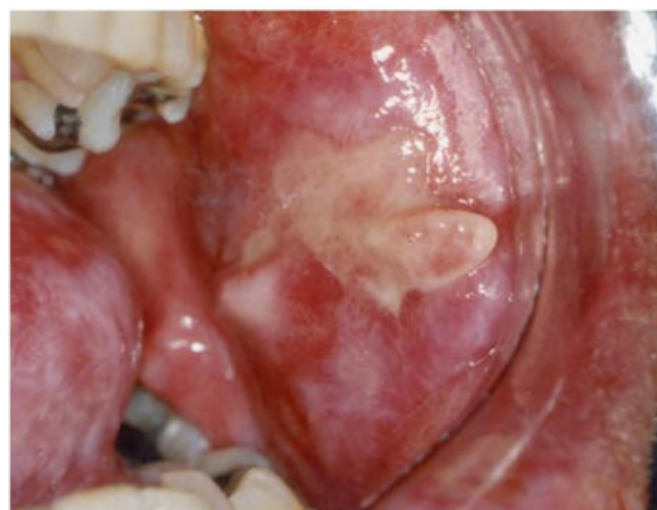

Figure 2

Figure 2: Exophytic masses of the buccal mucosa. Non-gingival soft tissue growth

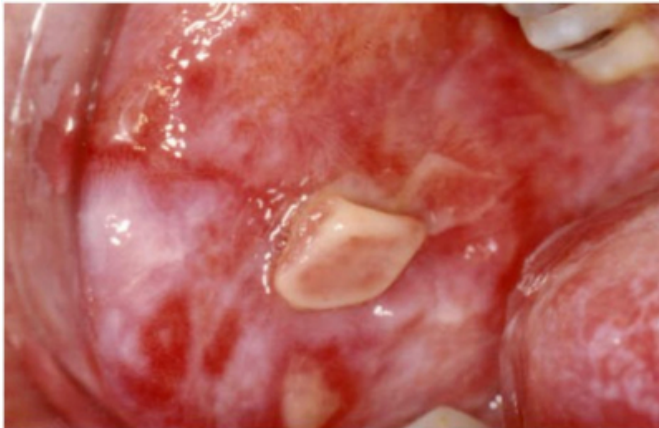
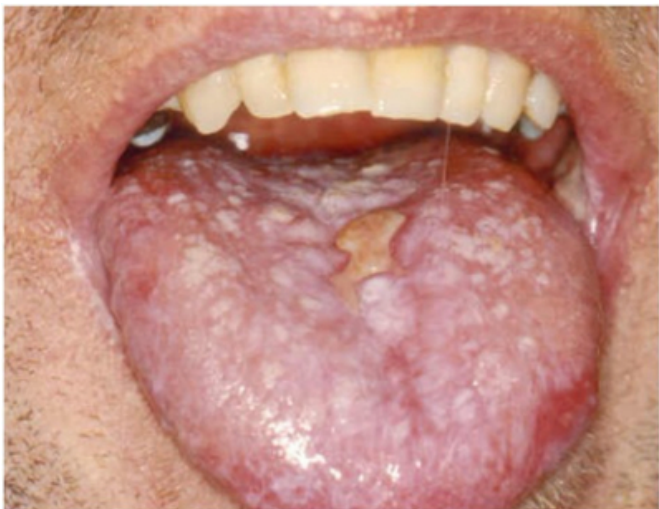

Figure 3

Figure 3: Ulceration and soft tissue mass on tongue.



An incisional biopsy of the buccal mucosa revealed an infiltrate of mixed chronic inflammatory cells, mostly lymphocytes and histiocytes within the connective tissue. There were no features of malignancy, however saw-tooth rete pegs and migration of lymphocytes into the epithelium was observed. These histologic findings were consistent with cGvHD. Biopsies of the three exophytic masses demonstrated exuberant reactive granulation tissue interspersed by distended capillaries and fibroblasts. There was a moderately intense inflammatory cell infiltration present, and the surfaces were partially ulcerated and covered by a fibrinous exudate. Our clinical assessment based on the histopathologic findings was chronic oral GvHD and NGSTGs.

Topical ultra-high potency and intralesional steroids were

used for approximately 12 weeks with minimal improvement. A decision was made to try topical tacrolimus 0.1% for 8 weeks, in an off-label trial. This resulted in a minimal (less than 10%) overall clinical improvement. The primary hematology-oncology service was reluctant to increase the doses of Prednisone and CSA since the patient had no other signs or symptoms of systemic cGvHD and there was strong evidence of drug induced adverse reactions. It was agreed to continue topical therapeutics. However, over a period of several months, topical tacrolimus, topical corticosteroids, and intralesional steroid injections were minimally successful in treating oral cGvHD and unsuccessful in treating the NGSTGs. The remainder of the NGSTGs were excised. Despite the significant advances in the understanding of this disease, the management of chronic oral GvHD still remains a treatment challenge.

DISCUSSION

To our current knowledge, cGvHD is thought to be mediated by autoreactive T-cells directed against cells expressing HLA Class II antigens, causing a spectrum of clinical manifestations affecting the skin, mucous membranes, GI tract, and various other organ systems, particularly the liver. The disease may be precipitated by trauma, ultraviolet light, or infections such as Herpes Simplex Virus (HSV) [4]. The effected oral cavity can serve as a direct portal of entry for many potential pathogens. The health of the oral cavity is of paramount importance for proper nutrition. Therefore treatment of oral cGvHD is warranted.

Many treatment modalities have been reported in the literature. Traditional systemic therapy includes systemic steroids and CSA, used separately or combination depending on the severity of the disease. Adjunctive systemic immunosuppressives include cyclophosphamide, mycophenolate mofetil, azathioprine, thalidomide, and methotrexate. Topical steroids are often prescribed and are occasionally useful for oral cGvHD. Clinical investigators have explored other alternatives including ultraviolet radiation with psoralen therapy[5,6], topical CSA[7], and topical azathioprine[8,9]; however, all of these modalities have been used with limited success. Topical tacrolimus has also been used in treatment of cutaneous cGvHD,[10] but to our knowledge not for oral cGvHD. In our case, this mode of therapy provided only minimal improvement.

Although there is a significant amount of research on the treatment of oral cGvHD, to date, there have been no reports discussing effective medical management of NGSTGs.

There are well-documented cases of reactive proliferations of fibrous and granulation tissue in bone marrow allograft recipients, also cited as oral 'pyogenic granulomas' [2, 3, 11, 12]. Although some of these patients had some systemic form of cGvHD such as gastrointestinal or organ involvement, all had oral cGvHD and were being treated with CSA.

Interestingly, in these case reports, the authors emphasized the absence of gingival overgrowth, which has frequently been associated with CSA use. In gingival overgrowth, the fibrovascular proliferation and increased extracellular matrix components thought to be caused by CSA, may possibly be mediated by the cytokines produced by other cells that are affected by CSA.

The process of chronic tissue injury developing into fibrous or granulation tissue has been established. It is thought that these NGSTGs may develop from chronic mucosal inflammation or trauma, while CSA may play a role in triggering an increased proliferative response of the connective tissue resulting in these soft tissue masses [2]. In this case, the NGSTGs recurred several weeks after excision, while the patient was maintained on steady doses CSA and prednisone therapy. In addition, the NGSTGs were refractory to treatment with intralesional corticosteroid injections, topical steroids, or topical tacrolimus. This may be related to the continuous fibroproliferative response associated with the use of CSA.

CONCLUSION

In summary, this report of NGSTGs in a patient with chronic oral GvHD demonstrates some of the difficulties in treatment of these conditions. Since the role of CSA in the development of intraoral soft tissue masses has been proposed in multiple cases, it would be of interest to evaluate the prevalence of soft tissue masses and lesions in patients who have received allogeneic HCT and are not being treated with CSA. As newer therapies are being integrated into immunosuppressive regimens, it will be interesting to observe the oral sequelae of these newer immunoselective medications.

CORRESPONDENCE TO

T. Sollecito, DMD University of Pennsylvania Dental School Department of Oral Medicine Suite 250 240 S 40th St Philadelphia, PA 19104 Tele: 215-898-6627 Fax: 215-573-7853 Email: tps@pobox.upenn.edu

References

1. Schubert MM, Sullivan KM. Recognition, incidence, and management of oral graft-versus-host disease. NCI Monographs 1990; 9:135-143.
2. Woo SB, Allen CM, Orden A, Porter D, Antin JH. Non-gingival soft tissue growths after allogeneic marrow transplantation. Bone Marrow Transpl 1996; 17(6):1127-1132.
3. Barnadas MA, Brunet S, Sureda A, Lopez R, Curell R, Sierra J, Alomar A. Exuberant granulation tissue associated with chronic graft-versus-host disease after transplantation of peripheral blood progenitor cells. J Am Acad Dermatol 1999; 41(5):876-879.
4. Aractingi S, Chosidow O. Cutaneous graft-versus-host disease. Arch Dermatol 1998; 134(5):602-612.
5. Redding SW, Callander NS, Haveman CW, Leonard DL. Treatment of oral chronic graft-versus-host disease with PUVA therapy: Case report and literature review. Oral Surg Oral Med Oral Pathol Oral Radiol Endod 1998; 86(2):183-187.
6. Elad S, Garfunkel AA, Enk CD, Galili D, Or R. Ultraviolet therapeutic concept for the management of oral manifestations of graft-versus-host disease. Oral Surg Oral Med Oral Pathol Oral Radiol Endod 1999; 88(4):444-450.
7. Epstein JB, Truelove EL. Topical cyclosporine in a bioadhesive for treatment of oral lichenoid mucosal reactions: An open label clinical trial. Oral Surg Oral Med Oral Pathol Oral Radiol Endod 1996; 82(5):532-536.
8. Epstein JB, Gorsky M, Epstein MS, Nantel S. Topical azathioprine in the treatment of immune-mediated chronic oral inflammatory conditions: A series of cases. Oral Surg Oral Med Oral Pathol Oral Radiol Endod 2001; 91(1):56-61.
9. Epstein JB, Nantel S, Sheoltch SM. Topical azathioprine in the combined treatment of chronic oral graft-versus-host disease. Bone Marrow Transpl 2000; 25(6):683-687.
10. Choi CJ, Nghiem P. Tacrolimus Ointment in the Treatment of Chronic Cutaneous Graft-vs-Host Disease: A Case Series of 18 Patients. Arch Dermatol 2001; 137(9):1202-1206.
11. Lee L, Miller PA, Maxymiw WG, Messner HA, Rotstein LE. Intraoral pyogenic granuloma after allogeneic bone marrow transplant: Report of three cases. Oral Surg Oral Med Oral Pathol 1994; 78(5):607-610.
12. Wandera A, Walker PO. Bilateral pyogenic granuloma of the tongue in graft-versus-host disease: Report of a case. J Dent Child 1994; 61(5-6):401-403.

Author Information

Ernesta Parisi, DMD

Assistant Professor of Oral Medicine, Department of Diagnostic Sciences, University of Medicine and Dentistry of New Jersey

Thomas P. Sollecito, DMD

Associate Professor Oral Medicine, School of Dental Medicine, University of Pennsylvania