

Current intervention strategies for Cerebral Venous Sinus Thrombosis

A des Etages, H Wee Chan

Citation

A des Etages, H Wee Chan. *Current intervention strategies for Cerebral Venous Sinus Thrombosis*. The Internet Journal of Neurosurgery. 2006 Volume 4 Number 2.

Abstract

Intravenous heparin infusion has been the mainstay of treatment for cerebral venous sinus thrombosis (CVST). Surgical and neuroradiological treatment was once an uncommon occurrence. Recent trends, however, have been to employ endovascular or surgical intervention strategies in carefully selected cases and the combined use of these modalities is on the rise. These strategies include endovascular thrombolysis, mechanical thrombectomy to remove the clot and operative neurosurgery to treat raised intracranial pressure. We review the literature and present an update on current treatment strategies.

INTRODUCTION

Cerebral venous sinus thrombosis is a pathological condition resulting in thrombosis of the dural venous sinuses, deep cerebral veins and cortical veins. Because of delays in presentation and the fact that it can mimic many other neurological illnesses, the exact incidence remains obscure. It is estimated that it occurs in 0.6/100,000 neonates¹, 4% of children and in 0.22 per 100,000 adults. It affects all ages and sexes and there is a strong preponderance in women of childbearing age. Outcome from this disease is highly variable but mortality rates appear to be falling as most recent reports quote a less than 10% mortality rate². Death is most often due to transtentorial herniation from cerebral edema or haemorrhagic stroke³. It recurs after treatment in under 10% of cases⁴ and appears at least in one study, to have a similar recurrence rate to lower limb deep vein thrombosis, but a lower mortality rate⁵. There are poor prognostic indicators that include, status epilepticus, intracranial haemorrhage, cortical vein thrombosis, coma⁶, thrombosis of the deep venous system, extremes of age⁷, cerebellar venous thrombosis, severely increased intracranial pressure and underlying sepsis or malignancy. Treatment strategies are aimed at treating the underlying pathology, controlling intracranial pressure and treatment of seizures or focal deficits caused by cerebral edema or infarction. Anticoagulation is used almost universally and in selected cases, endovascular and surgical techniques have been employed to remove the clot. Surgical techniques are further used to treat the sequelae of CVST, including hydrocephalus, raised intracranial pressure, visual failure

and haemorrhagic stroke.

INTRAVENOUS HEPARIN

Since 1941⁸, heparin has been used to treat CVST. There have been two randomised controlled trials to date, one using unfractionated and the other low molecular weight heparin^{9;10}. Only one (Einhaupl et al), has shown statistically significant improvement in outcome three months after administration, provided that treatment has been started 7 days or as early as possible following symptoms. Cipri performed a retrospective review of seven cases treated by intravenous heparin and fibrinolytic therapy that demonstrated no recanalisation of the thrombus despite clinical improvement¹¹. Other authors report resolution of clot on follow-up MRI scan¹², reflecting a possible need to standardise the timing of follow up investigation. Nagajara et al, reported reduced morbidity and mortality of low dose heparin in 56 cases puerperal CVST¹³. Systemic heparin carries a risk of intraparenchymal haemorrhage, however despite this risk, several studies showed a good risk benefit ratio, lower mortality¹⁴, and there are authors that recommend its use¹⁵. Heparin appears to work not only by preventing further clot formation, but in a CD-1 mouse model appeared to reduce the permeability of the blood brain barrier in the region of the clot as well¹⁶. Systemic thrombolysis using streptokinase, urokinase or rTPA have been used but these agents carry a significant risk of bleeding in patients with systemic disorders such as inflammatory bowel disease, recent childbirth, trauma and bleeding diathesis. As such local delivery of thrombolytic

agents carries the attractive prospect of minimising catastrophic complications whilst maximising therapeutic response.

ENDOVASCULAR STRATEGIES

Li et al in 1998 studied 12 cases of multiple thrombosis in CVST, treated with oral anticoagulation with warfarin and intermittent injection of urokinase via the common carotid artery. They found that 11 out of the 12 cases had a reduction in intracranial pressure and markedly improved neurological deficit in 10 days¹⁷. This same group in 2002 performed another study using stent angioplasty and instead of intermittent injection via the common carotid, a microcatheter was used to deliver urokinase 1.5 MU directly into the sinus. This was followed by oral warfarin for a duration of five days¹⁸. The results were that approximately 50% of the patients relapsed to a different degree after 7 days and 50% showed a reduction in the intracranial pressure. All patients showed no evidence of relapse at 3 and 6 monthly follow-up. These two papers performed by the same group seem to indicate that whilst oral anticoagulation combined with local administration of thrombolytic agents is effective, stent angioplasty seemed to have conferred, at least in the short term, no additional benefit.

Chow et al., in 2000 adopted the strategy of combining the AngioJet rheolytic mechanical thrombectomy with intra-arterial thrombolysis. In two patients, one of whom had an intracerebral haemorrhage, the mechanical thrombectomy was performed on the dural venous sinuses (sagittal and transverse sinuses) and intra-arterial thrombolysis was performed for the cortical venous thrombosis¹⁹. This strategy resulted in a significantly lower doses of urokinase (400,000IU delivers locally as 100,000 IU aliquots over four hours) as compared to the 1.5 MU doses used by Li et al's group. At six month follow-up the only deficit was mild short-term memory loss in one patient. Though this is too small a sample to generalise, it would seem that this is a useful strategy to reduce the risk of a haemorrhagic complication.

One author has described the use of coronary microballoon percutaneous transluminal angioplasty catheters for mechanical thrombectomy²⁰. This was performed in a single case of sagittal sinus and transverse-sigmoid sinus thrombosis that had a poor response to superselective chemical thrombolysis. The disadvantage with this procedure was that more than one catheter had to be used as increasingly larger calibre catheters were used to determine

the ideal size for removal of the thrombus. This of course incurs increased cost and highlights the limitations of cerebral venous angiography in determining the diameter of the thrombosed venous system.

In a single centre study²¹ involving six patients, aged 14 to 75 yrs old with varying co-morbidity, including inflammatory bowel disease, nephritic syndrome, cancer, peuperium and the use of oral contraceptive pills; mechanical microsnare wire maceration of thrombus was performed in two patients who failed selective chemical thrombolysis. The remainder of this group responded to selective delivery of urokinase at dosages varying from 200,000 IU to 1MU. Their results remarkably indicated that despite poor prognostic indicators being present, there was no statistically significant difference in the outcome. This seems to suggest, that with careful selection, endovascular strategies negate the traditional poor prognostic indicators.

In conclusion, the endovascular strategies involve superselective delivery of Thrombolytic agents via several routes including transfemoral, transjugular, transcarotid or directly through the venous sinus. This is supplemented by mechanical thrombectomy or used in combination with it. Intravenous anticoagulation followed by oral anticoagulation is used in all cases.

OPERATIVE NEUROSURGICAL STRATEGIES

Surgical intervention for CVST is directed mainly at controlling raised intracranial pressure. To this end insertion of ventriculoperitoneal shunts²² and emergency decompressive craniectomy have been advocated by some authors²³. Review of these reports revealed that decompression was performed after failed medical management of the raised intracranial pressure²⁴ or where there was clear reduction in consciousness from progressive raised intracranial pressure, rather than worsened symptoms in an alert patient.. It was unclear whether these patients were observed clinically or whether intracranial pressure monitors were used²⁵. Ventriculoperitoneal shunt was performed for intractable headache or progressive deterioration in vision. Lumboperitoneal shunting has also been advocated, but this was in a Protein S deficient patient with deteriorating vision remote from his acute presentation²⁶. The more novel use of surgery involved direct surgery on the dural sinus to remove thrombus.

Direct mechanical thrombectomy via a burr hole over a dural venous sinus employing the use of a rheolytic catheter has been reported²⁷. The patients selected had rapidly

deteriorating levels of consciousness who failed transfemoral attempt at thrombectomy. Use of rheolytic catheters has been reported by both Scarrow et al. and Opatowsky et al in 1999^{28,29}. Baker et al presented their series of 5 cases demonstrating good results³⁰. They point out that the often late presentation of these patients may be a contributory factor to the failure of thrombolytic therapy and advocate early mechanical techniques in patients who present late with deteriorating levels of consciousness. The current indications for use seem to be in the patient with a malignant clinical course and persistent neurological deterioration despite adequate anticoagulation in the presence of parenchymal haemorrhage³¹.

EFNS GUIDELINES

The European Federation of Neurological Societies has recently released guidelines on the treatment of cerebral venous sinus thrombosis³². In this guideline, Einhaupl et al performed an excellent literature review and reached the following conclusions:

- 1) Body weight adjusted low molecular weight heparin in patients without contraindication to anticoagulation, carries a lower risk of complications, is not contra-indicated in the face of intracerebral haematoma. There is no evidence that it is equally effective in treating CVST.
- 2) The use of thrombolytic therapy whether local or symptomatic lacks a clear evidence base. They recommend however attempting its use in carefully selected cases that fail anticoagulation.
- 3) Whilst evidence is lacking, they recommend oral anticoagulation for 3 months in cases without thrombophilic risk factor and 6 to 12 months for those with.
- 4) Anticonvulsants should be prescribed for patients with a seizure presentation, or prophylactically if a focal parenchymal lesion exists on neuroimaging. No recommendations are made on the duration of anticonvulsant therapy.
- 5) Patients who present with pending visual failure should have a lumbar puncture to normalise their ICP prior to anticoagulation. Optic nerve fenestration, acetazolamide and lumboperitoneal shunting should be considered.
- 6) Raised intracranial pressure should be managed according to severity, with full medical management including intubation, sedation, hyperventilation, paralysis and osmotic diuresis.

- 7) Decompressive craniectomy may be performed in cases of unilateral large haemorrhagic infarct, without preferably any resection of the haemorrhagic infarct.

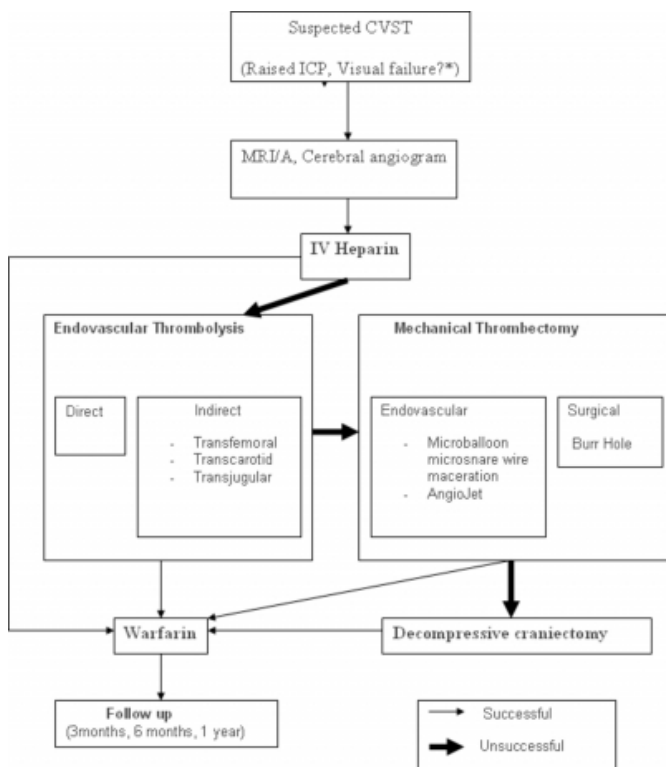
Whilst these points provide a good scaffold for clinical practice and the authors do highlight consensus agreement as well as a lack of available evidence, there are clinical scenarios which the guidelines fail to address. For example, it fails to mention the potential role of mechanical thrombectomy, which has despite the small clinical series, shown some efficacy in selected cases³³. The use of thiopentone has not been addressed. Whilst it can be used to help control raised intracranial pressure, it can however induce hypotension and worsen an infarct. Cooling, an often adopted strategy for ICP control, can result in an anticoagulable state, necessitating dose adjustment of anticoagulation. External ventricular drainage has also not been mentioned as part of the armamentarium and should be investigated. It also seems readily obvious that some patients may deteriorate in vision or consciousness despite initial improvement and may need to have any of the aforementioned surgical strategies whilst on anticoagulation. The burning question remains; is it safe to interrupt the anticoagulation and when is it safe to restart anticoagulation after operative intervention? These issues are not mentioned in the guidelines. Further investigation is therefore needed for effective and safe practice.

AN ALGORITHM

Although there is no clear evidence, the reported case series in the literature appear to follow a clear algorithm which we have demonstrated below (Fig 1.).

Figure 1

Figure 1: Algorithm for treatment of Cerebral Venous Sinus Thrombosis



* Consider medical management of ICP, LP, VP shunt, LP shunt or decompressive craniectomy as situation dictates, at any stage of algorithm.

There is a clear lack of evidence base for the algorithm above, but it does represent a distillation of current practice as determined by literature review. As further study is done on the aforementioned techniques, it is assumed that this algorithm may be refined further to a state where simple safe and effective practice with clear indications, risks and outcomes may be appreciated.

CONCLUSION

The current intervention strategies for cerebral venous sinus thrombosis involve multimodality treatment using anticoagulation, thrombolysis by different routes, mechanical thrombectomy and surgical treatments for raised intracranial pressure and clot removal. The evidence base for this approach is slowly being built up as awareness of these techniques increase. Although conflicting opinions exist over safety and outcomes, the future looks optimistic for the treatment of this disorder. Further study is needed before evidence based treatment recommendations can be made.

References

1. Ibrahim SH. Cerebral venous sinus thrombosis in neonates. *J Pak Med Assoc* 2006; 56(11):535-537.
2. Schwarz S, Daffertshofer M, Schwarz T, Georgiadis D, Baumgartner RW, Hennerici M et al. [Current controversies in the diagnosis and management of cerebral venous and dural sinus thrombosis]. *Nervenarzt* 2003; 74(8):639-653.
3. Canhao P, Ferro JM, Lindgren AG, Boussier MG, Stam J, Barinagarrementeria F. Causes and predictors of death in cerebral venous thrombosis. *Stroke* 2005; 36(8):1720-1725.
4. Masuhr F, Mehraein S, Einhaupl K. Cerebral venous and sinus thrombosis. *J Neurol* 2004; 251(1):11-23.
5. Gosk-Bierska I, Wysokinski W, Brown RD, Jr., Karnicki K, Grill D, Wiste H et al. Cerebral venous sinus thrombosis: Incidence of venous thrombosis recurrence and survival. *Neurology* 2006; 67(5):814-819.
6. Masuhr F, Busch M, Amberger N, Ortwein H, Weih M, Neumann K et al. Risk and predictors of early epileptic seizures in acute cerebral venous and sinus thrombosis. *Eur J Neurol* 2006; 13(8):852-856.
7. Girot M, Ferro JM, Canhao P, Stam J, Boussier MG, Barinagarrementeria F et al. Predictors of outcome in patients with cerebral venous thrombosis and intracerebral hemorrhage. *Stroke* 2007; 38(2):337-342.
8. Benamer HT, Bone I. Cerebral venous thrombosis: anticoagulants or thrombolytic therapy? *J Neurol Neurosurg Psychiatry* 2000; 69(4):427-430.
9. Einhaupl KM, Villringer A, Meister W, Mehraein S, Garner C, Pellkofer M et al. Heparin treatment in sinus venous thrombosis. *Lancet* 1991; 338(8767):597-600.
10. de Bruijn SF, Stam J. Randomized, placebo-controlled trial of anticoagulant treatment with low-molecular-weight heparin for cerebral sinus thrombosis. *Stroke* 1999; 30(3):484-488.
11. Cipri S, Gangemi A, Campolo C, Cafarelli F, Gambardella G. High-dose heparin plus warfarin administration in non-traumatic dural sinuses thrombosis. A clinical and neuroradiological study. *J Neurosurg Sci* 1998; 42(1):23-32.
12. Lee MK, Kim JH, Kang HR, Rho HJ, Nam EJ, Kim SW et al. Systemic lupus erythematosus complicated with cerebral venous sinus thrombosis : a report of two cases. *J Korean Med Sci* 2001; 16(3):351-354.
13. Nagaraja D, Taly AB, Haridas VT, Veerendrakumar M, Subbakrishna DK. Heparin in haemorrhagic infarction in cerebral venous sinus thrombosis. *J Assoc Physicians India* 1998; 46(8):706-707.
14. Nagaraja D, Taly AB, Haridas VT, Veerendrakumar M, Subbakrishna DK. Heparin in haemorrhagic infarction in cerebral venous sinus thrombosis. *J Assoc Physicians India* 1998; 46(8):706-707.
15. Allroggen H, Abbott RJ. Cerebral venous sinus thrombosis. *Postgrad Med J* 2000; 76(891):12-15.
16. Kim DE, Schellingerhout D, Jaffer FA, Weissleder R, Tung CH. Near-infrared fluorescent imaging of cerebral thrombi and blood-brain barrier disruption in a mouse model of cerebral venous sinus thrombosis. *J Cereb Blood Flow Metab* 2005; 25(2):226-233.
17. Li B, Zhang J, Yin L. [Diagnosis and endovascular treatment of multiple thrombosis in cerebral venous sinus]. *Zhonghua Yi Xue Za Zhi* 1998; 78(2):128-130.
18. Li B, Guo M, Li S, Wang M. [Endovascular thrombolysis and stent angioplasty for obliteration in cerebral venous sinuses]. *Zhonghua Wai Ke Za Zhi* 2002; 40(12):890-892.
19. Chow K, Gobin YP, Saver J, Kidwell C, Dong P, Vinuela F. Endovascular treatment of dural sinus thrombosis

- with rheolytic thrombectomy and intra-arterial thrombolysis. *Stroke* 2000; 31(6):1420-1425.
20. Chaloupka JC, Mangla S, Huddle DC. Use of mechanical thrombolysis via microballoon percutaneous transluminal angioplasty for the treatment of acute dural sinus thrombosis: case presentation and technical report. *Neurosurgery* 1999; 45(3):650-656.
21. Philips MF, Bagley LJ, Sinson GP, Raps EC, Galetta SL, Zager EL et al. Endovascular thrombolysis for symptomatic cerebral venous thrombosis. *J Neurosurg* 1999; 90(1):65-71.
22. Akbalik M, Duru F, Fisgin T, Tasdemir HA, Incesu L, Albayrak D et al. Cerebral thrombosis associated with heterozygous factor V Leiden mutation and high lipoprotein(a) level in a girl with factor XIII deficiency. *Blood Coagul Fibrinolysis* 2007; 18(4):371-374.
23. Stefini R, Latronico N, Cornali C, Rasulo F, Bollati A. Emergent decompressive craniectomy in patients with fixed dilated pupils due to cerebral venous and dural sinus thrombosis: report of three cases. *Neurosurgery* 1999; 45(3):626-629.
24. Enam SA. Role of surgery in cerebral venous sinus thrombosis. *J Pak Med Assoc* 2006; 56(11):543-547.
25. Barbat G, Dalla MG, Coletta R, Blasetti AG. Post-traumatic superior sagittal sinus thrombosis. Case report and analysis of the international literature. *Minerva Anesthesiol* 2003; 69(12):919-925.
26. Chen PY, Hu HH, Chang FC, Chern CM. Protein S deficiency associated with progressive loss of vision and intracranial venous sinus thrombosis. *J Chin Med Assoc* 2004; 67(10):521-526.
27. Chahlav A, Steinmetz MP, Masaryk TJ, Rasmussen PA. A transcranial approach for direct mechanical thrombectomy of dural sinus thrombosis. Report of two cases. *J Neurosurg* 2004; 101(2):347-351.
28. Scarrow AM, Williams RL, Jungreis CA, Yonas H, Scarrow MR. Removal of a thrombus from the sigmoid and transverse sinuses with a rheolytic thrombectomy catheter. *AJNR Am J Neuroradiol* 1999; 20(8):1467-1469.
29. Opatowsky MJ, Morris PP, Regan JD, Mewborne JD, Wilson JA. Rapid thrombectomy of superior sagittal sinus and transverse sinus thrombosis with a rheolytic catheter device. *AJNR Am J Neuroradiol* 1999; 20(3):414-417.
30. Baker MD, Opatowsky MJ, Wilson JA, Glazier SS, Morris PP. Rheolytic catheter and thrombolysis of dural venous sinus thrombosis: a case series. *Neurosurgery* 2001; 48(3):487-493.
31. Kirsch J, Rasmussen PA, Masaryk TJ, Perl J, Fiorella D. Adjunctive rheolytic thrombectomy for central venous sinus thrombosis: technical case report. *Neurosurgery* 2007; 60(3):E577-E578.
32. Einhaupl K, Boussier MG, de Bruijn SF, Ferro JM, Martinelli I, Masuhr F et al. EFNS guideline on the treatment of cerebral venous and sinus thrombosis. *Eur J Neurol* 2006; 13(6):553-559.
33. Chahlav A, Steinmetz MP, Masaryk TJ, Rasmussen PA. A transcranial approach for direct mechanical thrombectomy of dural sinus thrombosis. Report of two cases. *J Neurosurg* 2004; 101(2):347-351.

Author Information

Andre des Etages, MSc

Wessex Neurological centre, Southampton General Hospital

Huan Wee Chan, MRCS

Wessex Neurological centre, Southampton General Hospital