

Unilocular Splenic Hydatidosis In A Sheep

S Vural, H Keles, M Haligur

Citation

S Vural, H Keles, M Haligur. *Unilocular Splenic Hydatidosis In A Sheep*. The Internet Journal of Veterinary Medicine. 2004 Volume 2 Number 1.

Abstract

A pathomorphological definition of a hydatid cyst located on the facies diaphragmatica of the spleen in a 1.5 year old sheep provided from a slaughterhouse was performed in this study.

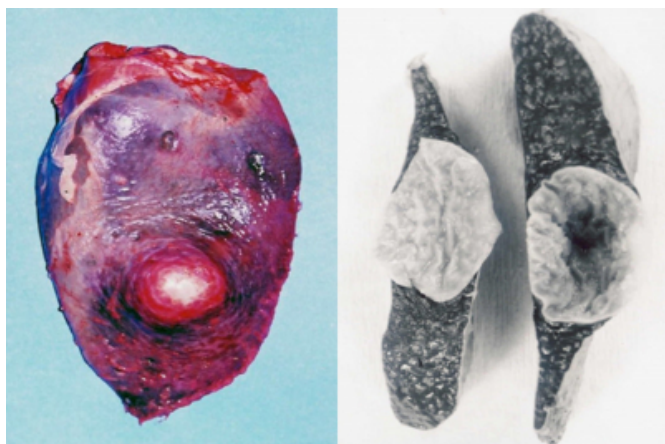
CASE REPORT

The spleen belonging to a 1.5 year old sheep revealed to have a hydatid cyst. The material was processed in accordance with routine histological procedures, fixed in 10% formalin solution and stained with Hematoxylin and Eosin (HE).

Macroscopical examination revealed the presence of a single cyst filled with clear fluid located in the center of the facies diaphragmatica of the spleen, detected to protrude from the surface and to measure 3.5x3.5x4 cm (Fig 1). The cyst was observed to be distinctively separated from surrounding tissue with a thin and light yellow colored wall. Upon drainage of the fluid, the inner surface of the cyst wall was observed to gain a folded appearance and to display numerous white colored granular structures (Fig 2).

Figure 1

Figures 1-2: Unilocular hydatid cyst and its cut section

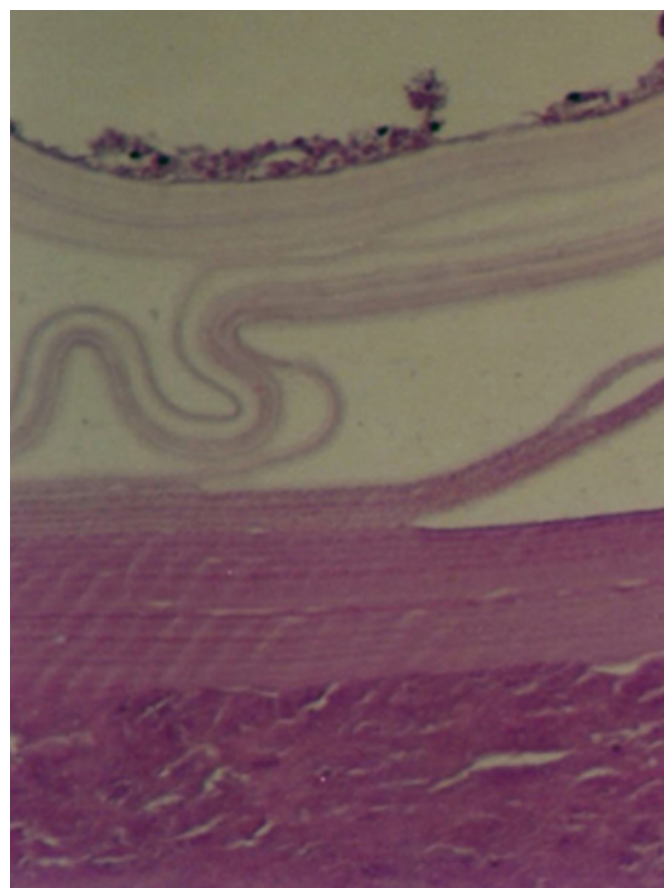


On the other hand, microscopical examination revealed two different appearances specific to the cyst and the host. The outer wall of the cyst was detected to be light pinkish in

color and to be formed of hyalinous cuticular membrane (Fig 3).

Figure 2

Figure 3: Hyalinous cuticular membrane and germinative membrane

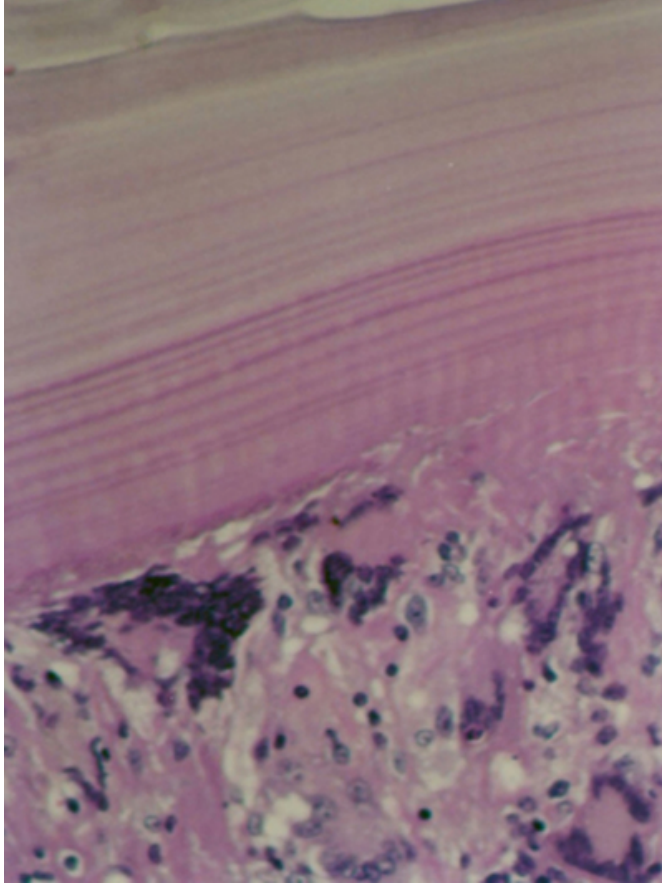


The germinative layer was assessed to exist below the outer wall. Necrotic material and many giant cells, surrounded by an outer layer comprised of macrophages, lymphocytes and a few numbers of epithelioid histiocytes were present at the

periphery of the cyst wall (Fig 4). The area in which the cyst was located was surrounded by a thin fibrous capsule from the external.

Figure 3

Figure 4: Giant cells at the periphery of cyst wall.



DISCUSSION

Hydatidosis (echinococcosis) caused by *Echinococcus granulosus* and *Echinococcus multilocularis* is a parasitic infection related closely both to human and animal health and known to cause economic loss.^{1,2} The adult parasite develops in carnivores whereas larvae develop in primarily sheep and cattle especially in omnivores, herbivore animals and humans.^{3,4,5,6} Hydatid cysts are encountered in cattle and sheep at rates of 7.8-50% and 3-11.4%, respectively.^{2,7} These cysts which may be one or more in number, contain a clear fluid and are most frequently located in the lungs and liver as well as other internal organs including the spleen, kidneys and brain.^{2,3,4,7,8,9,10} Cysts may be present in one or more of the above mentioned internal organs. In this reported case, the hydatid cyst was located in the spleen, an internal organ in which hydatidosis is less frequently observed. Macroscopical and microscopical findings of the cyst were determined to be in accordance with literature.

^{3,8,9,11} However, although some researchers^{12,13} have reported the thickness of the cyst capsule which develops due to fibrous host reaction to be dependent upon the severity of the reaction and the size of the cyst to be related to the features of the tissue the cyst is located in, we believe that such a generalization would be misleading for internal organs in which hydatidosis is less frequently observed, including the spleen.

ACKNOWLEDGEMENT

We would like to extend our gratitude to Veterinarian Mr. M. Akif Topcu for its assistance in the supply of the study material.

CORRESPONDENCE TO

Sevil ATALAY VURAL, Ass. Prof., Ankara University, Faculty of Veterinary Medicine, Department of Pathology, 06110-D??kap?-Ankara-Turkey Tel: (+90) 312 3170315 Fax: (+90) 312 3164472 e-mail: svural@veterinary.ankara.edu.tr

References

1. Tiğın, Y. Burgu, A. And Doğanay, A.: Hayvanlarda Ekinokok Türleri, 7. Ulusal Parazitoloji Kongresi, 22-25 Ekim, Ankara, 1991.
2. Zeybek, H. Tokay, A.: Ankara Yöresinde Evcil Ve Yabani Canidaeerde *Echinococcus* Türlerinin Yayılışı, Cyst Şekillerinin Ensidansı Ve Kontrol Olanakları Araştırılması. Etlik Vet Mikrob Derg 6(6): 1-19, 1990.
3. Güralp, N.: Helmintoloji. 2. Baskı, Ankara. üniv. Vet. Fak. Yayınları, Yay. No: 368, Ankara, 1981.
4. Jenkins, D.J. And Thompson, R.C.A.: Hydatid Cyst Development In An Experimentally Infected Wild Rabbit. Vet. Rec. 137: 148, 1995.
5. Singh, B.P. Dhar, D.N.: *Echinococcus Granulosus* In Animals In Northern India. Vet Parasitol 28: 261-266, 1988.
6. Walters, T.M.H.: Echinococcosis/Hydatidosis And The South Powys Control Scheme. J Small Anim Prac 27(10):693-703, 1986.
7. Arene, F.O.I. And Nweke, O.O.: The Epidemiology Of Echinococcus Infection In Niger Delta. Publ. Hlth. Lond. 99: 30-32, 1985.
8. Hüdaoğlu, H.: Kuzey Kıbrıs Türk Cumhuriyetinde Koyun Ve Keçilerdeki Kist Hidatidin İnsidensi Ve Patolojisi. A.ü. Sağlık Bilimleri Enstitüsü, Yüksek Lisans Tezi, Ankara, 1999.
9. Jubb, K.V.F. Kennedy, P.C. And Palmer, N.: Pathology Of Domestic Animals. 4 Th Ed., Academic Press Inc, San Diego, 1993.
10. Rossouw, G.J. Knott-Craig, C.J. And Erasmus, P.E.: Cardiac Echinococcosis: Cyst Removal In A Beating Heart. Ann. Thorac. Surg. 53: 328-329, 1992.
11. Jones, T.C. Hunt, R.D. And King, N.W.: Veterinary Pathology. 6 Th Ed., Williams & Wilkins, Philadelphia, 1997.
12. Soulsby, E.J.L.: Helminths, Arthropods And Protozoa Of Domesticated Animals. 7 Th Ed., Bailliere Tindall, London, 1982.
13. Toparlak, M. And Tüzer, E.: Veteriner Helmintoloji, İstanbul üniv Vet Fak. Yayınları, Yayın No: 30, İstanbul,

1995.

Author Information

Sevil Atalay Vural

Associate Professor, Department of Pathology, Faculty of Veterinary Medicine, Ankara University

Hikmet Keles

Doctor, Department of Pathology, Faculty of Veterinary Medicine, Afyon Kocatepe University

Mehmet Haligur

Doctor, Department of Pathology, Faculty of Veterinary Medicine, Akdeniz University