

Monocytic Acute Non-Lymphocytic Leukemia Presenting As A Malign-Appearing Cutaneous Eruption

A Yalcin, A Keskin, N Calli

Citation

A Yalcin, A Keskin, N Calli. *Monocytic Acute Non-Lymphocytic Leukemia Presenting As A Malign-Appearing Cutaneous Eruption*. The Internet Journal of Dermatology. 2003 Volume 2 Number 2.

Abstract

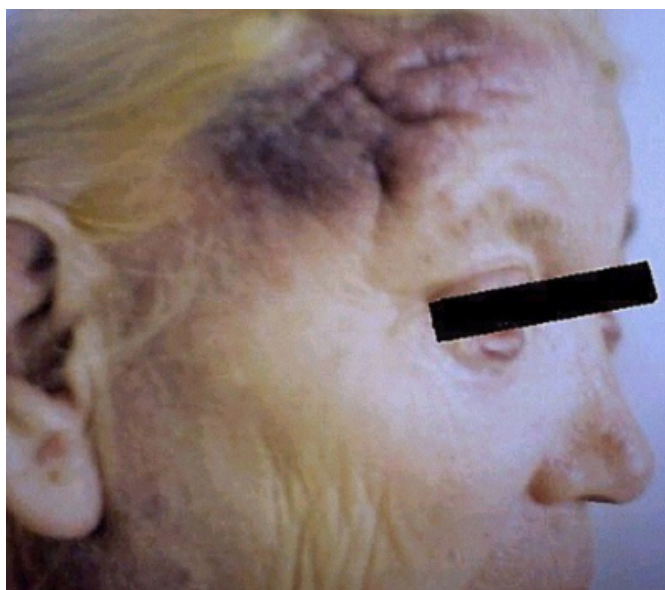The skin infiltration of leukemia known as leukemia cutis can be seen because leukemic cells from the peripheral circulation pass through the skin and remain in the dermis, which is relatively common in myelomonocytic (FAB-M4) and rare in monocytic acute non-lymphocytic leukemia's (FAB-M5). Leukemia cutis is a rare condition characterized by infiltration of the skin by leukemic cells prior to their appearance in the peripheral blood or bone marrow. We describe a patient who presented with leukemia cutis on the scalp.

CASE REPORT

A 60-year-old white woman was admitted for swelling of the eyelids and a maculo-papular lesion on her scalp. Routine biochemical and hematological studies were unremarkable. Two months later she was readmitted with a colored red purple plaque type lesions on her scalp and other lesions that spread to the trunk (Figure 1).

Figure 1

Figure 1: Colored red purple plaque type lesions on scalp and ectropion

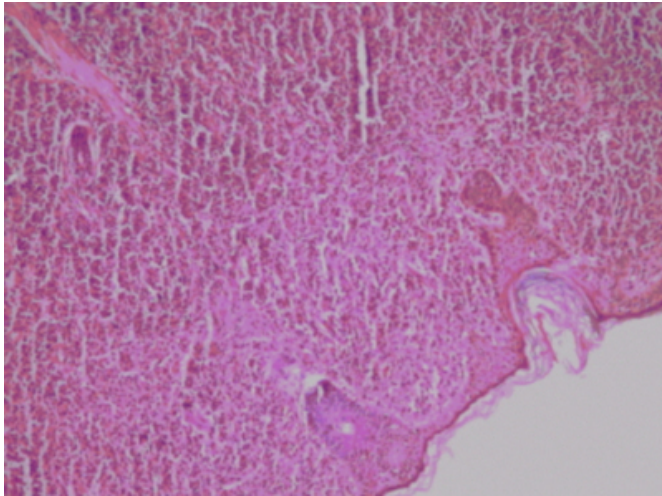


In her history she had been treated for rheumatoid arthritis for 20 years. She did not smoke and received only chronic non-steroidal anti-inflammatory therapy. Physical

examination revealed a temperature of 37.8C, pulse rate of 86 beats/min, blood pressure of 120/80 mmHg, and lymphadenopathy (2x3 cm) in the left epitrochlear area. A red purple plaque was localized on her scalp and disseminated erythematous brownish red papules and nodules localized on her substernal region and trunk. WBC was $18 \cdot 10^9/L$ Hb 8.7g/dl (13-16 g/dl) and platelets $86 \cdot 10^9/L$ (200-400. 10^9). A bone marrow biopsy showed complete replacement of normal the hematopoietic tissue by leukemic cells (98%). Erythrocyte sedimentation rate was 130 mm/h and biochemical analysis was normal except of lactate dehydrogenase with 742 IU/L. (100-190 IU/L). A dermatological biopsy showed monocytic infiltration through deep segment of dermis (Figure 2).

Figure 2

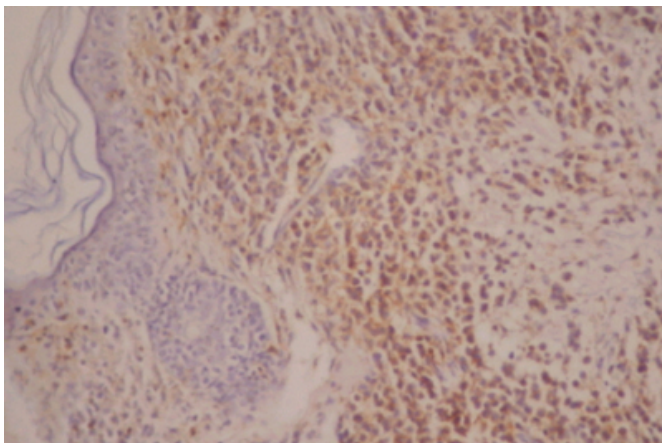
Figure 2: Monocytic infiltration in the deep segment of dermis by dermatological biopsy (x4 haematoxyline eosine).



Immunohistochemical analysis demonstrated that the cells were PGM1, KP1, CD45 and CD20 positive (Figure 3).

Figure 3

Figure 3: Mononuclear cells as CD45 and CD20 were positive by immunohistochemical analysis (x20 CD45).



The chest radiograph was normal. Abdominal ultrasonography revealed splenomegaly. Computerized tomography showed soft tissue increase in both eyelids, which were also consistent with leukemic infiltration. The patient was diagnosed with monocytic acute non-lymphocytic leukemia (FAB-M5 ANLL) according to morphological studies and antigen detecting monoclonal antibodies which were CD13, CD14, CD15, CD33, and CD34 positive. After remission, induction chemotherapy which consisted of daunorubicin and cytosine-arabioside (AraC) was started and the skin lesions decreased markedly. She was treated with the same protocol every three months, but after a year of follow-up she died because of pneumonia.

DISCUSSION

Skin infiltration of leukemia known as leukemia cutis is a distinctive feature of relatively common myelomonocytic (FAB-M4) and rare in monocytic acute non-lymphocytic leukemia's (FAB-M5 ANLL). Leukemic infiltrates can present as widespread macules and papules infiltrated plaques or nodules, which are distinctive, blue violet or red brown color. Some patients with leukemia develop diffuse maculopapular eruptions and were thought to be allergic reactions to circulating leukemic cells but most are probably true leukemic infiltrates with very few malignant cells (^{1,2,3,4}). Leukemia cutis is a rare condition characterized by the infiltration of the skin by leukemic cells prior to their appearance in the peripheral blood or bone marrow. We think that skin infiltrating cells firstly transformed into malignant cells, followed by distribution to bone marrow and systemic circulation as Millard et al. and Horlick et al's description. In this current report, the patient first presented with maculo-papular scalp lesions that resembled angiosarcoma on the scalp without any leukemic infiltrates in the bone marrow. It was postulated that immunohistochemical analysis with deparaffinized skin biopsy staining for antibodies is able to give information about the lesion but definite diagnosis of acute myeloid leukemia was not possible (³). Staining with lysozyme referred to as a good monocyte marker.. In the literature, two similar cases from different countries were reported in 1990 and 2003 (^{1,2})

Skin lesions associated with leukemia's often are non-specific, such as pruritus, purpura, and skin infections. Cutaneous infiltration of leukemic cells tends to be uncharacteristic clinically (^{5,6,7,8}). In most of the studies it was postulated that patients with leukemia cutis have poor prognosis. We presented this case in order to remind everyone about leukemia cutis in such instances.

CORRESPONDENCE TO

Dr. A. Didem Yalcin Pamukkale University, Medicine Faculty Hospital, Internal Medicine Department Denizli-Turkey Fax: 90 258 2410040 E-mail: adidyal@yahoo.com

References

1. Millard TP, Aitchison R, Wilkinson JD. Aleukaemic leukaemia cutis presenting as a benign-appearing eruption. *Clin Exp Dermatol.* 28:148-50, 2003.
2. Horlick HP, Silver DN, Knobler EH, Cole JT. Acute myelomonocytic leukemia presenting as a benign-appearing cutaneous eruption. *Arch Dermatol.* 126:653-6, 1990
3. Bennet JM, Catovsky D, Daniel MT, et al: Proposed revised criteria for the classification of acute myeloid

leukemia, Ann Intern Med, 103: 620, 1985.

4. Peterson L, Dehner LP, Brunning RD: Extramedullary masses as presenting features of acute monoblastic leukemia, Am J Clin Pathol, 75: 14-8, 1981.

5. Sepp N, Radaszkiewicz T, Meijer C.J.L.M, et al: Specific skin manifestation in acute leukemia with monocytic differentiation, Cancer, 71: 124-32, 1993.

6. Yu HJ, Kim YS, YangHY, KwanSJ, Park CK: A case of leukemia cutis, J Korean Med Sci, 13: 689-92, 1998.

7. Baer MR, Barkos M, Farrell H, Raza A, Preisler HD: Acute myelogenous leukemia with leukemia cutis. Eighteen cases seen between 1969 and 1986, Cancer, 63: 2192-200, 1989.

8. Kaddu S, Zenahlik P, Beham-Schmid C, Kerl H, Cerrani L: Specific cutaneous infiltrates in patients with myelogenous leukemia leukemia. A clinicopathologic study of 26 patients with assessment of diagnostic criteria, J Am Acad Dermatol, 40: 966-78, 1999

Author Information

Arzu Didem Yalcin, MD

Resident, Department of Internal Medicine, Faculty of Medicine, Pamukkale University

Ali Keskin, MD

Professor, Chief, Department of Hematology, Faculty of Medicine, Pamukkale University

Nese Calli, MD

Associate Professor, Department of Pathology, Faculty of Medicine, Pamukkale University