

# Esophagopleural Fistula In A 3 Year Old Child Following Disk Battery Ingestion.

A Umana, M Offiong, J Kuni, U Akpan, A Adekanye, R Mgbe, A Etiuma, A Ewa

## Citation

A Umana, M Offiong, J Kuni, U Akpan, A Adekanye, R Mgbe, A Etiuma, A Ewa. *Esophagopleural Fistula In A 3 Year Old Child Following Disk Battery Ingestion..* The Internet Journal of Otorhinolaryngology. 2010 Volume 13 Number 2.

## Abstract

Disk Battery ingestion is a medical emergency often seen children under the age of 6 years with a peak incidence in the 1 to 3 year old.<sup>2</sup> In most cases ingestion is not witnessed however in some cases especially in the older children, there is a history or suspicion of ingestion of the foreign body by the child or caregiver. Of all dangerous oesophageal FB, disk battery is the most dangerous. Occasionally, referral for endoscopic removal of ingested DB body is delayed because transition through the GIT is expected. Disk Battery ingestion seems to be an emerging pediatric emergency associated with clinically significant outcomes in our region.<sup>7</sup> We report a case of a three year old baby who ingested a disk battery and immediately informed the parents. A chest x-ray taken within 2 hours of ingestion revealed a coin like opacity but was misdiagnosed as a 50Kobo coin. The 50Kobo coin hitherto was the commonest circular metallic foreign body in the esophagus in our region. Referral for endoscopic assessment was delayed because transit through the gastrointestinal tract expected. The child seemed comfortable and asymptomatic but suffered significant injury resulting in esophageal pleural fistula within 4 days of ingestion. Battery type was CR2025 and lodgment was at the gastro esophageal sphincter. The need for early presentation to the hospital, correct diagnosis, undelayed endoscopic evaluation and removal of Disk Battery foreign body is reemphasized. The importance of careful history taking, examination and simple plain radiograph of the neck and chest and abdomen in a seeming comfortable and well child with suspicion of foreign body ingestion is highlighted. A review of relevant literature is also done.

## INTRODUCTION

Disk batteries (DB) are small, coin-shaped batteries used in devices such as remote control for MP3 players, toys, watches, calculators, and hearing aids.<sup>1</sup>

They are a commonly ingested by children under 6 years of age with a peak age of 1-3 years.<sup>2</sup> Males and females are equally affected.

The incidence of DB ingestion increases with accessibility of batteries to children. Accessibility has increased with the expanding use of DB in household and recreational products. Secured battery sources and safe disposal of spent cell also affect accessibility of DB to children.<sup>1</sup>

Most cases of DB ingestion are often not witnessed. Most children remain asymptomatic and pass the battery in their stool within 2-7 days.<sup>3</sup>

Batteries localized beyond the esophagus rarely need to be retrieved unless the patient manifests signs or symptoms of GI tract injury ( e.g. abdominal pain, tenderness) or a large-diameter battery fails to pass beyond the pylorus.

Battery passage is usually confirmed by daily inspections of all stools or weekly radiographs.

Lodgments in the esophagus typically present with irritability, food refusal, dysphagia, and increased salivation. It may present with unproductive cough, stridor and wheezing mimicking lower respiratory tract disease.<sup>4</sup>

No physical examination findings are specific for patients who ingest disk batteries. Therefore, the lack of symptoms should not be the indicator to rule out esophageal lodgment.

Recent reports of DB ingestion in the developed world show that they are usually are benign.<sup>2</sup> However, many major outcomes have occurred, when the ingestion was either not witnessed or initially misdiagnosed (including being mistaken for a coin) or delayed hospital presentation /endoscopic removal because of lack of awareness.<sup>2,4</sup>

The type of battery, size and quality, whether leak proof or not, and the status of the battery whether new or spent, are also risk factors to major outcome. From 2000-2009, 92% of disk batteries from fatal ingestions or those with major

outcomes were 20-mm lithium cells.<sup>1</sup>

The Lithium cell is associated with disproportionately more adverse effects than other types of batteries due to their larger size and increased likelihood of impaction as well as their ability to generate more current.<sup>5,1</sup>

New cells are 3.2 times more likely to be associated with clinically significant outcomes than spent cells.<sup>2</sup>

Batteries located in the esophagus should be removed as soon as possible because of the risk of esophageal burns and resultant complications. Liquefaction necrosis or perforations have been reported within 4-6hrs of ingestion and lodgement.<sup>3</sup>

Complications in major outcome of DB ingestion have included tracheoesophageal fistulas, other esophageal perforations, and esophageal strictures requiring repeated dilations. Other complications reported include vocal cord paralysis from recurrent laryngeal nerve damage, mediastinitis, pneumothorax, pneumoperitoneum, tracheal stenosis, tracheomalacia, aspiration pneumonia, empyema, lung abscess, and spondylodiscitis.<sup>2</sup>

Oesophageal perforation is rare and usually life-threatening, especially in children. The usual causes of perforations include the use of endoscopes, surgical thoracic procedures, trauma or foreign bodies. Oesophageal perforation following DB ingestion should be suspected on the basis of endoscopic findings of tissue burns or necrosis<sup>7</sup> or clinical presentation of sudden chest pain, fever, vomiting and subcutaneous emphysema following endoscopies.

A delay in diagnosis and management worsens the outcome and increases the risk of complications.<sup>2</sup>

DB ingestion seems to be an emerging problem with lack of awareness in our region.<sup>4</sup> It therefore necessary to report these conditions as they occur. Consequently we present a case of esophagopleural fistula with subsequent hydropneumothorax following a 4 day history of witnessed DB ingestion and lodgment in the oesophagus in our region. We are not aware of any Literature report of this complication in Nigeria

### **CASE REPORT**

A 3 year old boy presented to the emergency room (ER) of our hospital with a 3 day history of accidental swallow of a “button”. The child had immediately informed the mother and grandmother (both registered nurse) of swallowing a

“button” while playing outside the house. They presented to a district hospital within 2hours and a plain chest radiograph showed a radio opaque foreign body in the esophagus. This was misdiagnosed as a 50Kobo coin and parents assumed and were reassured that it will be passed out in stool. However, serial daily radiograph and inspection of patients stool showed foreign body was still in the esophagus after 3 days. The patient was then referred to our center. On presentation to us, the child was still accepting food but had a low grade fever of 37.5C. There were no other symptoms. There was mild tachypnea (respiratory rate 26 c/min), with tympanic percussion notes and clear lung fields on auscultation. The serial chest x-rays done at the district hospital showed a coin shaped opacity with a double rim appearance. We made a diagnosis of DB foreign body in the esophagus. A repeat plain neck and chest radiograph showed the foreign body was at the gastro esophageal region.- Figures 1a and 1 b Endoscopic assessment was carried out under general anesthesia via endotracheal intubation. Endoscopic findings showed edematous mucosa of the posterior wall of the esophagus at 21cm from the upper incisor tooth. A DB was lodged in the edematous mucosa at 22 – 24 cm from the upper incisor tooth. The anode (-ve) face of the battery was directed posterior with a left lateral inclination. The visible proximal edge of the FB showed signs of fragmentation. The battery slipped into the stomach following an attempt to grasp it with a foreign body removing forceps. Inspection of the bed where the Battery had lodged revealed burnt/necrotic tissue. A diagnosis of esophageal perforation was made. An immediate post endoscopy radiograph of neck, chest and abdomen showed battery was in the stomach with diminished vascular lung markings suggesting left pneumothorax. Figure 1c The child was placed on intravenous ceftriazone and metronidazole, nil by mouth and parenteral fluid and calories. A repeat x-ray after 36 hours showed the battery was in the descending colon with radiological features of left hydropneumothorax with right mediastinal shift.- Figure 1d A diagnosis of esophageal pleural fistula/left hydropneumothorax was made. The child was reviewed by the cardiothoracic surgical team. A chest tube was inserted and about 100ml of serous fluid and air was drained. - Figure 2

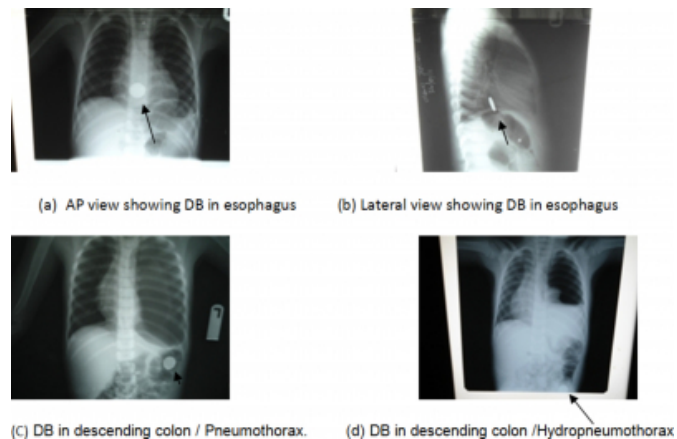
Forty eight hours post endoscopy; the child had still not passed the battery in stool but rather complained of feeling of incomplete defecation. Digital rectal examination was done and the battery removed. - Figure 4

After a week, drainage from the chest tube ceased. A light

barium swallow done on the 10th day post thoracostomy, did not show any extravasations of contrast suggesting healed esophageal pleural fistula. - Figure 3 Graded oral fluid was introduced after another 4 days. Another repeat chest X-ray showed no fluid accumulation in the pleural cavity. The chest tube was removed and the child discharge to out-patient follow up. The child is currently doing well.

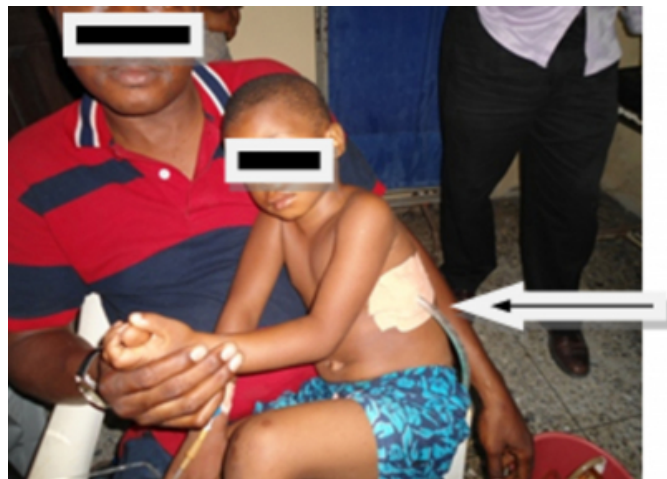### Figure 1

Figure 1: Plain radiographs showing DB in the digestive tract.



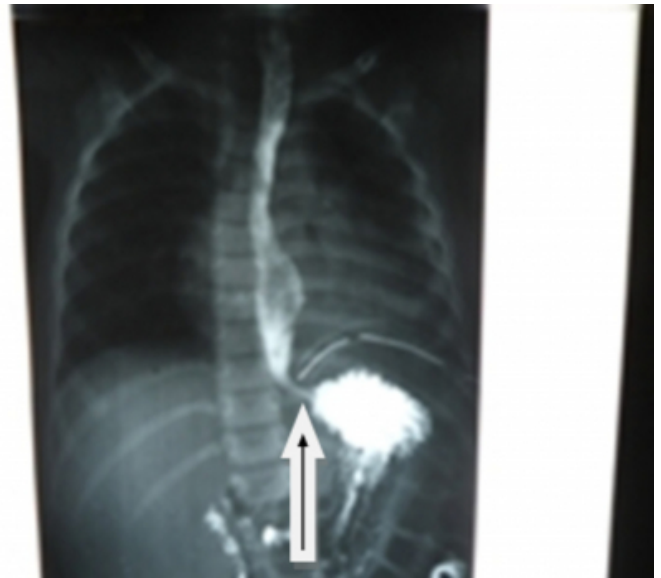### Figure 2

Figure 2: Child with thoracostomy tube




### Figure 3

Figure 3: Barium Swallow – no extravasations after one week



### Figure 4

Figure 4: DB from child with Esophagopleural fistula/ Hydropneumothorax within 4 days of ingestion.



## DISCUSSION

Oesophageal perforation following DB ingestion is a rare and usually life-threatening disease, especially in children.<sup>7</sup> Most children who ingest disk battery remain asymptomatic and pass the battery in their stool within 2-7 days.<sup>3</sup> Our patient developed esophagopleural fistula and Hydropneumothorax following a DB lodged in the esophagus for over 96 hours. Clinically significant outcomes have been reported severally in literature following lodgment and delayed removal within 2-6 hours.<sup>2,4</sup> The relatively longer duration of lodgment and perforation in our patient may be because the battery was a spent cell. New cells are 3.2 times more likely to be associated with clinically significant outcomes than spent cells.<sup>2</sup>

Our patient immediately informed the parents and grandmother of swallowing a button. They presented to a

district hospital within 2 hours and a radiograph taken showed a radio opaque foreign body in the esophagus. However, lack of awareness of DB foreign body and its misdiagnosis as a 50k coin led to a justifiable anticipation that it will transit the GIT without any sequelae.<sup>1,4</sup> The adoption of masterly inactivity by serial daily radiograph as a management approach seemed appropriate but led to delayed referral for endoscopic removal and a consequent major sequelae. This highlights lack of awareness of DB as an emerging FB in the aerodigestive pathway in our region.<sup>4</sup>

The DB was still in the esophagus 4 days after ingestion. This is not surprising because it was 20mm in diameter and only batteries less than 15mm in diameter almost never lodge in the esophagus<sup>6</sup>.

Endoscopic assessment was undertaken in the index patient although the x-ray showed that the DB was at the level of the gastro esophageal sphincter. This was justifiable because serial radiographs showed the DB had not transited the esophagus in 3 days and remained at the level of the gastro esophageal sphincter for over 18 hours. It standard clinical practice to remove batteries lodged in the esophagus as soon as possible because of the risk of esophageal burns and resultant complications.<sup>1</sup>

Our patient developed esophagopleural fistulae with subsequent pneumohydrothorax within 4 days of DB ingestion and lodgment. These may be because; the DB was a spent lithium battery cell lodged with the anode surface inclined to the left lateral direction and a necrotic base was identifiable where the battery had lodged. Lithium batteries have a higher capacitance and generate more current and produce more hydroxide more rapidly and the most severe tissue burns/liquefaction necrosis will occur adjacent to the anode. Liquefaction necrosis or perforations have been reported within 4-6hrs of ingestion and lodgement.<sup>4</sup> A spent cell, which no longer has enough power for the intended device, may still maintain considerable residual voltage to cause mucosal burns.<sup>2</sup>

Also, the edges of the battery showed signs of fragmentation. This may be because the battery was lodged at the gastro esophageal sphincter hence in close proximity to gastric acid. When a disk battery is in an acid environment, an electrochemical reaction occurs that leads to dissolution of the cathode, primarily in the crimp area.

Serial x- ray radiograph demonstrated the DB in the stomach immediate post endoscopy and in the descending colon

within 24 hours. Digital rectal examination to recover battery after 48 hours was justifiable because of the complaint of the feeling of incomplete defecation suggesting impaction. Furthermore at endoscopy, the edges of the battery showed signs of fragmentation a potential for rupture of battery.

The development of pneumohydrothorax within 36 hours post-endoscopy may be because the impacted DB was serving as lid to a potential fistula hence collection of swallowed saliva and air into the pleural cavity following dislodgement of the impacted battery.

The insertion of a chest tube was appropriate to drain the pneumohydrothorax and relief evolving respiratory distress.

The esophagopleural fistulae healed following conservative management (parenteral antibiotics, nil by mouth and parenteral fluid and calories).

This patient will be closely followed up on a long term because recurrences of perforation have been reported even following delayed surgical repair.

### **CONCLUSION**

Fatal cases of DB or those with major sequelae usually involve esophageal or airway battery lodgments.<sup>2</sup> Patients with coin like FB lodged in the esophagus should be referred without delay for endoscopic assessment and removal.

Products using Disk Batteries need to be designed with secure battery compartments while spent batteries must be properly disposed out of reach of children.

### **References**

1. Daniel J.D, Asim Tarabar. Disk Battery Ingestion. <http://emedicine.medscape.com/article/774838-overview>. Assessed 7/8/2011
2. Litovitz T, Whitaker N, Clark L, White NC, Marsolek M. Emerging battery-ingestion hazard: clinical implications. *Pediatrics*. Jun 2010; 125(6):1168-77.
3. Chan YL, Chang SS, Kao KL, Liao HC, Liaw SJ, Chiu TF, et al. Button battery ingestion: an analysis of 25 cases. *Chang Gung Med J*. Mar 2002; 25(3):169-74.
4. Umana A.N, Offiong M. E, Atana Uket Ewa, Francis P, Abiola Grace Adekanye, Mgbe R.B, Akpan N, Bassey A. Foreign body (disk battery) in the oesophagus mimicking respiratory problem in a 13 months old baby-delayed diagnosis. *Journal of Medicine and Medical Science*. Mar 2011; 2(3) 714-717.
5. Slamon NB, Hertzog JH, Penfil SH, Raphaely RC, Pizarro C, Derby CD. An unusual case of button battery-induced traumatic tracheoesophageal fistula. *Pediatr Emerg Care*. May 2008; 24(5):313-6.
6. Yardeni D, Yardeni H, Coran AG, Golladay ES. Sever esophageal damage due to button battery ingestion: can it be prevented? *Pediatr Surg Int*. Jul.20 (7):496-501.

7. Umana A.N, Offiong M. E, Etiuma A.U, Atana Uket Ewa, Francis P. Abiola Grace Adekanye, Mgbe R.B, Akpan N, Bassey A. Tracheoesophageal fistula within 72 hours of disk battery impaction in the esophagus in a 14months old baby. International Journal of Tropical Surgery. Sept 2011. Accepted for publication.

**Author Information**

**A.N. Umana**

Otorhinolaryngology Department, University Of Calabar Teaching Hospital

**M. E. Offiong**

Otorhinolaryngology Department, University Of Calabar Teaching Hospital

**J. Kuni**

Otorhinolaryngology Department, University Of Calabar Teaching Hospital

**Umoh Akpan**

Otorhinolaryngology Department, University Of Calabar Teaching Hospital

**Abiola Grace Adekanye**

Otorhinolaryngology Department, University Of Calabar Teaching Hospital

**R. B. Mgbe**

Otorhinolaryngology Department, University Of Calabar Teaching Hospital

**A.U. Etiuma**

Surgery Department, Cardiothoracic Unit, University Of Calabar Teaching Hospital

**Atana Uket Ewa**

Pediatric Department, University Of Calabar Teaching Hospital