

An Anomalous Palmaris Brevis Muscle and its Clinical Implications

S Das, S Paul

Citation

S Das, S Paul. *An Anomalous Palmaris Brevis Muscle and its Clinical Implications*. The Internet Journal of Surgery. 2006 Volume 9 Number 2.

Abstract

The palmaris brevis (PB) muscle is a small, thin, subcutaneous muscle of the palm. The palmaris brevis muscle is important muscle contributing to the grip of the hand. In the present case, during routine cadaveric dissection, we detected a PB muscle which was not subcutaneous but existed as a muscle deep to the dermis of the skin of the palm. The PB muscle stretched as a horizontal band over the hypothenar muscles of the palm. The anomalous location of the PB may result in compression of neurovascular structures on the ulnar side of the palm. The awareness of such anomalous muscle which is not subcutaneous, may be clinically important for surgeons operating on the hand and clinicians diagnosing compressive symptoms.

INTRODUCTION

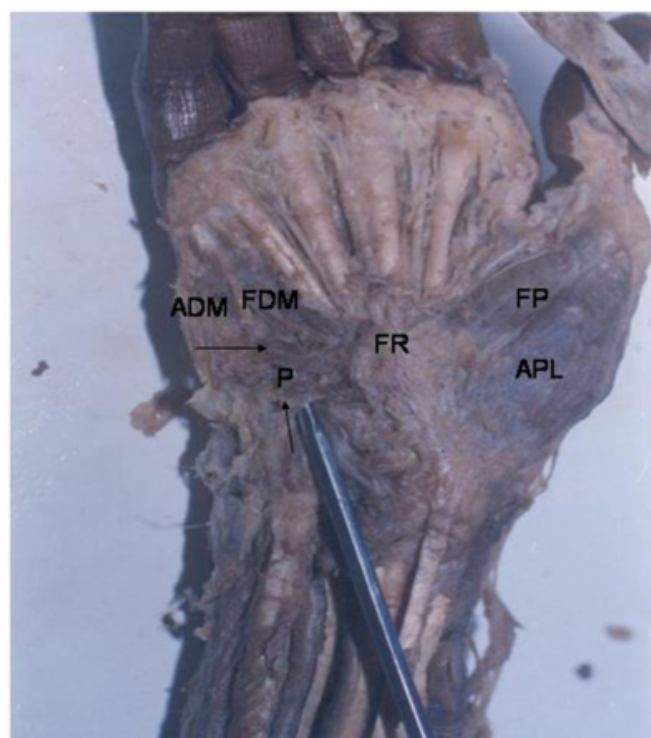
The PB muscle is a thin subcutaneous muscle. The PB arises from the flexor retinaculum and the medial border of the central part of the palmar aponeurosis and attached to the dermis of the skin on the ulnar side of the palm. ¹ The PB is innervated by the ulnar nerve and the main action of the muscle makes the palmar grip more secure. ¹ The clinical importance of the muscle lies in the fact, that it lies above the ulnar artery and the ulnar nerve in the palm. Any anomalous position of the muscle may produce compressive symptoms on these neurovascular structures. The PB spasm syndrome is an important clinical condition which may require immediate treatment. ² The PB muscle is also used as a musculocutaneous flap. ³ An anatomical knowledge of the normal and abnormal anatomy of the PB muscle may be important for clinicians and surgeons.

CASE REPORT

During routine dissection of cadaver for undergraduate medical teaching, we detected anomalous PB muscle on both sides of a 42 year male cadaver who died of anemia. The PB muscle was carefully dissected and studied. As such, it is difficult to dissect a PB muscle, as it is always subcutaneous and while reflecting the skin it usually comes out with the skin. While dissecting the ulnar side of the palm, we observed that the PB muscle ('P' in Fig.1) was much below the dermis of the skin. The muscle fibres traversed a horizontal course above the hypothenar muscles. The muscle was lifted with a forcep and was photographed (Fig.1).

Figure 1

Figure 1: Photograph of dissected right palm showing



P: Palmaris Brevis
F: Flexor Digiti Minimi
A: Abductor Digiti Minimi
Fr: Flexor retinaculum

DISCUSSION

As per standard textbook of anatomy, the PB is a thin muscle arising from the flexor retinaculum, central part of the medial border of the palmar aponeurosis and is attached to the dermis of the skin on the ulnar side of the palm.^{1,4} The PB by virtue of its attachment to the dermis of the skin has the unique action of steadying the skin while gripping.¹ The hypothenar eminence of the palm is deepened by the PB muscle. Any anomalous attachment of the PB muscle as seen in the present case, may not have any role in the deepening of the hollow of the skin of the palm thereby reducing the gripping function.^{1, 4}

Interestingly, the PB flap has been used in conjunction with internal neurolysis in a patient of recurrent bilateral carpal tunnel syndrome secondary to mucopolipidosis.⁵ It has been found that the use of highly vascular PB turnover flap as an adjunct to internal neurolysis discourages scarring and provides a nutrient bed for axonal regeneration, thus encouraging its chances of being used in recurrent carpal tunnel syndrome.⁵ The proximity of the PB muscle to the operating field, minor functional motor loss, adequate padding of the subcutaneous fat and the less chances of scar formation account for the reasons of using the PB muscle flap.⁵ The surgeons operating on the hand who use the muscle flap for reconstructive surgeries may be aware of such anomalies.

Research reports have described that PB muscle is not under voluntary control and spontaneous, irregular, tonic contractions of the PB muscle may cause PB spasm syndrome.² It is therefore very important that the topographical anatomy of the PB muscle may be understood.

The PB may sometimes press upon the ulnar vessels and the nerve producing compressive symptoms. Anomalous position of the PB as seen in the present case may cause such compressions on the ulnar vessels and the nerves.

Admittedly, we did not have any clinical history of the patient to corroborate this fact. A past study had reported the accessory PB causing ulnar tunnel syndrome in an individual.⁶ A study had also reported the duplication of the PB muscle as the PB profundus muscle.⁷ There is paucity of literature on the anomalous PB muscle. Considering the above facts, role of the PB muscle cannot be undermined clinically. We as anatomists report this case for academic and clinical interest.

CORRESPONDENCE TO

Prof. Shipra Paul MBBS, MD, FIMSA, MNAMS D-II/A-75, Nanak Pura, MotiBagh-South New Delhi-110021, India Tel: 91-11-2611975 E-mail: drshipra14@yahoo.com

References

1. Standring Susan. Gray's Anatomy. The Anatomical Basis for Clinical Practice. 39th ed. New York, Elsevier Churchill Livingstone, 2005, 918.
2. Serratrice G, Alulae JP, Serratrice J, Pouget J. Palmaris brevis spasm syndrome. J Neurol Neurosurg Psychiatry 1995 ; 59 (2):182-4.
3. Ueda K, Inoue T. The new palmaris brevis musculocutaneous flap. An Plast Surg 1994 ;32 (5) :529-34.
4. Sinnatamby CS. Last's Anatomy. Regional and Applied. 10th edition, Churchill Livingstone, 2001, 76.
5. Rose EH. The use of the palmaris brevis flap in recurrent carpal tunnel syndrome. Hand Clin 1996 ; 12 (2) :389-95.
6. Robinson D, Aghasi MK, Halperin N. Ulnar tunnel syndrome caused by an accessory palmaris muscle. Orthop Rev 1989 ; 18 (3) :345-7.
7. Tonkin MA, Lister GD. The palmaris brevis profundus. An anomalous muscle associated with ulnar nerve compression at the wrist. J Hand Surg [Am] 1985 ;10(6 Pt 1) : 862-4.

Author Information

Srijit Das, M.S.

Associate Professor, Department of Anatomy, Maulana Azad Medical College

Shipra Paul, M.D.

Department of Anatomy, Maulana Azad Medical College