

Chylothorax with chyloascites

A Uysal

Citation

A Uysal. *Chylothorax with chyloascites*. The Internet Journal of Pulmonary Medicine. 2008 Volume 10 Number 2.

Abstract

We report a case of a 54 year old man with history of hepatitis C, liver cirrhosis, esophageal varices, polysubstance abuse who was treated with interferon therapy for several months. He presented with progressive shortness of breath and abdominal distension. The patient was admitted with ascites and large pleural effusion that required serial paracenteses and thoracenteses. The findings were consistent with chyloascites and chylothorax that were caused by cirrhosis. We will review the case in view of current literature and latest treatment modalities.

KEY POINTS

- Chyloascites is rare. It has multiple causes and one of the uncommon causes is cirrhosis.
- Chyloascites can also be caused by lymphoma, occult cancer, cardiomyopathy, constrictive pericarditis.
- It can require multiple serial taps to drain the fluid in the abdomen and chest.
- Elevated triglycerides in the ascitic and pleural fluid is associated with these conditions.

INTRODUCTION

Accumulation of triglycerides in the peritoneal fluid and pleural fluid is known as chyloascites and chylothorax, respectively. It can occur in the setting of cirrhosis as well as trauma, malignancy, nephrotic syndrome and cardiomyopathy.

We report a 54 year old male with history of hepatitis C, liver cirrhosis who presented to the hospital complaining of progressive shortness of breath and abdominal distension.

The patient required serial paracenteses and thoracenteses. These yielded markedly elevated triglycerides. These results were consistent with the diagnoses of chyloascites and chylothorax.

The patient once diagnosed underwent cat scans to rule out occult malignancy. He also underwent peritoneal-venous shunt study which did not reveal any evidence of shunting from the abdomen to chest.

The patient responded well to the hospital treatment. The patient's chyloascites was thought to be due to his cirrhotic liver. Pathogenesis, diagnosis and therapy of chyloascites as well as chylothorax are reviewed for this unusual condition.

CASE REPORT

The patient presented to the hospital complaining of worsening shortness of breath and abdominal distension which got worse over several days.

On admission his vital signs were normal and he was afebrile at 98.0 F (36 C).

Relevant findings on physical exam were presence of marked abdominal distension as well as shifting dullness. The patient also had dullness to percussion and absent breath sounds over right lung base.

Relevant laboratory findings were slightly elevated plasma lactate dehydrogenase (LDH) of 218 U/L, low albumin levels of 2.9 g/dL, total protein of 7.3 g/dL. Patient had normal white blood cell count (wbc) of 5.0 K/cmm. He had slightly elevated liver enzymes and had mild thrombocytopenia of 134 K/cmm. Patient was mildly coagulopathic with an INR of 1.3.

The ultrasound of his liver revealed findings of cirrhosis, ascites and moderate splenomegaly. CT scans of the abdomen and pelvis revealed evidence of hepatosplenomegaly, retroperitoneal and paraaortic lymphadenopathy.

CT scan of the chest area as well as chest Xray (Figure 1 and 2) revealed presence of large pleural effusion.

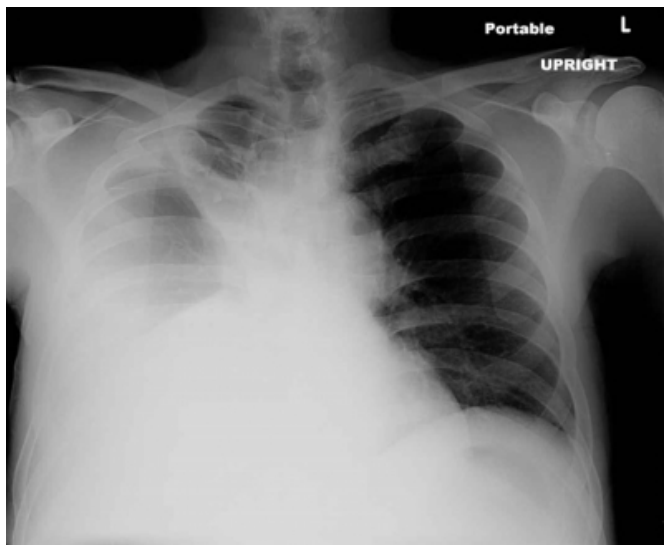
Figure 1

Figure 1: Ct chest showing large right pleural effusion.

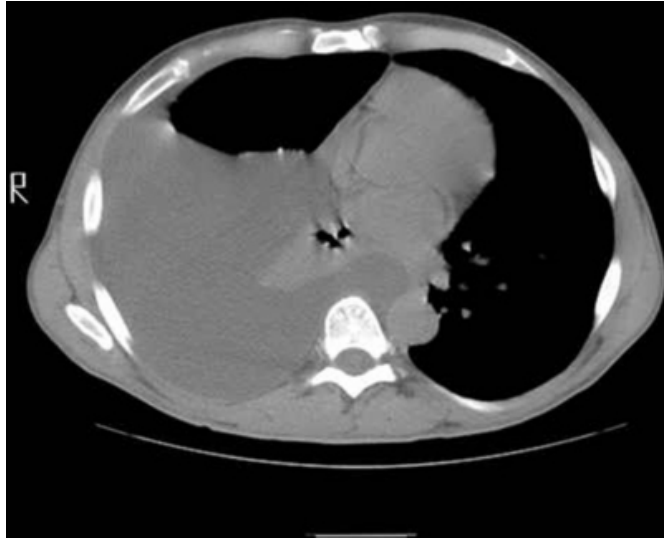

Figure 2

Figure 2: CXR showing large right pleural effusion



He underwent thoracentesis was consistent with chylothorax. The fluid was cloudy and straw colored. Pleural triglycerides was 401 mg/dL, glucose of 116 mg/dL and LDH of 70 U/L.

The patient also had several large volume paracentesis with subsequent intravenous albumin administration. Paracentesis did not show any evidence of infection and yielded total triglycerides of 200, albumin of less than 1g/dL, protein of 1 g/dL, cholesterol of 9 and LDH of 41 U/L. Tuberculosis was also ruled out by Tuberculin skin test as well as negative acid fast bacilli in pleural and ascitic fluid. Filariasis was ruled out as well. He underwent peritoneal-venous shunt study which did not reveal any evidence of shunting from

the abdomen to chest. The patient was started on spironolactone and furosemide for fluid removal and responded well to the treatment. He was discharged home with clinic follow up.

DISCUSSION

Chyloascites and chylothorax are the result of accumulation of chyle in peritoneal and pleural spaces.¹ Triglyceride rich fluid is known as chyle and is associated with chylomicrons.² Rupture of dilated lymph vessels can cause chyloascites and chylothorax.³

Chylothoraces are usually characterized by presence of triglyceride levels of more than 110 mg/dL, a ratio of pleural fluid to the serum triglyceride level of more than 1.0 and a ratio of the pleural fluid to serum cholesterol level of less than 1.0.⁴

Chylous ascites is a rare and it approximately occurs in 1 in 20000 cases.⁵ It can be due to disruption of the lymphatic system. Surgery most notably esophagectomy and surgery for congenital heart disease,⁶ abdominal trauma, malignancy, cardiomyopathy, right heart failure and cirrhosis are some of the major culprits.⁵ It can also be associated with nephrotic syndrome,⁷ as well as Henoch-Schonlein purpura.⁸

Chylothorax can be a rare manifestation of underlying malignancy most notably lymphomas.⁹ Altiparmak et al.¹⁰ described a rare case of constrictive pericarditis leading to chylothorax and chyloascites.

In cirrhotic patients, transdiaphragmatic passage of fluid from ascitic abdomen can lead to chylothorax.

Dyspnea is the most common complaint with chylothorax.⁶

This condition is often treated with low-fat diet supplemented with medium-chain triglyceride oil. In the patients where dietary compliance was an issue, xenical has been used with therapeutic success.⁵ Other treatment modalities include transjugular intrahepatic portosystemic shunt (TIPS)¹¹ and lymphoma related disease can be treated with radiation, chemotherapy. In patients where chylothorax is resistant to chemotherapy and radiation, medical thoracoscopic talc pleurodesis has been utilized with low complication rates.⁴

In conclusion, chyloascites and chylothorax are the result of accumulation of triglyceride rich fluid and can cause substantial discomfort to the patient. It can be caused by a number of underlying conditions such as cirrhosis,

malignancy, lymphoma and cardiomyopathy. Dietary modification, fluid removal by paracentesis or thoracentesis and TIPS are some of the treatment options that are available.

CORRESPONDENCE TO

Dr. Askin Uysal. Veterans Hospital Overton Brooks Medical Center, Department of Medicine, 501 East Stoner Avenue, Shreveport, Louisiana 71104 Email: askinuysal2003@yahoo.com

References

1. Hussain M, Ansarie M, Mehmood K. Chylothorax and chyloascites complicating cirrhosis of liver. *J Coll Physicians Surg Pak*. 2004;14(10):631-633.
2. Oosterbosch L, Leloup A, Verstraeten P, Jordens P. Chylothorax and chylous ascites due to malignant lymphoma. *Acta Clin Belg*. 1995;50(1):20-24.
3. Noel AA, Gloviczki P, Bender CE, Whitley D, Stanson AW, Deschamps C. Treatment of symptomatic primary chylous disorders. *J Vasc Surg*. 2001;34(5):785-791.
4. Romero S. Nontraumatic chylothorax. *Curr Opin Pulm Med*. 2000;6(4):287-291.
5. Chen J, Lin RK, Hassanein T. Use of orlistat (xenical) to treat chylous ascites. *J Clin Gastroenterol*. 2005;39(9):831-833.
6. Doerr CH, Allen MS, Nichols FC, 3rd, Ryu JH. Etiology of chylothorax in 203 patients. *Mayo Clin Proc*. 2005;80(7):867-870.
7. Chen YC, Kuo MC, Chen HC, Liu MQ, Hwang SJ. Chylous ascites and chylothorax due to the existence of transdiaphragmatic shunting in an adult with nephrotic syndrome. *Nephrol Dial Transplant*. 2005;20(7):1501-1502.
8. Lee TH, Lee EY, Cho YS, Yoo B, Moon HB, Lee CK. Concurrent occurrence of chylothorax and chylous ascites in a patient with henoch-schonlein purpura. *Scand J Rheumatol*. 2003;32(6):378-379.
9. Bautz JB, Delaney MD, Mostaghim R, Lodato RF. Chylothorax as presenting manifestation of adenocarcinoma with probable gastric primary. *Chest*. 1991;99(4):1044-1045.
10. Riza Altiparmak M, Avsar S, Yanik S. Chylous ascites and chylothorax due to constrictive pericarditis in a patient undergoing haemodialysis. *Neth J Med*. 2004;62(2):59-61.
11. Kinney TB, Ferrara SL, Miller FJ, Roberts AC, Hassanein T. Transjugular intrahepatic portosystemic shunt creation as treatment for refractory chylous ascites and chylothorax in a patient with cirrhosis. *J Vasc Interv Radiol*. 2004;15(1 Pt 1):85-89.

Author Information

Askin Uysal, MD

Department of Medicine, Veterans Hospital Overton Brooks Medical Center