

Thrombosis of Common Femoral Vein after Left Heart Catheterization– An Unusual Complication Resulting from Application of a Compression device: A Case Report and Review of Literature

K Modi, S Illum, P Reddy, M Reddy

Citation

K Modi, S Illum, P Reddy, M Reddy. *Thrombosis of Common Femoral Vein after Left Heart Catheterization– An Unusual Complication Resulting from Application of a Compression device: A Case Report and Review of Literature*. The Internet Journal of Cardiology. 2007 Volume 6 Number 1.

Abstract

Femoral vein thrombosis is not a commonly recognized complication of left heart catheterization. We present an unusual case of acute femoral vein thrombosis occurring after left heart catheterization. The case highlights a potential complication from application of compression device for prevention of hematoma formation or its expansion due to bleeding from femoral artery access site.

CASE

A 33 year old white female with diabetes and hypertension presented to her community hospital with complaints of abdominal pain, nausea and vomiting. The patient was diagnosed with an inferior ST segment elevation myocardial infarction and was transferred to LSUHSC for left heart catheterization which revealed total occlusion of proximal right coronary artery with collaterals, and the left anterior descending and left circumflex artery had noncritical lesions. Left ventricular angiogram revealed normal systolic function. Hemostasis was obtained with manual pressure. Medical treatment was continued with aspirin and clopidogrel. Forty eight hours after left heart catheterization patient complained of severe pain over the femoral artery access site in the right groin and swelling in the right thigh. An acute bleed from the right femoral artery access site resulting in hematoma in the right thigh was diagnosed and manual pressure was applied for 30 minutes. This was followed by placement of “FemoStop”, a femoral artery compression device over the site of bleed at a pressure of 120mmHg for 20 minutes which was decreased by 20mmHg every 30 minutes until a pressure of 30mmHg was reached. The device was then left in place at a pressure of 30mmHg for a total of six hours. The patient had no further bleeding complications.

An ultrasound of the right groin was obtained the following

day which revealed thrombosis of the right common femoral vein with a surrounding hematoma (figure 1). CT angiogram did not show any pseudoaneurysm or AV fistula (Figure 2) Treatment with warfarin was initiated together with aspirin and clopidogrel. Ultrasound examination of the right groin was repeated four days later and showed complete recanalization of thrombus in the right common femoral vein.

An adenosine stress test was performed and revealed a large area of mixed ischemia and infarction in the inferoseptal wall. Before discharge from the hospital patient had successful intervention of the right coronary artery from contralateral femoral arterial access. Warfarin, ASA and clopidogrel were continued at discharge.

Figure 1

Figure 1: 2.8 X 1.7 mixed echo textured area representing groin hematoma adjacent to the right femoral vessels. There is partial recanalization of the right common femoral vein with partial compressibility. Compressed vein (black arrow) and hematoma (white arrow)

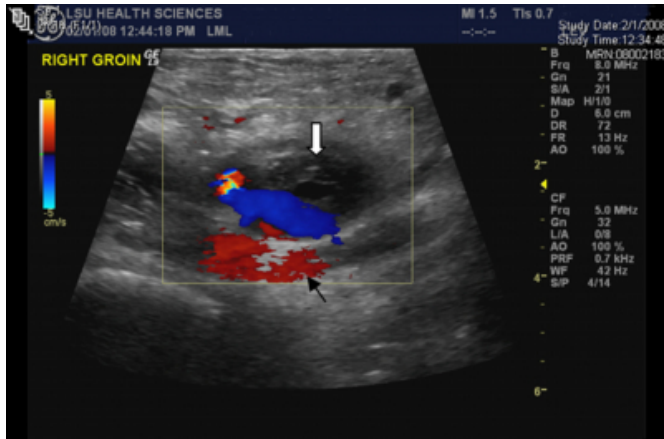
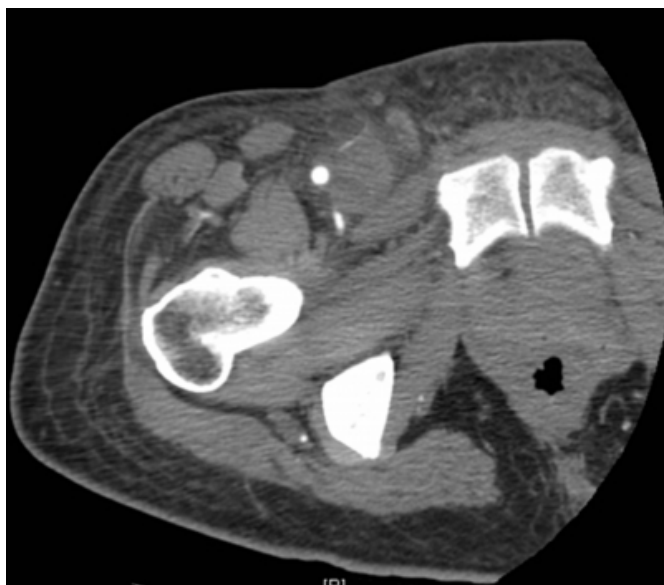


Figure 2

Figure 2: Axial CT angiogram slice of the right lower extremity. This demonstrates normal caliber common femoral artery with rounded soft tissue density in the expected position of the femoral vein without any immediate enhancement to suggest arterio-venous (AV) communication. There are post-procedural changes due to groin puncture for cardiac catheterization.



DISCUSSION

Local vascular complications occur in 0.5 to 0.6% of patients following diagnostic catheterization procedures and in 2.8% of patients following combined diagnostic and interventional procedures. (1, 2) These complications include

arterial thrombosis, distal embolization, dissection, fistula formation, Pseudoaneurysm, hematoma, and bleeding from the puncture site.

Our case highlights a rare vascular complication resulting from treatment to prevent bleeding and hematoma expansion with application of a compression device over femoral artery access site.

Continued bleeding from an arterial access site may be due to a poorly placed puncture, vessel laceration, excessive anticoagulation, or due to poor technique in using either closure devices, or mechanical groin compression. Local compression manually or with a mechanical compression device is an excellent method to prevent post catheterization bleeding and hematoma, with a success rate of well above 90% and a very low incidence of serious complications. Mechanical clamp compression reduces the amount of time and effort required to assure hemostasis, and may possibly reduce the rate of vascular complications. In one study 778 patients were randomly assigned to hand applied pressure or mechanical clamp pressure; the latter reduced the frequency of ultrasound-defined femoral vascular complications (femoral artery thrombosis, echogenic hematoma, pseudoaneurysm, or arteriovenous fistulae formation) by 63 percent (3)

Femoral vein thrombosis is a rare complication of femoral artery catheterization. In 1982 Gwost et al analyzed complication of cardiac catheterization in 1771 patients over a nine year period and found an incidence of 0.64% of asymptomatic pulmonary embolus or infarction within 24 hrs of femoral artery catheterization presumably due to femoral vein thrombosis (4) In another study asymptomatic lung scan abnormalities possibly representing small pulmonary emboli have been described in 8.3% of patients after diagnostic right and left heart catheterization. The duration of manual groin compression was longer in patients who developed new lung perfusion defects (8). Since then there have been a few isolated case reports of femoral vein thrombosis following femoral artery catheterization, a majority of them resulting from external compression of femoral vein by a hematoma and pseudo aneurysm. In one case, thrombin injection of pseudoaneurysm was followed by femoral vein thrombosis. (5, 6, 7, 9, 10) The mechanism responsible for common femoral vein thrombosis in our case remains uncertain but most likely a consequence of groin hematoma compressing the femoral vein, sustained femoral puncture-site compression using a compression device and

possibly bed rest.

The case presented here places venous thrombosis on the list of potential complications that result from manual compression of arterial puncture site to prevent hematoma formation.

CORRESPONDENCE TO

Kalgi Modi, MD, FACC, FASE Assistant Professor of medicine Section of cardiology 1501 Kings Highway Shreveport, LA 71106 Phone: 318 675 5943 Fax: 318 675 5686 E-mail: kmodi@lsuhsc.edu

References

1. Noto TJ, Johnson LW, Krone R, et al. Cardiac catheterization 1990: a report of the registry of the Society for Cardiac Angiography and Intervention. *Cather Cardiovascular Diagn* 1991; 24:75
2. Agostoni P, Giuseppe GL, Biondi -Zaccai et al. Radial versus femoral approach for percutaneous coronary diagnostic and interventional procedures, Systemic overview and meta analysis of randomized trials. *JACC* 2004; 44:349-56
3. A randomized trial of vascular hemostasis techniques to reduce femoral vascular complications after coronary intervention. Pracyk JB; Wall TC; Longabaugh JP; Tice FD; Hochrein J; Green C; Cox G; Lee K; Stack RS; Tchong JE *Am J Cardiol* 1998 Apr 15;81(8):970-6.
4. Gwost, J, Stoebe, Tom, Chesler, E Weir, KE. Analysis of the complications of cardiac catheterization over nine years. *Cathet Cardiovasc Diag* 8: 13-21, 1982
5. Gowda S, Bollis AM, Haikal AM, Salem BI, Incidence of new focal pulmonary emboli after routine cardiac catheterization comparing the brachial to the femoral approach. *Cathet Cardiovasc Diag* 1984; 10:157
6. Slysco, R. Mondek, P. Lofaj, P. Sefranek, V. Post-catheterization pseudoaneurysm of the femoral artery-an unusual cause of femoral vein thrombosis-case report and review of the literature. *Rozhledy V Chirurgii*. 83(3):113-7, 2004 Mar.
7. Grossman's Cardiac Catheterization, Angiography, and Intervention, seventh edition page 44, Herman MG, Brigham and Women's Hospital Kurz DJ, Jungius KP, Luscher TF. Delayed Femoral Vein Thrombosis after Ultrasound -guided Thrombin injection of Post Catheterization Pseudoaneurysm. *Journal of Vascular and Interventional Radiology* 2003; 14(8):1067-1070.
8. Shammass RL, Reeves WC, Mehta PM, Deep venous thrombosis and pulmonary embolism following cardiac catheterization. *Cathet Cardiovasc Diag* 1993;30: 223
9. Klein-Weigel, Pillokat P, Klemens A, Koning M, Wolbergs C, Schroder S, Wissgott H, Flessenkamper C, Steinkamp H. Proximal deep venous thrombosis following PTA of the superficial femoral artery - an obligation to disclose a complication that is rarely taken into account. *Vasa* 35(1):41-4, 2006 Feb. Gefazsszentrum Mitte, DRK Kliniken Berlin, Mark Brandenburg, Berlin, Germany.
10. Kurz DJ, Jungius KP, Luscher TF Delayed Femoral Vein Thrombosis after Ultrasound guided Thrombin Injection of a Post catheterization Pseudoaneurysm *J Vasc Interv Radio* 2003; 14 1067-1070

Author Information

Kalgi Modi

Louisiana State University Health Science Center

Sandra Illum

Louisiana State University Health Science Center

Pratap Reddy

Louisiana State University Health Science Center

Madhusudhan Reddy

Louisiana State University Health Science Center