

Cervical Polypectomy During Pregnancy: Is There Any Management Advances On The Last Decades?

C Panayotidis, A Alhuwalia

Citation

C Panayotidis, A Alhuwalia. *Cervical Polypectomy During Pregnancy: Is There Any Management Advances On The Last Decades?*. The Internet Journal of Gynecology and Obstetrics. 2004 Volume 5 Number 1.

Abstract

The diagnosis of a cervical polyp during pregnancy is not an uncommon condition. These polyps can give concern to the pregnant woman despite their benign nature in the majority of cases. The management depends on the symptoms. Most of the time, conservative approach is preferred. This article summarises the essential points of the current management and gives a recent review of literature of cervical polypectomy during pregnancy.

INTRODUCTION

The diagnosis of a cervical polyp during pregnancy is not an uncommon condition. These polyps can give concern to the pregnant woman despite their benign nature in the majority of cases. Protruded cervical polyps out of the vulva are rare and their management depends on the symptoms. Most of the time, conservative approach is preferred only for small polyps.

REVIEW AND DISCUSSION

DISCOVERY OF A POLYP DURING PREGNANCY

Cervical polyps are relatively common in pregnancy, especially in women older than 20 who have had at least one child. Many times the polyp is asymptomatic and the pregnant woman does not know its existence. Occasionally it can be diagnosed during vaginal examination in labour. If asymptomatic, it disappears most of the times itself during the delivery. If the polyp remains intact at the time of delivery the obstetrician may consider removing it. The polyp can be present with various signs such as vaginal discharge, bleeding after intercourse, discharge that can be foul smelling if there is an infection, or recurrent vaginal infections.

PATIENT CONCERNS

The pregnant woman can be very concerned about the polyp because of the recurrent bleedings or infection risks or because the possible existence of a protruded growth which could lead to a premature labour, difficulties of delivery or increased risks of bleeding during labour.

NATURE OF POLYPS

When a polyp is found during pregnancy the examination must be thorough in order to exclude malignancy. Most polyps are small, less than 2 centimetres long. Because rare types of cancerous conditions can look like polyps, all polyps should be removed and examined to exclude malignancy. The polyps are usually cherry-red to reddish-purple or greyish-white. They vary in size and often look like bulbs on thin stems. The cause of cervical polyps is not well understood. Cervical polyps can occur alone or in groups. They may be associated with chronic inflammation, an abnormal local response to increased levels of oestrogen, or local congestion of cervical blood vessels.

MANAGEMENT

The management depends on the type of polyp. As it was illustrated in the previous case example, if the polyp is pedunculated and small without evidence of infection, conservative management is advised. On the other hand, if symptoms occur with intermittent vaginal bleeding, vaginal discharge, change in the appearance aspect of the polyp such as ulceration with additional cervicitis, removal is the rule under antibiotic cover.

Occasionally polyps can be long and big enough to provoke discomfort to the pregnant woman. Polyps can be protruded, visible out of the vulva giving pain or discomfort. Again in these cases polypectomy is to be undertaken. Metaplasia and precancerous changes can occur in inflamed polyps. It is not certain what the influence of these long protruded polyps is on the matrix of the cervix. Limited data suggest that

presence of polyps on the cervix in pregnancy may modify the consistency and enzyme properties of the cervix. In a paper granulocyte elastase activity in cervical mucus was measured and showed significant difference between pregnant women with polyps. From this research the authors conclude that polyps encourage inflammation and may risk local infection or even chorioamnionitis! [1] It is suggested that cervical polyp during pregnancy should be removed. If polypectomy can not be performed, local anti-inflammatory and anti-microbial therapy would be needed.

POLYPECTOMY TECHNIQUES

A polyp forceps is used to grasp the base of the polyp stem, and the polyp is taken off with twisting motion. Depending the shape of the polyp, twisting is to be avoided in pregnancy because the polyp basis can bleed significantly. In this case electrocoagulation of the site can be used with the necessary settings to assure good haemostasis. More often during pregnancy a polyp is removed by tying a surgical ligature around the base and cutting it off. Removal of the base is done by electrocautery or laser vaporization. Because many polyps are infected, antibiotics may be administered after the removal, either prophylactically or with any early signs of infection. Once removed, polyps tend not to have recurrence on the same site. Extremely rarely, aggressive tumours can be imitating polypoid formation such as pseudo-sarcoma botryoides of cervix [2]. Cervical polyps can present in other clinical situations in pregnancy such as an inevitable abortion [3]. In early pregnancy expulsion of decidualised polyps was described in association with uterine malformations [4,5].

IN ORDER TO ILLUSTRATE THE ABOVE WE PRESENT A CASE OF A PROTRUDED CERVICAL POLYP DURING PREGNANCY

A 37 years old, primigravida presented with blood stained discharge at 19 weeks gestation. She had normal smears in the past and the ultrasound scan at 19 weeks shown a posterior fundal placenta and excluded any placental cause of bleeding. Since then she had intermittent light blood stained discharge and at 21 weeks of gestation a pediculated polyp measuring 5X3cm was diagnosed on vaginal examination. A week later, the polyp increased in size and shape measuring 5X7 cm, it was becoming more inflamed and elongated. She was given oral cephalixin to treat cystitis, her symptoms improved but a week later; she was readmitted for moderate antepartum haemorrhage and vaginal discomfort. The polyp was visible as it protruded out of the vulva. Steroids were given, smear was taken from the

polyp that excluded malignancy and finally at 29 weeks under spinal anaesthesia the polyp was removed. The pedicle was clamped and ligated See Photos I -IV. She was discharged the next day. Her symptoms of discomfort and recurrent bleeding disappeared. Finally she had a normal vaginal delivery at term plus 10 days. The histology of the pedunculated cervical polyp showed a benign endocervical polyp with extensive microglandular hyperplasia and superimposed squamous metaplasia. No evidence of dysplasia or malignancy was diagnosed. Follow up has been arranged in 3 months

Figure 1

Photo I: Pedunculated polyp

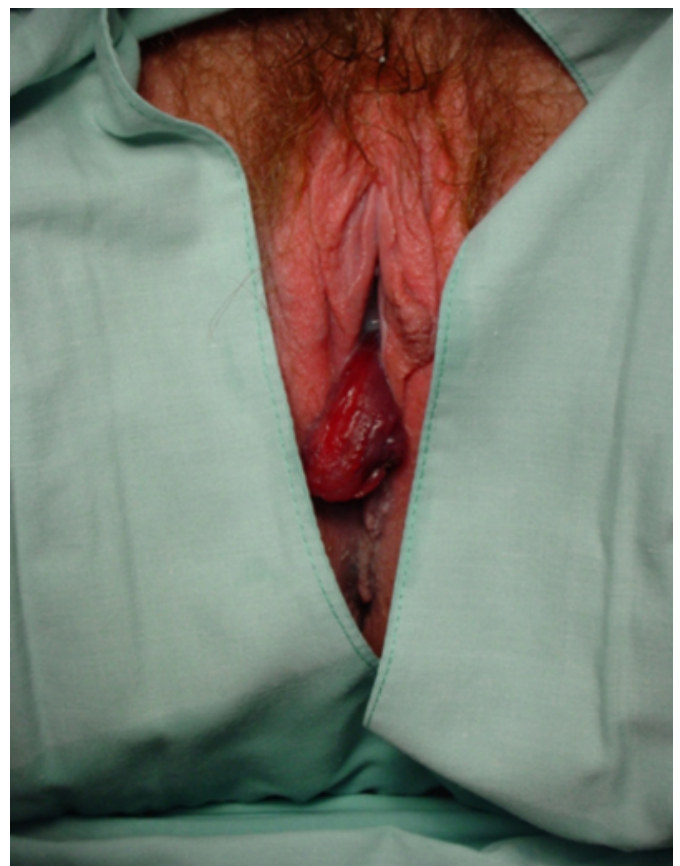


Figure 2

Photo II: Pedunculated polyp protruded out of the vagina

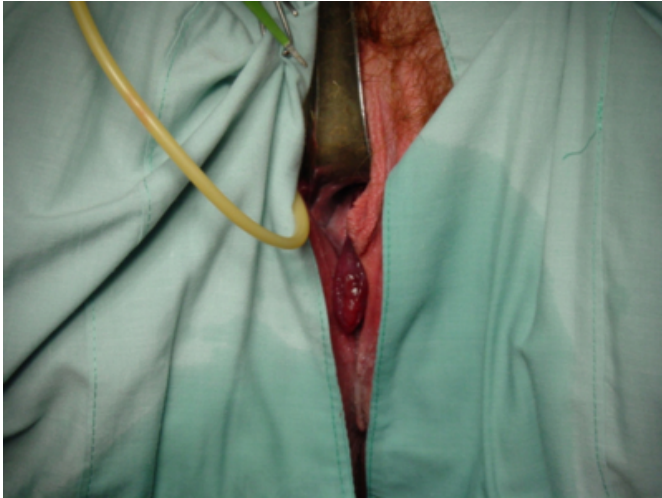


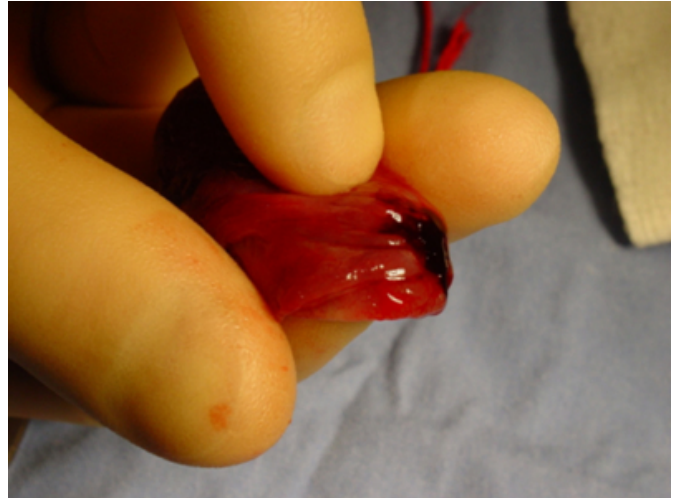
Figure 3

Photo III: Polyp after removal

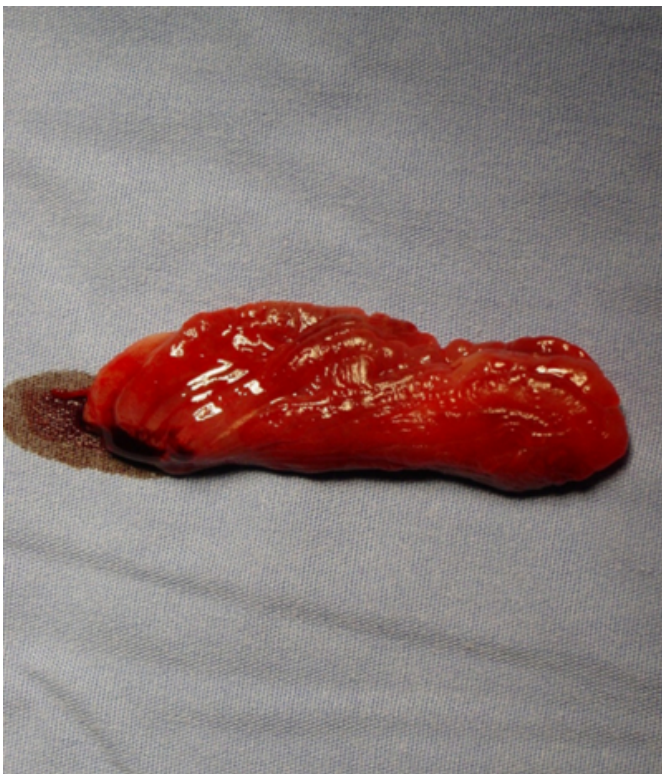

Figure 4

Photo IV: Detail of the polyp after removal, stalk



CONCLUSION

In our best knowledge there is no description or papers studying the effect of pedunculated polyp and the overall pregnancy duration. There is limited data about the cervical molecular changing with presence of polyp. It is accepted that such types of polyps do not usually provoke problems during labour and do not influence the overall dilation of the cervix. It is important to notice that there are no papers or studies done the last two decades confirming these empirical beliefs. Despite the benign nature of the cervical polyps during pregnancy, careful examination is mandatory to exclude malignancy and appropriate counselling and reassurance must be given to the pregnant woman.

CORRESPONDENCE TO

costapan@hotmail.com

References

1. The relation between granulocyte elastase activity in cervical mucus and gestational cervical polyp Kanayama N, Terao T. Nippon Sanka Fujinka Gakkai Zasshi. 1991 Jan
2. Pseudo-sarcoma botryoides of cervix and vagina in pregnancy Elliott GB, Reynolds HA, Fidler HK J Obstet Gynaecol Br Commonw. 1967 Oct; 74(5): 728-33.
3. Cervical polyp presenting as inevitable abortion Adinma JJ. Trop Doct. 1989 Oct; 19(4): 181
4. Vaginal bleeding and premature contractions during pregnancy in uterus bicornis with expulsion of a decidual polyp Schiessl B, Hantschmann P, Brucker C Gynakol Geburtshilfliche Rundsch. 2000; 40(3-4): 163-4.
5. Spontaneous expulsion of decidualized pseudopolyps in pregnant women with uterine malformation. Gangemi O, Petrone M, Crivelli F. Clin Exp Obstet Gynecol. 1987; 14(2): 113-5

Author Information

Costas Panayotidis

Department of Obstetrics and Gynaecology, Wythenshawe Hospital, South Manchester University Hospitals

A. Alhuwalia

Department of Obstetrics and Gynaecology, Wythenshawe Hospital, South Manchester University Hospitals