

Filarial Chylous Ascites With Chylothorax: Successfully Treated With Diethylcarbamazine, Doxycycline and Octreotide

V Chewoolkar, L Bachile, N Jain

Citation

V Chewoolkar, L Bachile, N Jain. *Filarial Chylous Ascites With Chylothorax: Successfully Treated With Diethylcarbamazine, Doxycycline and Octreotide*. The Internet Journal of Infectious Diseases. 2007 Volume 6 Number 2.

Abstract

Lymphatic filariasis is a common disease in the tropical and sub-tropical areas of the world. Lymphatic obstruction and the associated complications caused by the adult worms is an important cause of morbidity and cosmetic disfigurement. Most of these patients require shunt surgery to divert lymph flow. We report a patient who came to us with chylous ascites with chylothorax secondary to lymphatic filariasis. Surgical treatment was deferred in view of very poor nutritional status. This patient was successfully managed with Diethylcarbamazine, Doxycycline and Octreotide without any surgical intervention thereby highlighting the need for an aggressive medical management of patients who are unlikely to tolerate surgery.

CASE REPORT

A 22 year old female, resident of Mumbai, India, was referred to us with abdominal distension and breathlessness at rest since 14 days and intermittent fever with dry cough since 10 days. On examination, patient was febrile, cachexic with normal pulse and blood pressure. There was no neck vein distension. She had firm, discrete inguinal lymphadenopathy and pitting bipedal oedema. Her breath sounds were not audible in the right mid and lower zones. She had a tense ascites. Her hemoglobin level was 11.5 gm%, WBC count-8600/cumm with polymorphs-74%, eosinophils-13%, lymphocytes-13 %, adequate platelets. Her X-ray chest showed a massive right sided pleural effusion. Liver function tests, serum creatinine and electrolytes were normal. Urine examination was normal. Ultrasound of the abdomen showed massive ascites with normal liver and spleen. The ascitic fluid was milky in appearance (Figure 1) with proteins-6.3 gm%, 90 leucocytes with lymphocytes-86%, polymorphs-14% and no acid fast bacilli, other organisms or malignant cells. The pleural fluid was also milky and showed proteins-7.9 gm%, sugar-119 mg/dl, 80 leucocytes with 90% lymphocytes and 10% polymorphs with fair number of red blood cells in both.

Figure 1


Figure 1: Chylous ascitic fluid



CT scan of the chest, abdomen and pelvis showed a massive right pleural effusion with massive ascites. A fine needle aspiration of the inguinal lymph node showed reactive lymphadenitis. Serum triglycerides were 71mg/dl(65-180),cholesterol-156 mg/dl (150-250),high density lipoproteins-44 mg/dl (30-80),low density lipoproteins-97.8 mg/dl (90-160),very low density lipoproteins-14.2(14-15) . The ascitic fluid showed triglycerides - 203mg/dl, cholesterol-66mg/dl. With a strong suspicion of lymphatic filariasis, a peripheral smear was collected for microfilaria which turned out to be positive, species being W.Bancrofti. A smear of the ascitic and pleural fluid (Figure2) also showed positive for microfilaria of the same species.

Figure 2

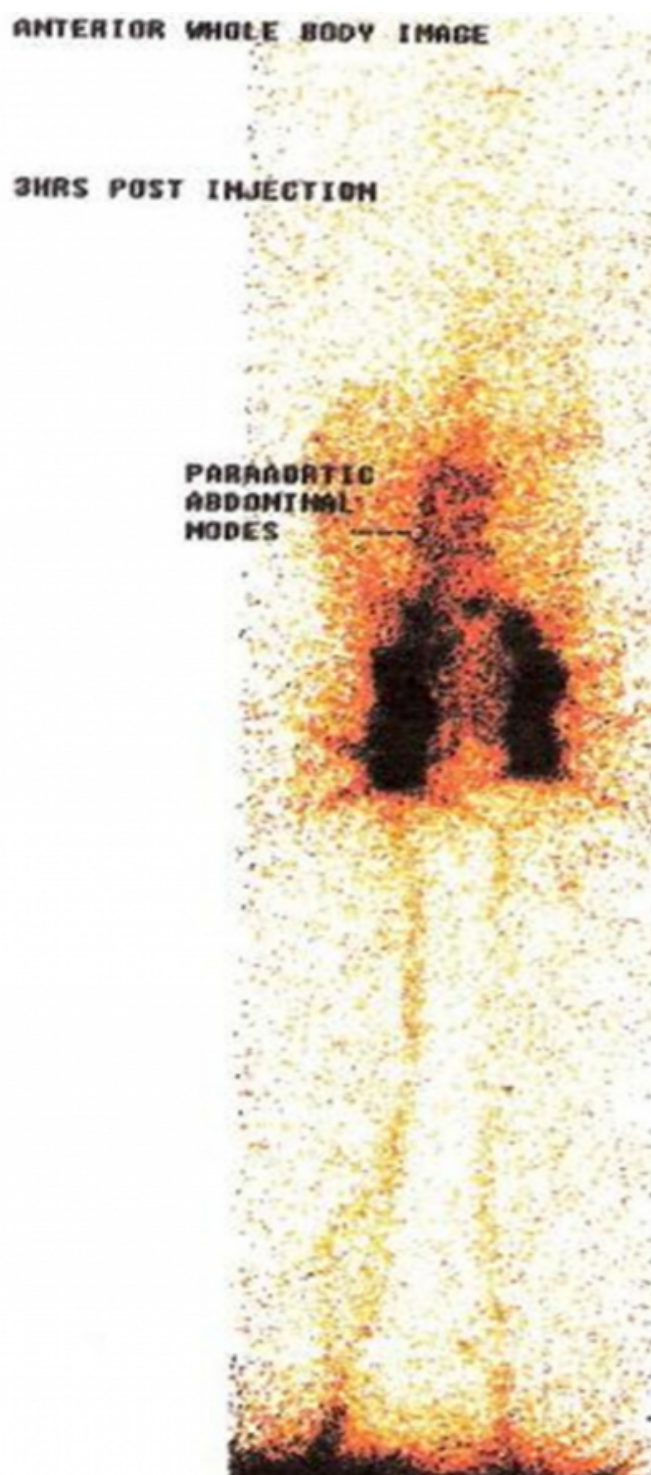Figure 2: Giemsa stained smear of pleural fluid showing microfilaria of species W.Bancrofti.



A lymphoscintigraphy showed a hold up of the tracer at the level of paraaortic lymph nodes with non visualisation of the abdominal lymphatic duct. A delayed film after a gap of 24 hours again failed to show the abdominal lymphatics with collection of the tracer in the peritoneal cavity (Figure 3).

Figure 3

Figure 3: Lymphoscintigraphy showing a hold up of the tracer at the level of paraaortic lymph nodes with collection of the tracer in the peritoneal cavity.



Patient was started on Diethylcarbamazine (DEC) 300mg/day in 3 divided doses with pheniramine and hydrocortisone followed by a therapeutic pleural and ascitic tapping. An oral diet containing lipids in the form of

medium chain triglycerides(coconut oil) and fat soluble vitamin supplements was started which patient tolerated very well. A repeat smear after seven days of treatment was still positive and abdominal distension increased. A surgical opinion was sought for a shunt surgery. It was however deferred as the patients nutritional status was very poor and the risk of post-surgical complications was high.

Doxycycline was started at 200mg/day with Inj.Octreotide (100 micrograms) eight hourly subcutaneously. DEC was continued. The ascites gradually decreased and a repeat peripheral as well as ascitic fluid smear after fourteen days was negative. Octreotide was given for two weeks. Other drugs were continued for six weeks. After six weeks, clinically patient had minimal abdominal fluid, a clear chest and no fever. A repeat X-ray chest was normal and ultrasound showed only minimal amount of ascitic fluid. A repeat assessment done at eight weeks after the course of Octreotide showed no significant increase in the abdominal free fluid.

DISCUSSION

Human lymphatic filariasis is caused by infections with *W. bancrofti*, *Brugia malayi*, or *Brugia timori*. These parasites are found in many tropical and subtropical areas of the world. Most infections are asymptomatic, but the living adult worm causes progressive lymphatic vessel dilation and dysfunction¹. Lymphatic dysfunction may lead to lymphedema of the leg, scrotum, penis, arm, or breast, which can increase in severity as a result of recurrent secondary bacterial infections^{2,3}. Tropical pulmonary eosinophilia is a potentially serious progressive lung disease with nocturnal cough, wheezing, and fever, resulting from immune hyperresponsiveness to microfilariae in the pulmonary capillaries.

The adult worms live in the lymphatics and can cause lymphangiectasia by obstructing lymph flow. Filariasis is the most common cause of acquired lymphedema in the world⁴. The diagnosis is made by identifying microfilariae on a Giemsa stained thick blood film. Blood must be drawn at night, since the microfilaria circulates at night, when their vector, the mosquito, is most likely to bite. There are also PCR assays available for making the diagnosis.

Diethylcarbamazine is used mainly as a microfilaricide even though it does have macrofilaricidal properties. It is usually effective in treating Tropical Pulmonary Eosinophilia (TPE) and its mechanism of action is thought to involve sensitizing the microfilariae to phagocytosis. For chronic manifestations

of lymphatic filariasis, such as lymphedema and hydrocele, specific lymphedema treatment (including hygiene, skin care, physiotherapy, and in some cases, antibiotics) and surgical repair, respectively, are recommended⁵. Doxycycline is a new drug for reducing microfilaria burden as it depletes the Wolbachia symbionts from *W. bancrofti*⁵. Somatostatin administration reduced lymphorrhagia from a ruptured thoracic duct⁶, and Raimondi et al.⁷, described a long-term remission of post-traumatic chyluria following 7 days of intravenous somatostatin infusion. However, the short half-life of somatostatin limits its use to intravenous continuous infusion only. Octreotide is an octapeptide synthetic somatostatin analogue with a circulating half-life of about 2 h₈. Thus it can be administered subcutaneously every 8 h with a less pronounced effect on glucose metabolism. The mechanism of action of octreotide is at present unknown. However, evidence for a role of Somatostatin in lipid homeostasis has been reported⁹. In dogs, somatostatin administration reduces lymph flow in the thoracic duct and may as well reduce chylomicron synthesis and transport¹⁰. Nakabayashi et al.¹⁰ reported a relationship between the reduction of lymph flow through the thoracic duct and the dose of somatostatin administered. As there are no specific guidelines as far as dose and duration of Octreotide is concerned in patients with chylous ascites, we chose the optimum, tolerable and affordable dose for our patient. Thus, Octreotide is a safe and effective therapy for chylous ascites and may represent a valid alternative to surgical intervention in patients who are unlikely to tolerate surgery. As the long term outcome of our patient or similarly treated patients is not known, standard clinical trials with such an approach are required to lay down specific guidelines in future.

CORRESPONDENCE TO

Dr. Vaibhav Chewoolkar, Lecturer, Department Of Medicine, K.E.M. Hospital, Parel, Mumbai -12 E mail- drvaibhavc@yahoo.com Tel-022-24126766 Parel,Mumbai-12

References

1. Dreyer G, Addiss D, Roberts J, Noroes J. Progression of lymphatic vessel dilatation in the presence of living adult *Wuchereria bancrofti*. *Trans R Soc Trop Med Hyg.* 2002; 96:157-61.
2. Dreyer G, Medeiros Z, Netto MJ, Leal NC, de Castro LG, Piessens WF. Acute attacks in the extremities of persons living in an area endemic for bancroftian filariasis: differentiation of two syndromes. *Trans R Soc Trop Med Hyg.* 1999; 93:413-7.
3. Shenoy RK, Suma TK, Rajan K, Kumaraswami V. Prevention of acute adenolymphangitis in brugian filariasis:

comparison of the efficacy of ivermectin and diethylcarbamazine, each combined with local treatment of the affected limb. *Ann Trop Med Parasitol.* 1998; 92:587-94.

4. Szuba A, Rockson SG. Lymphedema: classification, diagnosis and therapy. *Vasc Med* 1998; 3:145-156

5. Hoerauf A, Mand S, Fischer K, Kruppa T, Marfo-Debrekyei Y, Debrah AY, Pfarr KM, Adjei O, Büttner DW. Doxycycline as a novel strategy against bancroftian filariasis-depletion of Wolbachia endosymbionts from *Wuchereria bancrofti* and stop of microfilaria production. *Med Microbiol Immunol.* 2003 Nov; 192(4):211-6.

6. Ulibarri JL, Sanz Y, Fuentes C, Mancha A, Aramendia M,

Sanchez S. Reduction of lymphorrhagia from ruptured thoracic duct by somatostatin. *Lancet* 1990; 28: 258

7. Raimondi C, Dalmastrì V, Sestigiani E et al.: Post-traumatic chyluria treated with somatostatin. *Gin It Nefrol* 1994; 5:423-426

8. Katz MD, Erstad BL. Octreotide, a new somatostatin analogue. *Clin Pharm* 1989; 8: 255-273

9. Schusdziarra V, Harris V et al. Evidence for a role of splanchnic SST in the homeostasis of ingested nutrients. *Endocrinology* 1979; 104: 1705-1708

10. Nakabayashi H et al. Effects of SST on the flow rate and triglyceride levels of thoracic duct lymph in normal and vagotomized dogs. *Diabetes* 1981; 30: 440-445

Author Information

Vaibhav Chewolkar, MD

Lecturer, Department of Medicine, Seth G. S. Medical College and KEM Hospital

Lata S. Bachile, MD

Professor and Head, Department of Medicine, Seth G. S. Medical College and KEM Hospital

Neeraj Jain, MD

Observer, Department of Medicine, Seth G. S. Medical College and KEM Hospital