

# Multiple skin nodules as presenting feature of lymphoblastic lymphoma: a diagnostic dilemma

O Femi, P Nikila, T Sriramulu, T Mary

## Citation

O Femi, P Nikila, T Sriramulu, T Mary. *Multiple skin nodules as presenting feature of lymphoblastic lymphoma: a diagnostic dilemma*. The Internet Journal of Pediatrics and Neonatology. 2008 Volume 9 Number 2.

## Abstract

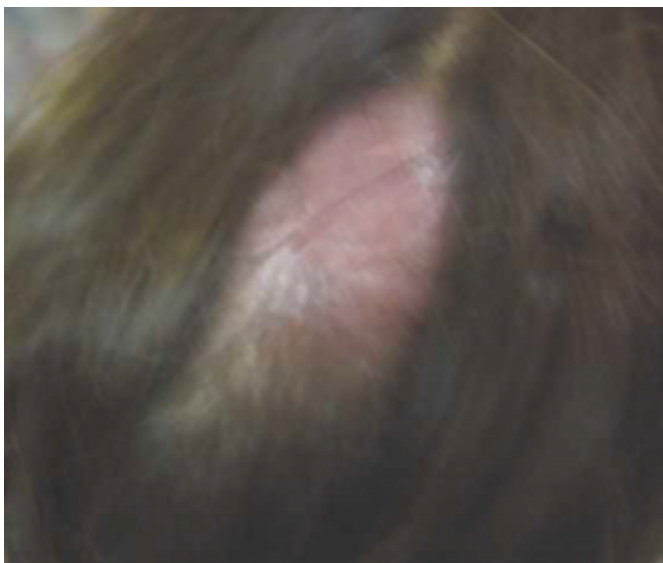Cutaneous manifestations of malignancies in children are not uncommon. A thirteen year old girl presented with multiple skin nodules on the scalp, face and trunk. Histopathology established the diagnosis of T cell lymphoblastic lymphoma. This case is being presented for its rarity and clinical interest.

## CASE REPORT

A 13 year old girl presented with multiple nodular lesions over her scalp and plaques of violaceous discolouration over her chest and face. She was otherwise well and had no constitutional symptoms. On examination she was afebrile, had no enlarged lymph nodes and abdominal examination showed no hepatosplenomegaly. She had multiple nodules over the scalp, hyper pigmented, violaceous, non tender, rubbery-firm in consistency and measuring about 2-4cm. There were similar lesions on the chest and abdomen (figure 1,2).

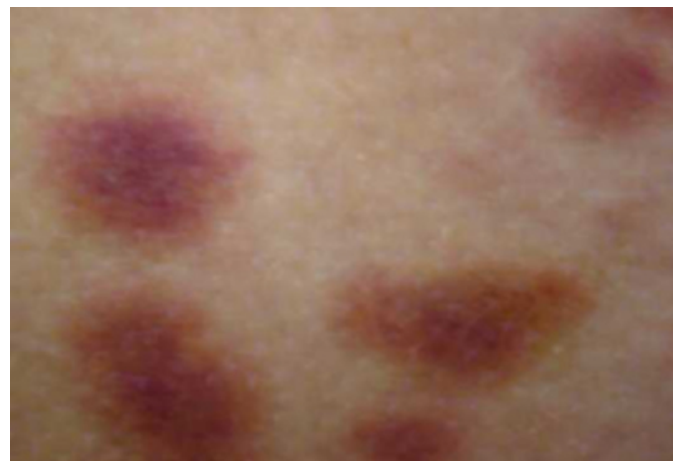### Figure 1

Figure 1: Lump on scalp



### Figure 2

Figure 2: Lesions on skin

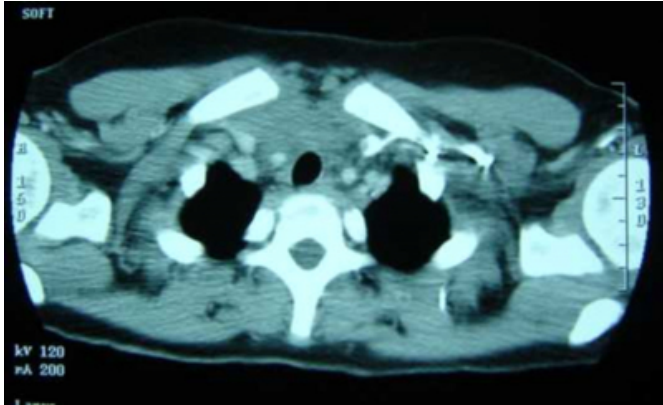


Her full blood count and biochemistry were normal except for a raised LDH level of 525. {Normal <300} X-ray chest revealed widened mediastinum.

CT scan showed lymphomatous deposits in the anterior mediastinum and liver (figure 3,4).

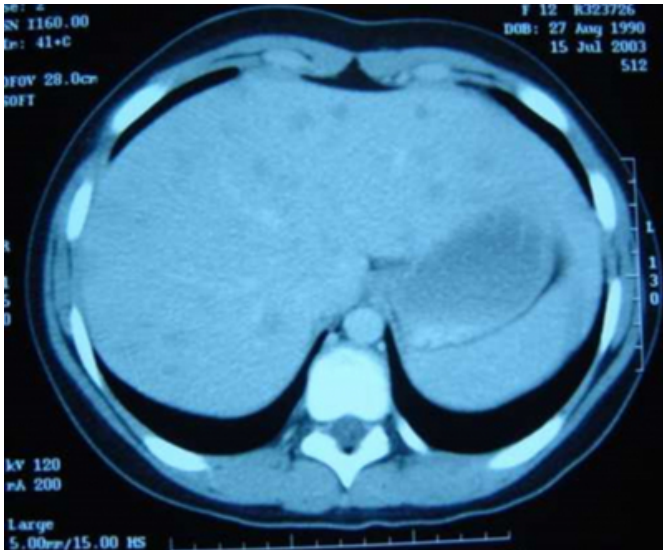
**Figure 3**

Figure 3: Mediastinal lymph nodes, No tracheal compromise



**Figure 4**

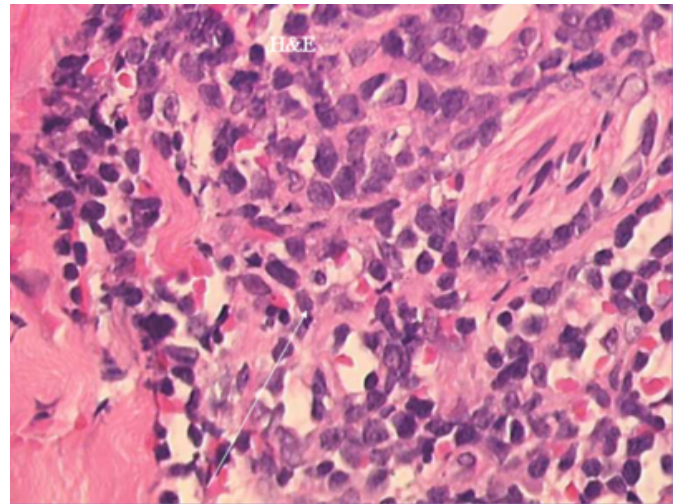
Figure 4: CT scan with lymphomatous infiltrates in liver



Skin biopsy showed a patchy dermal infiltrate of lymphoid cells that have scanty cytoplasm indented nuclei and granular chromatin. These cells were positive for CD3, CD4, CD8, tdt and CD10. They expressed CD79a and were weakly positive for CD5. A diagnosis of T cell lymphoblastic lymphoma was confirmed.

**Figure 5**

Figure 5: Biopsy of skin lesion showing Lymphoblastic infiltration



She has been treated with chemotherapy on the MRC ALL 97/01 protocol Regimen B for a total of 2 years and 2 months and finished treatment Oct 2005. Despite her unusual presentation she responded well to treatment and remains in remission at the present time.

## DISCUSSION

Non Hodgkin Lymphoma represents 4-6% of all malignant neoplastic disease of childhood. Paediatric non-Hodgkin lymphomas differ from adult disease in that they are almost all high grade, have a diffuse growth pattern and commonly involve extra nodal sites.<sup>1</sup>

Majority of cases fall into one of three diagnostic groups: Burkitts lymphoma; lymphoblastic lymphoma and anaplastic large cell lymphoma.<sup>1</sup>

Cutaneous involvement in lymphoblastic lymphoma (LBL) has been described. In one series, 1.8% of paediatric patients with ALL or LBL presented with skin lesions before diagnosis of haematological malignancy or simultaneously.<sup>2</sup> However cutaneous infiltration is more common in B cell lineage lymphoblastic lymphoma.<sup>2</sup> The commonest sites of presentation of cutaneous LBL have been described as the head and neck area.<sup>3</sup> Involvement of the back and generalised tumours can occur.<sup>4</sup> A further 3 cases of T cell lymphoblastic Lymphoma presenting with cutaneous lesions have been described in the literature.<sup>4,5</sup> Our index case presented with an initial skin lesion before progressing rapidly to involve the scalp, chest, and abdomen and was T cell in origin rather than B cell.

It is also important because the patient had no clinical features of a T cell Lymphoma and was thought to be a skin condition till the biopsy was done.

Since the cutaneous lesions are part of a generalised systemic aggressive disease treatment is with chemotherapy on Leukaemia/lymphoma protocols. Prognosis of patients who present with cutaneous infiltration is still uncertain (due to its rarity), although there is evidence to suggest that this condition is highly curable despite dissemination at presentation<sub>6</sub>. The index case continues to make excellent progress with complete resolution of scalp and cutaneous lesions.

### **CORRESPONDENCE TO**

Dr Nikila Pandya Consultant Paediatrician, Maidstone hospital, Hermitage lane, Maidstone ME16 9QQ Email

npandya2@nhs.net Fax no 01622224495

### **References**

1. Wright Dennis, McKeever Patricia, Carter Richard et al. Childhood non-Hodgkin's Lymphoma in the United Kingdom. Findings from UK Children's Cancer Study group. *Journal of Clinical Pathology* 1997; 50 (2): 128-135.
2. Millot Richard, Robert Alain et al. Cutaneous involvement in Children with Acute Lymphoblastic leukaemia or Lymphoblastic lymphoma. *Pediatrics* 1997 ;100 : 60-64.
3. Zataari G.S, Chan-W-C et al. Malignant Lymphoma of the Skin in Children. *Cancer* 1987: vol. 59(5); 1040-45
4. Chiment S, Fink-Puches-R et al. Cutaneous Involvement in Lymphoblast Lymphoma *Journal of Cutaneous Pathology* 1999; vol.26(8): 379-85.
5. Sander CA, Medeiros LJ, Abruzzo LV, Horak ID, Jaffe ES. Lymphoblastic Lymphoma presenting in cutaneous sites. A clinicopathological analysis of 6 cases. *J Am Acad Dermatol*. 1991 Dec; 25 (6 Pt 1): 1023-31.
6. Wollner-N, Lindsley-K-L et al. Primary peripheral nodal lymphoma in children. *Cancer* 1993, vol. 71, (11): 3670-9

**Author Information**

**Ogunbona Femi**

Department of paediatrics, Maidstone hospital

**Pandya Nikila**

Department of paediatrics, Maidstone hospital

**Tharakaram Sriramulu**

Department of Dermatology, Maidstone and Tunbridge wells NHS trust

**Taj Mary**

Department of Paediatric Oncology, Royal Marsden hospital