

Flexor Hallucis Longus Tendon: An Unexpected Location For A Foreign Body

O Kayiran, R Baris, U Kocer

Citation

O Kayiran, R Baris, U Kocer. *Flexor Hallucis Longus Tendon: An Unexpected Location For A Foreign Body*. The Internet Journal of Plastic Surgery. 2008 Volume 6 Number 1.

Abstract

Foreign bodies may cause chronic mild pain during their presence. Since then, it may not be the only symptom, but supplementary signs may be contributed with it such as ambulatory pain. Here, a case comprised of a foreign body with unknown ethiology is presented. The foreign body was found within the tendon of the great toe. To achieve the proper diagnosis, a flouroscope was used intraoperatively.

PATIENT AND METHOD

A 33 year-old female patient applied to our out-patient clinic with chronic pain (approximately 2 years) on her left foot during ambulation. While examination, the only detected sign was suffering at the dorsiflexion position of the great toe. We could not observe either any traumatic or surgical scar wound on the left foot. Besides, the patient was unable to determine the possible reason for the pain such as an antecedent trauma. Next step included the plain radiography of the lower extremity showing a foreign body on the plantar side of the left foot. This examination revealed that the foreign body had an origin of a metal. According to the appropriate consultations and vaccination history, there was no need for a tetanus profilaction.

The plain roentgenogram clearly showed the location of the body which was situated on the plantar side of the left foot (Figure 1 and 2). A needle with two seperate pieces could easily be detected on the graphy. Because the anteroposterior and lateral plain radiographies could indicate two-dimensional image, an intraoperative flouroscope was used.

Figure 1

Figure 1: Anteroposterior X-ray clearly shows the foreign bodies on the plantar side of the foot but further radiological examination is needed to locate.

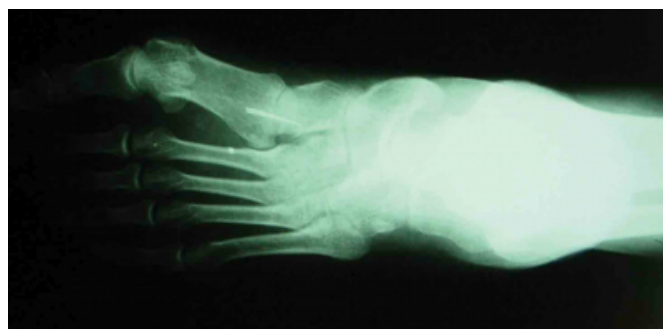
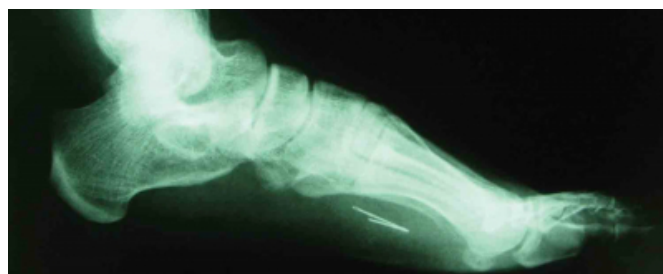

Figure 2

Figure 2: Lateral view of the roentgenogram.

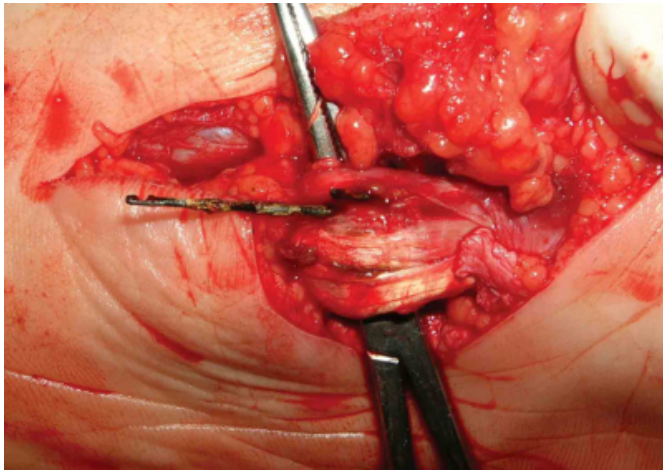


A zig-zag incision was made on the medial plantar side of the left foot. Under flouroscope, the dissection continued through the deeper planes. There were no evidence either for a foreign body reaction or a capsule formation peripherally. Finally, an unexpected location, flexor hallucis longus tendon, revealed the foreign body within it (Figure 3). After the removal of the foreign body, the appropriate hemostasis

and closure were carried out. In the postoperative period, no complications were recorded and the pain relief was established on the forthcoming days.

Figure 3

Figure 3: The foreign bodies within the tendon itself that were partially extracted for a better view. Note the minimal tendon reaction with no complication around.



DISCUSSION

The daily life encompasses various open traumas that may result with foreign body insertion, especially in undeveloped or developing countries. But, a few needs first aid.

There are few studies in the literature showing lower extremity foreign bodies, especially within the plantar side tendons [1]. This is the first case reported in which the foreign body is located not within the tendon sheath but in the plantar flexor tendon itself.

The previous reports revealed a predominance of upper extremity foreign bodies within tendon sheaths. The complication rates were also higher in this group [1]. Jozsa et al reported a broad series of intra-tendinous foreign bodies [1]. This study demonstrated 53 foreign bodies within 931 tendons in which upper extremity predominance was detected. According to that search, a foreign body in flexor hallucis longus was not reported either as a biopsy or autopsy material.

Most of the time, it is not for easy for the practitioner how to locate a foreign body within the tendon. It is globally believed to use X-ray first in traumatic patients. However, there are reports of detecting foreign bodies in the hand with ultrasonography [2345]. The practitioner shall choose the

appropriate diagnostic method, but in special circumstances such as the patients having pacemaker need further methods like sonography for the proper diagnosis. In selected patients, a dynamic method, fluoroscope, may be chosen for the exact location of the foreign body.

Flexor hallucis tendon originates from posterior aspect of the upper 1/3 fibula and inserts at the base of the distal phalanx of the great toe. The function of this muscle is to flex the great toe just like the ankle. This action makes the possible pain mechanism while stepping forward in our patient.

The foreign bodies in the tendons may be attributable with tendon ruptures, tendonitis, triggering, nodule formation, granuloma formation, tendon calcification, migration of the body within the tendon or sheath [1678910]. However, a great number of foreign bodies may astonishingly cause no symptoms or signs like as in our case [1].

In conclusion, it is still a debate for us with how the needle retained and moved forward silently within the tendon without a high-grade morbidity. In addition, the practitioners should be aware of the location possibility of a foreign body elsewhere in the foot proceeding subclinically with body movements.

References

1. Jozsa L, Reffy A, Demel S et al. Foreign bodies in tendons. J Hand Surg [Br]. 1989; 14 (1): 84-5.
2. Höglund M, Tordai P, Engkvist O. Ultrasonography for the diagnosis of soft tissue conditions in the hand. Scand J Plast Reconstr Hand Surg. 1991; 25: 225-31.
3. Fornage BD, Scherberg FL. Sonographic diagnosis of foreign bodies in the distal extremities. AJR. 1986; 147: 567-9.
4. McGeorge DD, McGeorge S. Diagnostic medical ultrasound in the management of hand injuries. J Hand Surg. 1990; 2: 256-61.
5. Gooding GAW, Hardiman T, Sumers M et al. Sonography of the hand and foot in foreign body detection. J Ultrasound Med. 1987; 6: 441-7.
6. Slodicka R, Mahfeld A, Otto W. An interesting case: late sequelae of a primary asymptomatic glass fragment injury of the wrist. Handchir Mikrochir Plast Chir. 1996; 28 (6): 306-8.
7. Jablon M, Rabin SI. Late flexor pollicis longus tendon rupture due to retained glass fragments. J Hand Surg [Am]. 1988; 13 (5): 713-6.
8. Freund EI, Weigl K. Foreign body granuloma. A cause of trigger thumb. J Hand Surg [Br]. 1984; 9 (2): 210.
9. Yang SS, Bear BJ, Weiland AJ. Rupture of the flexor pollicis longus tendon after 30 years due to migration of a retained foreign body. J Hand Surg [Br]. 1995; 20 (6): 803-5.
10. Myskiw PM, Pattinian HR, Ricken JA et al. J Am Podiatry Assoc. 1978; 68 (11): 759-65.

Author Information

Oguz Kayiran

Specialist, Ankara Training and Research Hospital, 1st Plastic and Reconstructive Surgery Clinic

Ruser Baris

Resident, Ankara Training and Research Hospital, 1st Plastic and Reconstructive Surgery Clinic

Ugur Kocer

Professor, Ankara Training and Research Hospital, 1st Plastic and Reconstructive Surgery Clinic