

Minimally Invasive Technique For The Management Of Communitated Fracture Of The Tarsal Navicular Bone

A Pendse, S Al-Naser, A Khurana, N James, A Gadgil, H Fanarof

Citation

A Pendse, S Al-Naser, A Khurana, N James, A Gadgil, H Fanarof. *Minimally Invasive Technique For The Management Of Communitated Fracture Of The Tarsal Navicular Bone*. The Internet Journal of Orthopedic Surgery. 2006 Volume 5 Number 1.

Abstract

Closed fracture dislocation of navicular is a rare injury. All 8 reports in the current literature, which we could find, describe treatment by open reduction and internal fixation of this injury. In this case report we describe how this injury was managed successfully by closed reduction using ligamentotaxis with an external fixator and supplemented by percutaneous internal fixation of the fracture of the navicular.

BACKGROUND

Mid-tarsal fracture dislocation is an inexact term used to describe a variety of lesions of the tarsal navicular bone [1].

Displaced fracture of the navicular is a rare injury. Additionally isolated disruption of the talo-navicular joint without subtalar dislocation or injury to the calcaneo-cuboid joint is also a rare phenomenon [2].

Sangeorzan & colleagues have classified Navicular body fractures into 3 types [3].

Type 1: A coronal fracture line with displaced dorsal fragment.

Type 2: Sagittal fracture line with a dorsomedially displaced fragment.

Type 3: Abduction injuries resulting in central or lateral comminution of the navicular body, these type of injuries are also associated with disruption of the naviculo-cuneiform and calcaneo-cuboid joint.

All the reports of these injuries describe management by open reduction and internal fixation.

Type 1 fractures are approached by longitudinal anteromedial incision.

Type 2 fractures are approached by longitudinal midaxial dorsomedial incision.

Type 3 fractures are approached by two incisions; an

anteromedial standard incision and a mid dorsolateral approach [4]. Variety of implants such as 2.7 mm screws, 2.4 mm miniplates, 2.0 mm mini and t-plates or k wires have been used to stabilise these fractures after open reduction [4].

After extensive literature search we have not come across any reported case of severely communitated type-I navicular fracture which had a good outcome after percutaneous fixation method and we report one such case, which is an eye-opener to the fact that sometimes little is the best for such kind of injuries.

CASE PRESENTATION

A 53 year old lady was referred via emergency department with a swollen, painful and deformed foot 5 days following injury to her left foot after a fall from stairs.

Radiographs and CT scan showed burst fracture of the navicular with fracture of the medial and intermediate cuneiform and subluxation of the talo –navicular and naviculo-cuneiform joint (figures 1 & 2).

Figure (1) AP and Oblique view of left foot showing the fracture of the tarsal Navicular.

Legend: AP and oblique view of the left foot showing Type-1 fracture of the Navicular, with a subluxated talo-navicular and naviculo-cuneiform joint and an intact subtalar joint. This x-ray according to the Main & Jowett's classification would be classified as having axial loading and forced dorsiflexion as the mechanism of injury though in this

case it was axial loading and plantar flexion. Bringing out the shortcoming of Main & Jowett's classification system.

Figure 1

Figure 1: AP and Oblique view of left foot showing the fracture of the tarsal Navicular.

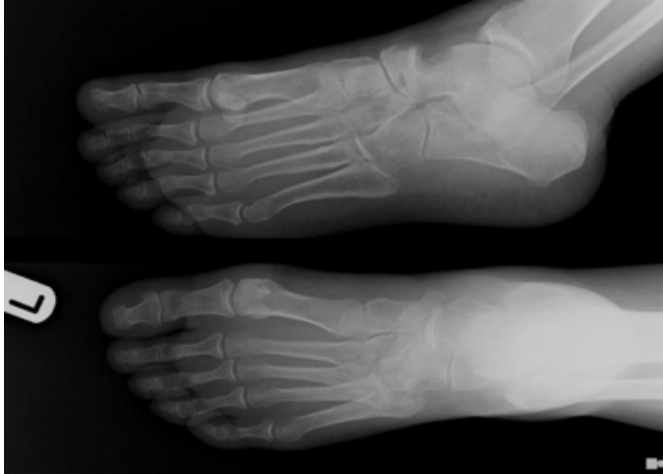
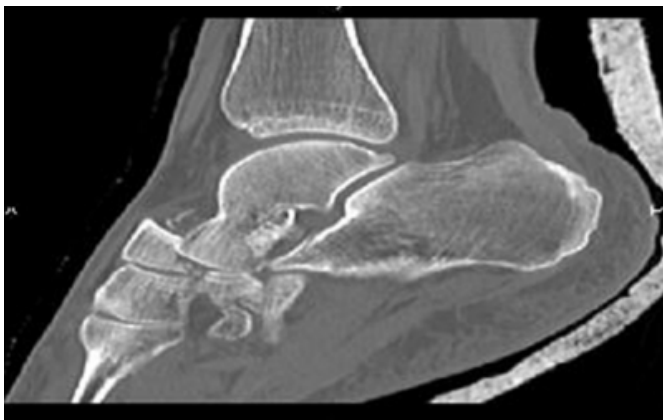
Figure 2

Figure 2: Saggital CT image of the left foot, showing the Navicular fracture.



Initial treatment consisted of admission, monitoring of compartment pressures in the foot and high elevation with a foot pump to reduce the swelling. Swelling began to subside after 48 hours as denoted by positive wrinkle sign at which time she underwent surgery, under general anaesthesia.

Closed reduction of the navicular was done by the principle of ligamentotaxis using a A.O. Minifix external fixator system. The major fragments were reduced into position under image intensifier control using a Mac-Dowell inserted through a 2 cm. incision over the dorsum of the foot centered on the navicular. A 4 mm cancellous screw was passed from the dorsal to volar aspect to hold the major fracture

fragments to provide additional stability and the external fixator was tightened (figures 3).

Figure (2) Title: Saggital CT image of the left foot, showing the Navicular fracture.

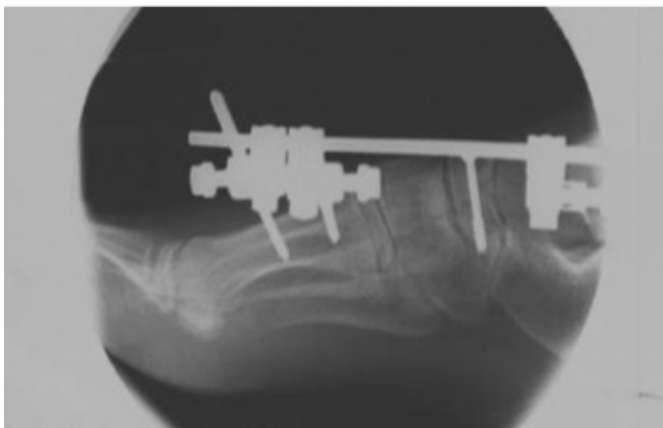
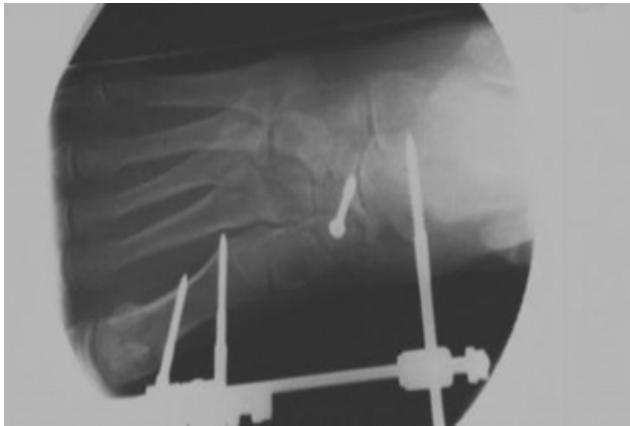Legend: Saggital CT scan image of the left foot showing tarsal navicular fracture with talonavicular and naviculo-cuneiform subluxation but intact subtalar joint. According to Keith Meister and Harry A. Demos such variety of fracture with isolated disruption of the talonavicular joint without subtalar dislocation or injury to the calcaneo-cuboid joint is quite a rare injury.

Figure (3) AP and Lateral post-operative films showing achievement of excellent articular reconstruction and alignment.

Legend: Post operative x-ray of the navicular fracture, showing excellent reconstruction of the joint surface and alignment obtained after reduction by ligamentotaxis using A.O. Minifix external fixator and 4.0 mm cancellous screw. It is surprisingly easy to obtain more than 60% articular reconstruction even in badly communitated fractures, thus avoiding primary arthrodesis, as achievement of 60% or more of the joint surface congruity is an indication for joint preservation as per Sangeorzan and colleagues.

Figure 3

Figure 3: AP and Lateral post-operative films showing achievement of excellent articular reconstruction and alignment.



The patient was discharged with a back slab and at 3 weeks time she was given a removable soft cast and ankle mobilisation begun. The external fixator was removed at 6 weeks and air-cast boot given with a rocker sole. Partial weight bearing started at 8 weeks. At 10 weeks she was allowed to full weight bear with use of air-cast boots & well-moulded rocker sole. At 13 months post operative the patient had good recovery with no collapse on the x-ray (figure 4).

Figure (4) X-rays of the foot at 13 months, showing good articular congruity and foot arches

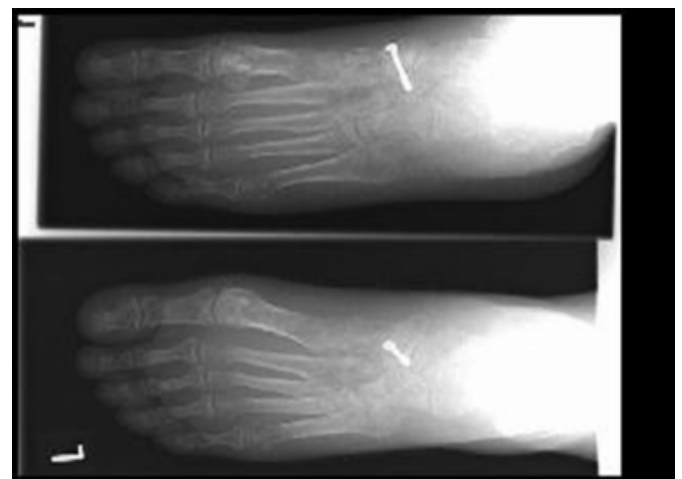
Legends: AP, lateral and oblique view of the left foot at 13 months of follow up showing maintenance of the articular congruity and alignment and preservation of the arch of the foot. Functionally the patient had good functional outcome though her range of inversion and eversion was significantly restricted.

Figure 4

Figure 4: X-rays of the foot at 13 months, showing good articular congruity and foot arches.

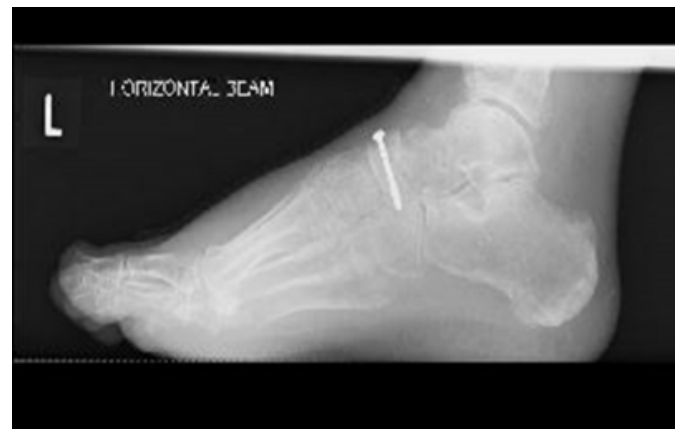

Figure 5



She had mild swelling over the mid foot but no pain at all. She had returned to her pre-trauma range of functions. However her eversion & inversion range was significantly restricted though it did not seem to affect her final functional outcome

DISCUSSION

The infrequency of this condition is due to the secureness of the bony, ligamentous and musculotendinous anatomy [4]. Freund 1989 has reported isolated dorsal dislocation of the navicular [7], though it is debatable as pointed out by R.Vaishya and J H Patrick 1991 [8]. A high-energy impact is required to disrupt and break the navicular.

According to Main and Jowett [5], radiologically, the mechanism of injury in this case would be axial loading and dorsiflexion; though in our case the mechanism was axial

loading and plantar flexion. This discrepancy in the Main & Jowetts classification for determining the injury forces from the x-rays is noteworthy and has been recognised once in the past [6].

The communitated fractures of Navicular are associated with traumatic arthritis and most authors have reported disappointing results with the same. Hence a variety of salvage operations have been described, including primary talonavicular fusion for severe communitation [9, 10].

Nowhere in the literature search have we found proponents for minimally invasive techniques for such kind of severely communitated injuries.

We believe first stage arthrodesis is an aggressive procedure. Undertaking extensive open procedures in the presence of compromised soft tissue often leads to wound complications and hence subsequent poor result. Also it has been reported that patients do well even in the presence of localised arthritis [5], potentially negating the need for a fusion.

Optimal reduction can often be achieved by ligamentotaxis for comminuted displaced intra articular fractures and maintained by an external fixator. Further stability can be added by percutaneous screw fixation of the major fragments.

Such treatment has been mentioned by DiGiovanni as akin to distraction arthroplasty [4].

AUTHORS' CONTRIBUTIONS

AP, AG and HF conceived the study and reviewed the patient's records. SA, NJ and AK were involved in the

literature search and helped in the compilation of the data. AP and AG formatted the final manuscript, which was reviewed and approved by all the authors.

ACKNOWLEDGEMENTS

Written consent was obtained from the patient for the publication of the study.

CORRESPONDENCE TO

Mr A. Pendse 15, Bellfield Avenue Cheadle Hulmes
Manchester SK8 7AG Email add.: adpendse@gmail.com
Tel. No.: 07716077923

References

1. C.A. Puente, M.D., J.P. Alaez, M.D., D.G. Marti, Ph.D.: Tarsal Fracture Dislocation with Plantar Dislocation of the Navicular: A case study. *Foot & Ankle International*, 1996, 17;2:111-113.
2. Keith Meister, MD, Harry A. Demos, MD: Fracture Dislocation of the Tarsal Navicular with Medial Column Disruption of the Foot. *Journal of foot and Ankle Surgery*, 1994, 33;2:135-137.
3. Sangeorzan, B.J., Benirschke, S.K., Mosca, V., Mayo, K. A., Hansen, S.T: Displaced intra-articular fractures of the tarsal navicular. *J. Bone Joint Surg.* 1989, 71A:1504-1510.
4. Christopher W., DiGiovanni: Fractures of the navicular. *Foot Ankle Clinics N. America* 2004, 9:25-63.
5. Main B.J. and Jowett R.L: Injuries of the midtarsal joint. *J. Bone Joint Surg.* 1975, 57B:89
6. L.A. Rymaszewski, J.E. Robb: Mechanism of fracture-dislocation of the navicular: brief report, *JBJS(Br.)* 1988, 70-B:492
7. Freund K. G: Isolated dislocation of the tarsal navicular. *Injury*. 1989, 20:117.
8. R. Vaishya and J. H. Patrick: Isolated dorsal fracture-dislocation of the tarsal navicular. *Injury*. 1991, 22;1: 47-48.
9. Eichenholtz SN, Levinne DB: Fractures of the tarsal navicular bone. *Clin Orthop* 1964, 34:142-157.
10. Watson-Jones R: Injuries of the foot. In: Wilson J.N. (ed.) *Fractures and Joint Injuries*, ed. 6, Vol. II. Edinburgh, London, New York: Churchill Livingstone 1982, p.1194.

Author Information

Aniruddha Pendse, MRCS, MS (Orthopaedics), MBBS
Senior House Officer, Orthopaedics, Edith Cavell Hospital

Saeed Al-Naser, MBBS
Senior House Officer, Orthopaedics, Prince Philip Hospital

Ashish Khurana, MRCS, MS (Orthopaedics), MBBS
Clinical Fellow Trauma, Royal Gwent Hospital

Nirmal James, MBBS
Senior House Officer, Orthopaedics, West Wales General Hospital

Aniruddha Gadgil, FRCS (Orthopaedics)
Consultant Foot and Ankle Surgeon, West Wales General Hospital and Prince Philip Hospital

H. Fanarof, FRCS (Orthopaedics)
Consultant Foot and Ankle Surgeon, West Wales General Hospital and Prince Philip Hospital