

# A NEW CAUSE OF AMBIGUOUS GENITALIA: MULTIPLE MALFORMATION SYNDROME RELATED TO AN UNBALANCED TRANSLOCATION [46,XY t(7;16)]

L Pavone, A Le Pira, M Caruso, P Pavone, O Palumbo, M Carella, T Mattina

## Citation

L Pavone, A Le Pira, M Caruso, P Pavone, O Palumbo, M Carella, T Mattina. *A NEW CAUSE OF AMBIGUOUS GENITALIA: MULTIPLE MALFORMATION SYNDROME RELATED TO AN UNBALANCED TRANSLOCATION [46,XY t(7;16)]*. The Internet Journal of Pediatrics and Neonatology. 2009 Volume 12 Number 2.

## Abstract

We report the case of a three years old male child who showed ambiguous genitalia in a setting of multiple malformations. Disorders of sex development (DSD) are due to many different causes, such as chromosome abnormalities, or alterations in transcription factors, receptors, and hormones implicated in sexual differentiation during fetal life. Here we describe a case of partial deletion 7q ter associated with partial trisomy 16p as a new chromosome anomaly associated with ambiguous genitalia. We have attempted to analyse the individual contributions of chromosomes 7 and 16 in the pathogenesis of the sex malformation in our patient.

## INTRODUCTION

There are many causes of ambiguous genitalia, recently renamed “disorders of sex development” (DSD). This generic definition includes any congenital condition in which the development of chromosomal, gonadal, and anatomic gender is atypical. Several conditions, such as sex chromosome abnormalities, and alterations in transcription factors, receptors, and hormones implicated in sexual differentiation during fetal life underlie disorders of sexual differentiation. Occasionally, complete or partial ambiguity of the genitalia is due to abnormalities of non-sex chromosomes.

Recently, we have evaluated a patient with multiple malformations and ambiguous genitalia in whom an unbalanced translocation [46,XY t(7;16)] was found.

## CASE REPORT

A 3-year-old male born by cesarean section after a 38-week gestation complicated by oligohydramnios and gestosis. He was the first born of healthy, non-consanguineous parents. The birth weight was 2,450 g (<3%), the length was 43 cm (<3%), and the cranial circumference was 30.5 cm (<3%). At birth, the child was initially considered female, with good Apgar scores (8 at 1 minute and 10 at 5 minutes). A few hours after birth, he was admitted to the Intensive Care Unit of the Department of Pediatrics at the University of Catania

(Italy) for diagnostic evaluation, where he was submitted to chromosomal analysis which revealed a male chromosome complement with an unbalanced translocation involving chromosomes 7 and 16. His karyotype was 46,XY t(7;16)mat. On physical examination, the child showed hypotonia, dysmorphic features, and ambiguous genitalia. He had undergone an ultrasound scan of the abdomen, which revealed relaxatio diaframmatica, and a heart ultrasound scan which revealed a ventricular septal defect and a patent foramen ovale. The hormonal evaluation at birth and at the age of 3 years is reported in Table 1.

The patient came to the Department of Pediatrics Clinic of the University of Catania (Italy) at the age of 2.5 years for a check-up. On physical examination, the child showed slight generalized hypotonia, and had a weak and feeble cry. Cognitive development was very poor. He showed ambiguous genitalia (Fig.1), bilateral syndactyly of the 2<sup>nd</sup> and 3<sup>rd</sup> toes, a soft palate cleft, facial dysmorphism (sloping forehead, eyebrows elevated and sparse, long eyelashes, blepharophimosis, down-pointing nose, small mouth, and retrognathia), and hands with tapering fingers. At the cardiac auscultation systolic murmur was present. The liver and spleen were within normal limits. The EEG showed spike-waves in the centre-temporal regions of the right hemisphere. Ultrasound scans of the pelvis showed the testes situated in the inguinal channel. A brain-MRI showed a

dysmorphic skull with marked expansion of the subarachnoid and subtentorial spaces, enlargement of the cisterna magna with pachygyria most evident in the left hemisphere, a slight asymmetric expansion of the lateral ventricles, and hypoplasia of the posterior horn of the corpus callosum. The angio-RM, ECG, and ophthalmologic consultation did not disclose pathologic findings. The echocardiograph showed small atrial septal defects, a patent foramen ovale with a left-to-right shunt at high velocity, and a small interventricular defect with a transeptal gradient of 32 mmHg. Impedancemetry (Ty plate) and otoemissions showed the absence of noise on the right and left sides, indicating moderate-to-severe hearing loss. He was admitted again at 3 years of age. During this period, he had frequent respiratory tract infections and convulsive attacks. Basal hormonal evaluation and HCG test (1000 UI/day for 4 days) were performed to assess androgen production and testicular function: the results were in the normal range (Table 1).

## CHROMOSOMAL FINDINGS

Chromosome analysis from peripheral blood lymphocytes was performed on the proband and his parents. The child had a derivative chromosome 7q+. The father had a normal phenotype and a normal 46, XY karyotype, while the mother had a normal phenotype and a balanced reciprocal translocation t(7;16) (Fig. 2). Therefore, the karyotype in the child was interpreted as follows:

46,XY,-7,+der7t(7;16)(7q36.06;16p11.2). The DNA study for the microdeletion of the Y chromosome was normal with respect to the molecular analysis carried out on the sex-determining region Y (SRY), azoospermia factor (AZF), and DAZ genes.

Array CGH was performed to refine the break points and to map the unbalances on chromosomes 16 and 7.

## MATERIALS AND METHODS

SNPs array analysis was performed using the Affymetrix Genome Wide Human SNP Array 6.0, which includes over 906,600 single nucleotide polymorphisms (SNPs) and more than 946,000 probes for the detection of copy number variation. Sample preparation, hybridization and scanning were performed using GeneChip® Instrument System hardware according to manufacturer's specifications (Affymetrix, Santa Clara, CA). Analysis was performed using the Affymetrix Genotyping Console 3.0.2 software and the sample met Affymetrix recommended values for Contrast QC (SNP) and MAPD QC (CNV). All aberrations

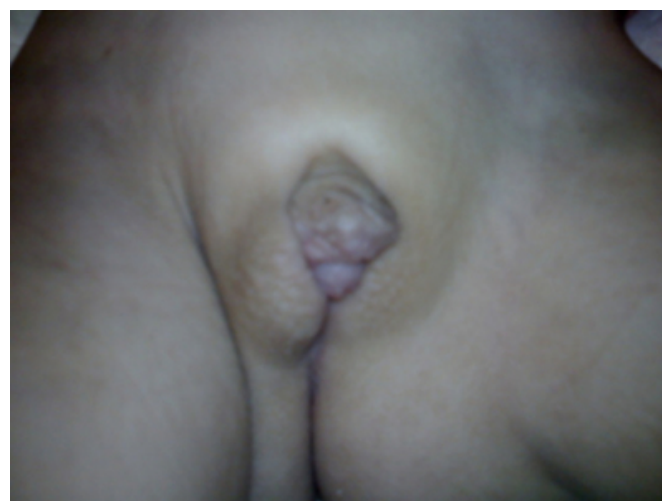
were calculated with respect to a set of 270 Hapmap normal individuals.

## RESULTS

Our results showed a 24Mb duplication of chromosome 16p with dup 16pter-p12.1 between marker CN\_724789 at chr16:765 and marker CN\_697870 at chr16:23917739 (UCSC genome browser, March 2006) (Fig. 3a), and a deletion of 1.5 Mb of chromosome 7q, with del 7q36.3-qter between marker CN\_1208658 at chr7:157287998 and marker CN\_1219560 at chr7:158812469 (Fig. 3b). The break point are, therefore different from those observed on standard chromosome analysis.

### Figure 1

Fig. 1 : Shawl scrotum and cryptorchidism.



### Figure 2

Fig. 2 : Partial karyotype showing the balanced translocation in the mother.



Figure 3

Fig. 3 : Graphic representation of copy number changes for chromosome 7 (a) and 16 (b) using Genotyping Console 3.0.2. Log2ratios values are plotted in blue while copy number state as predicted by the Hidden Markov Model is plotted in red.

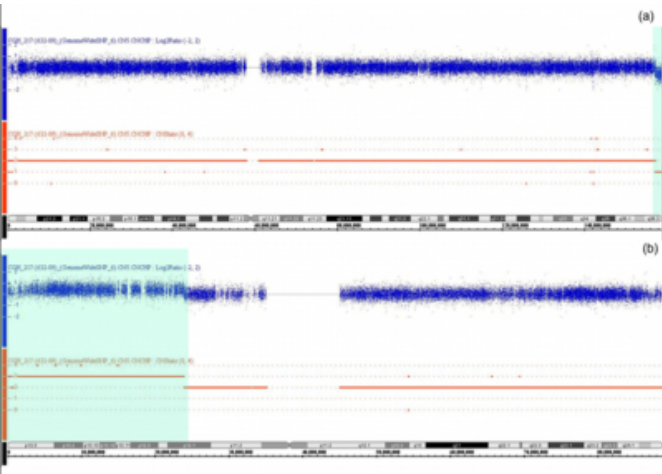


Figure 4

Table 1 : Hormonal evaluation at birth and at 3-years of age (normal values in parentheses)

Hormone	Birth	Three years of age
FT4	NP	16 pmol/l (12-22)
TSH	NP	2.18 mU/ml (0.27-4.20)
FSH	7.8 mIU/ml (0-4.5)	1.8 mIU/ml
LH	8.3 mIU/ml (0-1.5)	0.5 mIU/ml
Estradiol	NP	<5 pg/ml (6-27)
Prolactin	NP	294.3 uIU/ml (102-496)
17-OH-Progesterone	9.8 ng/ml (1.8-2.5)	0.3 ng/ml
Testosterone after HCG	0.01 ng/ml	0.02 ng/ml
DHT	0.5 ng/ml	NP
DHEA-S	0.4 µg/ml	0.06 µg/ml
Androstenedione	0.9 ng/ml	0.4 ng/ml
ACTH	32 pg/ml (30-120)	NP
Cortisol	169.05 ng/ml (90-180)	NP

NP = not performed

DISCUSSION

According to the recent nomenclature and classification proposed by the Chicago Consensus (1), there are three main categories of the now called DSD: sex chromosome DSD, 46,XY DSD and 46,XX DSD. Among 46,XY DSD, to which our patient belongs, are found: disorders of testicular

development; disorders in androgen synthesis or action and a third group named “other”, which include syndromic association of male genital development. In our patient, the male karyotype and the absence of microdeletion of the Y chromosome make unlikely the hypothesis of complete or partial testicular gonadal dysgenesis, although other genes, such as WT1, SOX9, SF1, besides SRY, are involved in testicular differentiation (2). Moreover, ultrasounds, basal and stimulated hormonal levels indicate the presence of functional testis with normal production of androgens, excluding as cause of the ambiguous genitalia a disorder of androgen synthesis, or Leyding cells agenesis or hypoplasia. However, we cannot exclude the diagnosis of partial peripheal resistance to androgens.

Clinically, the patient showed ambiguous genitalia in a setting of multiple malformations and chromosomal anomalies. Chromosomal abnormalities are associated with dysmorphic features, multiple congenital malformations, physical growth delay, and mental retardation syndromes. Cryptorchidism is frequently observed in male infants with chromosome anomalies. In contrast, ambiguous genitalia are rarely observed in children with chromosome anomalies, but most often in cases of sex chromosome mosaicism with contemporary presence of cell lines associated with female and male phenotypes, such as mos45X0/46XY or structural abnormalities of the chromosomes.

In this report, we have described a case of partial deletion 7q ter associated with partial trisomy 16p as a new chromosome anomaly associated with ambiguous genitalia. We have attempted to analyze the individual contributions of chromosomes 7 and 16 in the pathogenesis of the sex malformation in our patient.

While full trisomy 16 is apparently incompatible with life, it is certain that partial duplication 16p, reported in 41 literature cases, can result in liveborn infants with multiple congenital anomalies, including bilateral cryptorchidism (3). The most common anomalies associated with 16 p trisomy (4-7) include severe truncal hypotonia, lower-limb hyporreflexia, craniofacial anomalies (hypertelorism, dysmorphic ears, cleft palate, and a hypoplastic mandible), deformities of the fingers, dorsiflexion of the toes, a single umbilical artery, cardiac defects, and cryptorchidism. However in the 1975 report by Stern and Murch (8), an infant with pseudohermaphroditism showed an unbalanced translocation involving the short arm of chromosome 16 and the long arm of chromosome 18, leading to a partial deletion

18q and partial trisomy 16p. The patient had unusual facial features and female external genitalia with clitoral hypertrophy associated with other anomalies already described in trisomy 18 syndrome.

Analyzing the anomalies involved in chromosome 7, we have found that a terminal deletion (q36-qter) of this chromosome is associated with microcephaly, holoprosencephaly, delayed mental and physical development, facial anomalies (prominent forehead, cleft lip and palate, hypertelorism, and auricular malformations), short stature, and sacral dysgenesis (9), but no genital anomalies.

In our patient, it is difficult to recognize the individual role played by the two chromosomes involved in causing the genital anomalies. We suggest that the contemporary presence of a 16 p duplication and 7qter deletion was necessary in this case to cause sex development anomalies. A previous report (8) of unbalanced translocation with 16p partial trisomy and 18q partial deletion might suggest an important contribute provided by 16 p trisomy, which might be not sufficient, on its own, to cause DSD.

## ACKNOWLEDGEMENTS

The authors thank Dr O. Zuffardi, MD, University of Pavia, Italy, and Dr. F. De Luca, MD, University of Messina, Italy,

for helpful suggestions and critical review of the manuscript. There are no known potential conflicts of interest. We wish to thank the “International Science Editing”, Shannon, Ireland, UK (<http://www.internationalscienceediting.com>) for editing the final draft of the present manuscript.

## References

1. Hughes IA, Houk C, Ahmed SF et al. Consensus statement on management of intersex disorders. *Arch Dis Child* 2006;91:554-563.
2. DiNapoli L, Capel B. SRY and the standoff in sex determination. *Mol Endocrinol* 2008; 22:1-9.
3. Rochat MK, Riegel M, Schinzel AA. Long-term follow-up of a 26-year-old male with duplication of 16p: clinical report and review. *Am J Med Genet A*. 2007;143:399-408.
4. Pergament E, Pietra GC, Kadotani T, et al. A ring chromosome no. 16 in an infant with primary hypoparathyroidism. *J Pediatr* 1970;76:745-751.
5. Schmickel R, Poznanski A, Himebaugh J. 16q trisomy in a family with a balanced 15/16 translocation. *Birth Defects Orig Artic Ser*. 1975;11(5):229-36.
6. McMorro LE, Bornstein S, Fischer RH, et al. Partial trisomy 16p due to a maternal balanced translocation. *J Med Genet* 1984;21:315-316.
7. Carrasco Juan JL, Ciquodosa JC, Otero Gómez A, et al. De novo trisomy 16p. *Am J Med Genet* 1997;68:219-221.
8. Stern LM, Murch AR . Pseudohermaphroditism with clinical features of trisomy 18 in an infant trisomic for parts of chromosomes 16 and 18: 47,XY,der(18),t(16;18)-(p12;q11)mat. *J Med Genet* 1975;12:305-307.
9. Su PH, Chen JY, Chen SJ, et al. Sacral dysgenesis associated with terminal deletion of chromosome 7 (q36-qter). *Pediatr Neonatol* 2008;49:189-192.

**Author Information**

**L. Pavone, MD**

Department of Pediatrics, Unit of Clinical Pediatrics, University of Catania

**A. Le Pira**

Department of Pediatrics, Unit of Clinical Pediatrics, University of Catania

**M. Caruso, MD**

Pediatric Endocrinology, University of Catania

**P. Pavone, MD, PhD**

Department of Pediatrics, University Hospital "Vittorio Emanuele"

**O. Palumbo, PhD**

Medical genetics Unit, IRCCS Casa Sollievo della Sofferenza

**M. Carella, PhD**

Medical genetics Unit, IRCCS Casa Sollievo della Sofferenza

**T. Mattina, MD**

Genetic Clinics, University of Catania