

Epidemiological study of Mycotic Keratitis

V Sharma, M Purohit, S Vaidya

Citation

V Sharma, M Purohit, S Vaidya. *Epidemiological study of Mycotic Keratitis*. The Internet Journal of Ophthalmology and Visual Science. 2008 Volume 6 Number 2.

Abstract

Introduction: Mycotic ulcer is common in rural, remote, agricultural regions of India, where primary medical facilities are lacking. Diagnosis of causative fungus is usually not possible on the basis of available clinical and laboratory tests so the magnitude of mycotic keratitis is under-estimated as a factor of corneal blindness.

Purpose: To know the incidence of mycotic keratitis among the all corneal blindness cases along with predisposing factors,

Setup: Tertiary Care Center (Medical college hospital).

Material and Methods: We have included in the present study 201 consecutive cases of corneal ulcer attended hospital during April 2006 to November 2007. Diagnosis of mycotic keratitis was confirmed by history, clinical examination, direct microscopic examination of corneal scraping from the edge of ulcer for fungal hyphae and culture of fungus of corneal scraping and pus from anterior chamber, in different culture medias.

Results: 42 cases (20.9%) of fungal corneal ulcer were found to be positive by direct examination and / or by culture. Fungal hyphae were seen by wet mount KOH preparation in 34 (80.9%) and culture growth present in 37 (88.0%) cases. Patients who have both test positive were 31(73.8%). Out of 34 culture grown 23 (54.7%) had pure fungal growth while 14(45.3%) showed fungus with superadded bacterial infections. *Aspergillus fumigatus* was the commonest causal agent isolated from 12 cases (5.9%) followed by in order to frequency are *Aspergillus flavus* (3.9 %), *Candida* (4.48 %), *Curvularia* (2.98 %), *Penicillium* (2.49 %) and *Fusarium* species (1.0 %).

Conclusion: This study suggests that in all cases of corneal ulcer, corneal scraping is mandatory for early diagnosis of mycotic keratitis to prevent corneal blindness as there is a high incidence (20.9%) particularly in tropical agricultural regions.

INTRODUCTION

Ocular trauma and corneal ulceration are significant causes of corneal blindness that are often underreported but may be responsible for 1.5-2.0 million new cases of monocular blindness every year [1]. India is a tropical agricultural country having higher prevalence of fungal keratitis compared to European and other cold countries. It is one of the major causes of corneal blindness in this region because of difficulties to manage mycotic corneal ulcer in rural, remote and underprivileged areas; in wants of establishment of clinical diagnosis, isolating the etiologic fungal organism in the laboratory [2,3] and treating the keratitis effectively with available antifungal agents.

Moreover incidence of fungal keratitis has increased over the

past 30 years as a result of the frequent and prolonged injudicious use of topical corticosteroid and antibacterial agents in ophthalmic ailments and postoperatively [4,5], the rise in the number of patients who are immuno-compromised, and better laboratory diagnostic techniques that aid in its diagnosis. Most cases are associated with outdoor agriculture activities [6,7,8,9]. Trauma resulting from vegetation is the common predisposing factor [10], commoner in males than in females. Other causes are wearing of contact lens and foreign body in conjunctival sac.

Ocular fungal organisms are: Moniliaceae (non pigmented filamentary fungi, including *Fusarium* and *Aspergillus* species), Dematiaceae (pigmented filamentary fungi, including *Curvularia* and *Lasiodiplodia* species) and yeasts

(including *Candida* species).^{7,8,9,11}

The incidence of fungal keratitis varies according to geographical location. Internationally *Aspergillus* species is the most common isolate in fungal keratitis worldwide. Large series of fungal keratitis from India report that *Aspergillus* species is the most common isolate (27-64%), followed by *Fusarium* (6-32%) and *Penicillium* (2-29%) species.^{10,11}

This study includes consecutive 201 corneal ulcers cases treated in a period of sixteen months presented at Eye OPD with special focus on fungal infections.

MATERIALS AND METHOD

Total 201 consecutive corneal ulcer cases were studied for epidemiological and clinical study of mycotic keratitis who attended the department of ophthalmology, R.D.Gardi Medical College hospital. 42(20.9%) patients of fungal keratitis detected by detail history, clinical examination and laboratory investigations included. Along with the presenting symptoms a history taken whether resident of urban or rural area, occupation, working conditions, outdoor eye trauma, trauma caused by foreign body in eye, type of foreign body : organic or non- organic, and inquire about possible risk factors like contact lens wearing and prolonged use of cortisone.

Diagnosis of fungal corneal ulcer was done by clinical examination after recording visual acuity. Anterior segment examined by slit lamp for ciliary or mixed congestion, size and site of epithelial defect, margin of ulcer, texture, suppuration, deep stromal infiltration, pigmentation, associated endothelial plaque, neovascularization, satellite lesions, anterior chamber reaction, hypopyon and fluorescein staining of epithelial defects.

Corneal scrapings were taken. after instillation of proparacain 0.5% , using standard techniques under aseptic conditions from the edge of ulcer by blade No.15 on Bard Parker handle A.C. tap was done in cases of hypopyon and material obtained sent to laboratory for investigations.

Confirmation of mycotic lesion established by: 1. direct examination of mycelium in corneal scraping after KOH preparation 2. Fungus culture done of corneal scraping, and pus from anterior chamber in cases of hypopyon on suitable media

RESULTS

201 patients with clinical diagnosis of corneal ulcer with or

without hypopyon were enrolled for this study. Out of them 42 patients (20.9%) were confirmed to have fungal ulcer by direct examination of corneal scrapings and / or by fungal culture. Presenting symptoms were foreign body sensation, discomfort or pain in eye, decreased vision, hypersensitivity to light, redness, thick mucoid or muco-purulent discharge with history of trauma or foreign body in eye. 15 (7.5%) patients had non specific signs like ciliary injection, stromal infiltration, anterior chamber reaction, aqueous flare, keratic precipitates, hypopyon and positive fluorescein staining while 27(13.5%) patients had specific signs of mycotic keratitis like feathery margins of infiltrate, rough texture, raised borders, brown pigmentation and satellite lesions. A deep stromal infiltrate with an intact epithelium was present in 4 cases (2.0%).

RESULT

Figure 1

Table 1: Causative Factors

Causative Factor	Numbers of cases	Percentage
Soybeans foreign body	13	6.47%
Wheat foreign body	11	5.5%
Babul thorn	3	1.5%
Straw whiling sweeping	2	1.0%
Khad(organic fertilizer)	1	0.5%
Non-specific foreign body	9	4.8%
Contact lens	1	0.5%
Prolong use topical cortisone	1	0.5%
No specific history	1	0.5%
Total	42	20.9%

Out of 42 mycotic keratitis cases fungal hyphae were seen by wet mount KOH preparation in 34 (16.9%) and culture growth present in 37 (18.4%) cases. Patients who have both test positive were 31(15.4%). Out of 34 culture grown 23 (11.4%) had pure fungal growth while 14(6.9%) showed fungus with superadded bacterial infections.

Figure 2

Table 2: Results

Total corneal ulcer	201
Mycotic keratitis	42 (20.9%)
Fungal hyphae were seen	
- In Corneal scraping	34 (16.9%)
- in Culture growth	37 (18.4%)
- Both test positive	31 (15.4%)
Pure fungal growth	23 (11.5%)
Superadded bacterial infections	14 (06.9%)

A. fumigatus was the commonest causal agent isolated from twelve cases (5.97 %) and *A. flavus* in eight (3.98 %) cases. *Aspergillus* species was followed in order to frequency by *Candida* in nine (4.48 %), *Curvularia* in six (2.98 %), *Penicillium* in five (2.49 %) and *Fusarium* species in two (1.0 %).

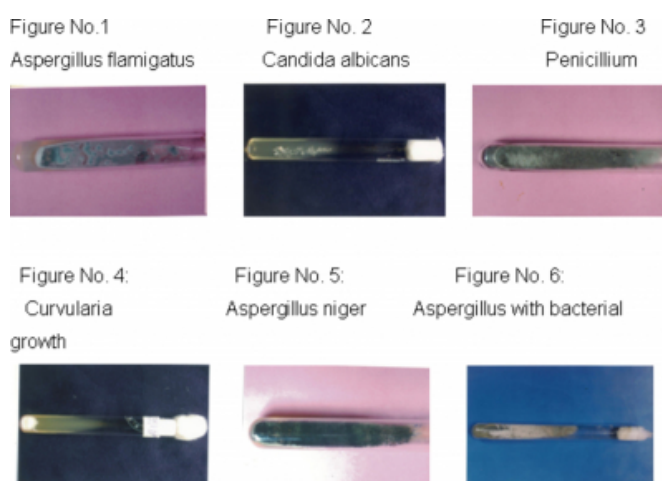Figure 3

Table 3: Species of fungus detected


Fungus species detected	Numbers of cases	Percentage
<i>Aspergillus fumigatus</i>	12	5.97 %
<i>Aspergillus flavus</i>	8	3.98 %
<i>Candida</i>	9	04.48 %
<i>Curvularia</i>	6	02.98 %
<i>Penicillium</i>	5	02.49%
<i>Fusarium</i>	2	01.0 %
Total	42	20.9%

Figure 4

Images of Fungus culture growth from corneal ulcer



Microphotograph of Fungus isolated from corneal scrapping / culture



The incidence was more in the age group 21-50 and the males were more affected. The maximal occurrence was seen in the post harvesting period of soybean (November) and wheat (March).

37(18.4%) patients were either farmers or manual laborers from rural agricultural areas and 34(16.9%) of them gave a definite history of antecedent corneal trauma due to vegetable or soil matter. 2 patients (1.0 %) were the chronic users of systemic corticosteroid for other ailments and got foreign body in eye. One patient from remote area used topical cortisone drops post-operatively after cataract surgery with IOL implant for 8 months, sutures were not removed and she presented with large corneal ulcer with endophthalmitis.

DISCUSSION

Even ½ mm enlargement of central corneal ulcer by stromal infiltration may obscure visual axis and reduces visual acuity drastically from 6/18 to F.C. 3 meters. Fast, intensive, effective treatment should be started as an emergency procedure. If diagnosis and treatment is delayed, ulcer spread in surrounding areas which may covers a large area and the ultimate opacity form after healing leads to blindness. No other treatment is available than keratoplasty for opacity, which is a cumbersome technique along with its

side effects and complications, at the same time there is always scarcity of donor's cornea and most of the time out of range to common person residing in a village. In this scenario it is better to heal ulcer as early as possible with all the possible tools available, making the scar as small as possible and trying to retain vision.

Primary mycotic keratitis does occur, but most mycotic keratitis is secondary to some form of trauma to the cornea^{9, 10}. In the present we detected antecedent history of injury or F.B in 38 (18.9%), out of which 29(14.4%) due to specific organic matter like thorn, seed-skin, stalk of wheat, soybeans or Babool depending on the harvesting seasons.

To diagnose a mycotic ulcer is not a Herculean job as hyphae can be easily detected in wet mount KOH preparation of corneal scrapping but diagnosis of specific type of fungal keratitis may be problematic because of the very small sample obtained by scraping the corneal ulcer and it takes 2-3 weeks for the fungus to grow in culture. So it is not of much help for the treating clinician.

Ocular fungal organisms are: Moniliaceae (non pigmented filamentary fungi, including *Fusarium* and *Aspergillus* species), Dematiaceae (pigmented filamentary fungi, including *Curvularia* and *Lasioidiplodia* species) and yeasts (including *Candida* species).^{7,8,9,11} On culture *Aspergillus fumigatus* was the commonest causal agent isolated from twelve cases (5.97 %) and *Aspergillus flavus* in eight (3.98 %) cases, *Candida* in nine (4.48 %), *Curvularia* in six (2.98 %), *Penicillium* in five (2.49 %) and *Fusarium* species in two (1.0 %) in our study.

CONCLUSIONS

The study concludes that fungal ulcer is an important cause of corneal blindness. A significant number : 20.9% in total cases of corneal ulcer were found due to fungus, which indicates that all precaution should be observed in taking history and clinical examination supplemented by investigations with a high suspicion in mind, in any case of corneal ulcer presented, particularly with a history of organic foreign body in eye.

CORRESPONDENCE TO

Dr. Virendra Kumar Sharma E-20 Rishi Nagar Ujjain 456
001 Madhya Pradesh (India) E-mail –
dr.virendra.k.sharma@gmail.com

References

1. Prajna NV, Rao RA, Mathen MM, Prajna L, George C, Srinivasan M. Simultaneous bilateral Fungal Keratitis caused by different fungi. *Indian J Ophthalmol* 2002; 50:213-214.
2. 1 Whitcher JP, Srinivasan M, Upadhyay MP. 1: Bull World Health Organ. 2001;79(3):214-21. Epub 2003 Jul 7
3. Deshapande SD, Koppikar GV. A study of Mycotic keratitis in Mumbai. *Indian J Pathol Microbiol* 1999; 42(1):81-87.
4. Kotigadde S, Ballal M, Jyothiratha, Kumar A, Rao SRN, Shivananda PG. Mycotic keratitis: A study in coastal Karnataka. *Indian J Ophthalmol* 1992; 40(1):31-33.
5. Venugopal GV, Venugopal TV, Gomathi A, Ramakrishna ES, Ilavarasi S. Mycotic keratitis in Madras. *Indian J Patho Microbiol* 1989; 32(3): 190-197
6. HOQUE, M. E.; HOSSAIN, A.; SALAHUDDIN, M.; BANU, F. A. Isolation of organism from hypopyon corneal ulcer Bangladesh Journal of Pathology 1992; 7(2): 33-37
7. John Stanford- Smith, Eye diseases in hot climates; fourth edition ELSEVIER, page 164
8. Brilliant LB, Pokhrel RP, Grasset NC, et al. Epidemiology of blindness in Nepal. *Bull World Health Organ* 1985; 63:375-86

Author Information

Virendra Kumar Sharma, M.S.

Associate Professor, Department Of Ophthalmology, R.D.Gardi Medical College Ujjain

Manju Purohit, M.D.

Associate Professor, Department of Pathology, R.D.Gardi Medical College Ujjain

Sudhakar Vaidya, D.L.O. D.N.B.

Associate Professor, Department of ENT, R.D.Gardi Medical College Ujjain