

Retroperitoneal Cystic Lymphangioma

E Ergul, S Sarikaya, B Korukluoglu, A Ucar, A Kusdemir

Citation

E Ergul, S Sarikaya, B Korukluoglu, A Ucar, A Kusdemir. *Retroperitoneal Cystic Lymphangioma*. The Internet Journal of Surgery. 2007 Volume 15 Number 1.

Abstract

An interesting and rare differential diagnosis for a retroperitoneal cystic mass is cystic lymphangioma. A case of a patient presenting with a multicystic mass in the retroperitoneum that was identified as a cystic lymphangioma is reported. These tumours are commonly confused with other cystic masses in the retroperitoneum.

INTRODUCTION

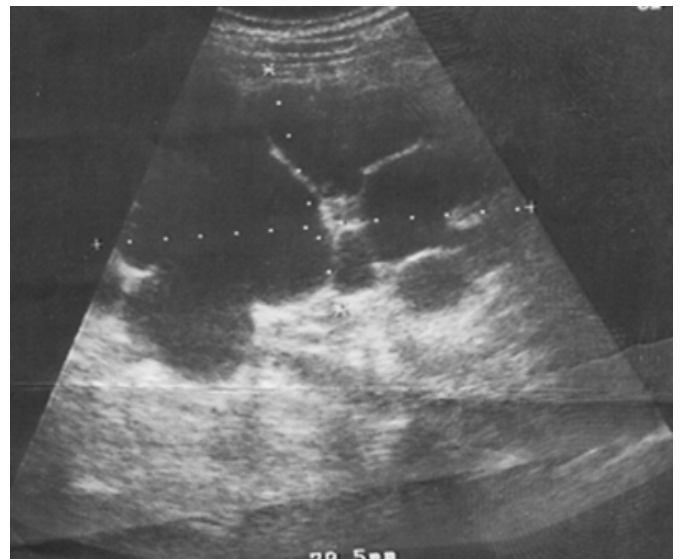
Lymphangiomas are rare cystic tumours that may present as cystic masses in the retroperitoneum. Retroperitoneal lymphangiomas account for approximately 1% of all lymphangiomas¹. Confusion with other cystic tumours of the retroperitoneum including those arising from the liver, kidney and pancreas is common. A case of a patient presenting with a multicystic mass in the retroperitoneum that was identified as a cystic lymphangioma is reported. These tumours are commonly confused with other cystic masses in the retroperitoneum.

CASE REPORT

A 29-year-old man presented with a 2-month history of vague upper abdominal pain and persistent nausea. He had no previous illness episodes. Colonoscopy and gastroscopy were normal. Complete blood count and liver function tests were within normal limits. An ultrasound scan revealed a large multiloculated cystic mass (the largest one with 13 × 9 × 8cm) in the left paraaortic region from processus xiphoideus to pelvis (Figure 1), which was thought to be extrahepatic. Computed tomography (CT) showed a multiloculated cyst possibly arising from outside the liver compressing the adjacent liver and small bowel which may relate to pancreas (Figure 2). Tumor markers were not elevated and hydatid serology was negative.

Figure 1

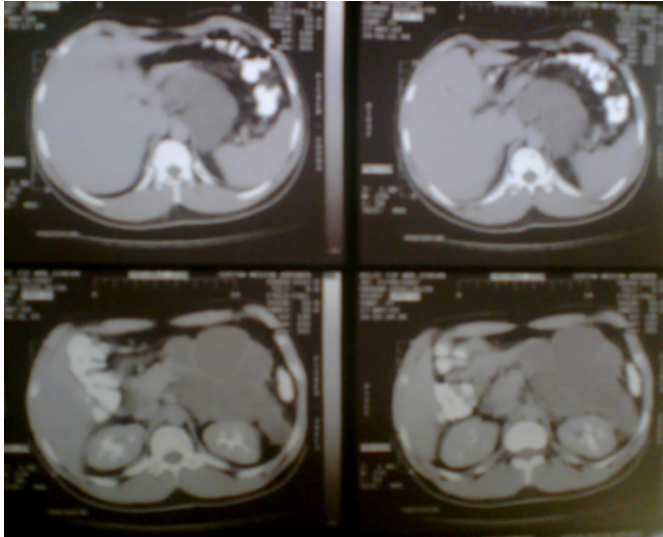
Figure 1: Ultrasonogram of the patient. A multilocular cystic mass can be seen



Preoperative diagnosis based on imaging investigations could not be made with any certainty and a percutaneous biopsy of the lesion was deemed too high-risk due to the location and the possibility of malignant seeding if the lesion was neoplastic. A laparotomy was ultimately performed. A large retroperitoneal multicystic tumour attached to the tail of the pancreas and left kidney was identified. The cyst was excised intact, with a small portion of attached pancreatic capsule and tissue. The histopathological examination of the cyst wall demonstrated fibrosis, inflammatory cell infiltrate and the presence of endothelial lined vascular channels. These findings confirmed a benign lymphangiomatous cyst and a diagnosis of retroperitoneal cystic lymphangioma. Recovery of the patient was uncomplicated.

Figure 2

Figure 2: Computerized tomogram of the patient. A multiloculated cyst possibly arising from outside the liver, compressing the adjacent liver and small bowel, which may relate to pancreas, can be seen.



DISCUSSION

The differential diagnosis of cystic tumour in the retroperitoneum raises several possibilities. These include both malignant and benign tumours. Malignant causes include necrotic neoplasms, germ cell tumours (teratoma), undifferentiated sarcoma, cystic metastases (gastric/ovarian), malignant mesenchymoma, biliary cystadenoma/carcinoma and cystic mesothelioma¹. Benign cystic lesions of the retroperitoneum include lymphangioma, microcystic pancreatic adenoma and cysts of urothelial and foregut origin. Cysts of foregut origin are subdivided into bronchogenic cysts, which contain cartilage or seromucinous respiratory glands, oesophageal cysts, which are composed of well-developed layers of smooth muscle without cartilage, and simple foregut cysts, which have none of these distinguishing features¹.

Retroperitoneal cystic lymphangioma is a rare, benign mesodermal tumour arising from the retroperitoneal lymphatics. Lymphangiomas are histologically classified as capillary, cavernous and cystic with the retroperitoneal types being almost always cystic². These cystic lesions may be unilocular or multilocular and contain serous or chylous fluid. The majority (more than 95%) are situated in the head, neck, axilla and extremities. Other sites including the abdomen are seen only in 5% of cases². The intraabdominal cystic lymphangiomas occur in less than 1 per 100,000 hospital admissions. Retroperitoneal lymphangiomas are rarer than abdominal lymphangiomas of mesenteric origin.

The postulated mechanism for the formation of lymphangioma is the early developmental sequestration of lymphatic vessels that fail to establish connection with normal draining vessels at about 14 to 20 weeks of intrauterine life².

Cystic retroperitoneal lymphangioma can present in infancy with 50% to 60% occurring during the first year of life and 90% in the second year. They usually present as palpable soft abdominal masses. Though benign, they can compress and infiltrate vital structures³, or present with complications like intracystic hemorrhage, cyst rupture, volvulus or infection.

Preoperative diagnosis of lymphangiomas is rare prior to laparotomy or laparoscopy⁴. Abdominal X-rays generally show nonspecific expansion and, in some cases, foci of calcification may be seen. Lymphangiography is seldom used but is sometimes useful in preoperative diagnosis. CT and MRI features of lymphangiomas have been described. The diagnosis of lymphangioma based on these modalities is generally one of many potential differential diagnoses for a multiloculated cystic mass arising retroperitoneally. One of the main features of retroperitoneal lymphangioma is that the mass is generally of water density on CT or MRI⁵. Guided biopsy of the lesion is often difficult and rarely attempted due to the location of tumours and concerns of potential dissemination of malignancy. When fine-needle biopsy is performed, characteristic abundant lymphocytes may be apparent⁵. The likelihood of preoperative diagnosis is greatest when imaging is combined with biopsy.

Outcomes following complete resection of retroperitoneal lymphangiomas are generally good. Surgery is often required for symptom control or diagnosis¹. Recurrence of symptoms with incomplete excision is possible. Dissemination in the retroperitoneum is very rare but potentially a fatal complication¹. Hauser et al. suggested that isolation and ligation of the cystic lymphangioma's peduncle as well as ligation of lymph channels can prevent recurrences and chylascos.

CORRESPONDENCE TO

Emre Ergul, M.D.
Askaabat Cad. Eser Sitesi B3 Blok Daire:11
Bahcelievler 06480
Ankara / Turkey
dreergul@gmail.com
Phone: +905056821500
Fax: +903122123414

References

1. Cherk M, Nikfarjam M, Christophi C. Retroperitoneal lymphangioma. *Asian J Surg* 2006; 29; 51-4.
2. Rani DV, Srilakshmi R, Malathi S, Raghupathy V, Bagdi RK. Unusual presentation of a retroperitoneal lymphangioma. *Indian J Pediatr* 2006; 73; 617-8.
3. Shankar KR, Roche CJ, Carty HM, Turnock RR. Cystic retroperitoneal lymphangioma: Treatment by image guided percutaneous catheter drainage and sclerotherapy. *Eur Radiol* 2001; 11: 1021-3.
4. Hauser H, Mischinger HJ, Beham A, Berger A, Cerwenka H, Razmara J, Fruhwirth H, Werkgartner G. Cystic retroperitoneal lymphangiomas in adults. *Eur J Surg Oncol* 1997; 23: 322-6.
5. Breidahl WH, Mendelson RM. Retroperitoneal lymphangioma. *Australas Radiol* 1995; 39: 187-91.

Author Information

Emre Ergul, M.D.

General Surgery Department, Ankara Ataturk Teaching and Research Hospital

Seyit Muhsin Sarikaya, M.D.

General Surgery Department, Ankara Ataturk Teaching and Research Hospital

Birol Korukluoglu, M.D.

General Surgery Department, Ankara Ataturk Teaching and Research Hospital

Ali Erkan Ucar, M.D.

General Surgery Department, Ankara Ataturk Teaching and Research Hospital

Ahmet Kusdemir, M.D.

General Surgery Department, Ankara Ataturk Teaching and Research Hospital