

Acute Gastric Dilatation And Abdominal Compartment Syndrome As Complication Of Pyloric Stenosis

C Parsak, G Sakman

Citation

C Parsak, G Sakman. *Acute Gastric Dilatation And Abdominal Compartment Syndrome As Complication Of Pyloric Stenosis*. The Internet Journal of Gastroenterology. 2006 Volume 5 Number 2.

Abstract

Two patients were admitted to our emergency unit with complaints of acute abdominal syndrome. Both of them had emergency laparotomy due to abdominal compartment syndrome which is diagnosed with clinical findings and the measurement of the bladder pressure. At laparotomies we established generalized peritonitis caused by the gastric perforation. Gastric perforations were triggered by the acute gastric dilation due to pyloric stenosis. Both patients expired during the operation, because of the sepsis and the abdominal compartment syndrome.

Patients who are not appropriately treated for the peptic ulcer may develop pyloric stenosis and gastric volvulus. It should keep in mind that gastric contents and air may cause abdominal compartment syndrome and its prognosis is very poor.

INTRODUCTION

Generally speaking, pyloric stenosis is gastric outlet obstruction arising from edema, spasms and scar tissue due to chronic peptic ulcer¹. Gastric perforation due to pyloric stenosis generally starts off from the side with ulcer generally, and lies along the major curvature. When treatment is delayed, it results in mortality by 15-20% in ratio^{1,2}. Abdominal compartment syndrome, characterized by acute and pathological elevation in intra-abdominal pressure, is a clinical syndrome, which results in mortality if not treated³. In this report, we aimed to discuss these two emergency cases in which advanced stomach dilatation developed, and resulted in gastric perforation due to pyloric stenosis.

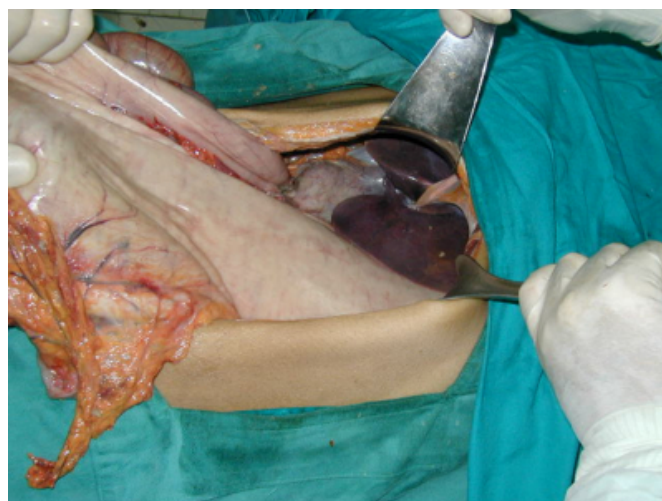
CASE 1

A 35 years old, female patient had dyspeptic complaints for one year, and vomiting complaints during the last month. Intra-abdominal pressure (IAP) of the patient was measured to be 40 mm/Hg (measured the bladder pressure as described by Kron et al⁴). The patient's general condition was bad, conscience unclear and confused and pulse: 148/min., TA: 80/30 mm/Hg, respiratory asidose and oligury were present. When evaluated together with the clinical table, the patient who was considered to be a grade 4 abdominal compartment syndrome case was given 100 ml mannitol, sodium bicarbonate and dopamine infusion were performed in order to be able to compensate for the effects of reperfusion

syndrome, and the patient was operated immediately. We detected the pyloric obstruction due to pre-pyloric ulcer, stomach was dilate and pale, and was full of gas and food. Furthermore, partial gastric volvulus was developed and perforated at the side of major curvature (Figure 1).

Figure 1

Figure 1: Dilate and pale stomach with partial volvulus. Shot from the operation.



She also had generalized peritonitis. Subtotal gastrectomy, bilateral truncal vagotomy and gastroenterostomy were planned; however, the patient died due to multiple organ failure because of abdominal compartment syndrome and sepsis before the operation could be completed in the 45-

minute planned time.

CASE 2

A 25 years old, female had dyspeptic complaints for two years, and vomiting complaints in the last three months. IAP measurement of the patient was 45 mm/Hg. When evaluated together with the clinical findings, patient who had been thought as grade 4 abdominal compartment syndromes was operated emergently in order to able to compensate for the effects of reperfusion syndrome after the required treatment. The abdomen was dilate, pale and perforated at the side of antrum-major curvature. Due to advanced pyloric stenosis, gastro-splenic ligament was eroded and there was a partial circulation problem at the major curvature. In the first minutes following the laparotomy, sudden hypotension, asystole and supraventricular arrhythmia were detected, and the patient died despite internal cardiac massage and resuscitation. In this case, where abdominal compartment syndrome had been advanced, early death took place immediately following the first minutes of the laparotomy, and since findings are in consistent, we assume that this could be due to reperfusion syndrome despite prophylactic treatment.

DISCUSSION

One of the four cardinal complications of peptic ulcer is pyloric stenosis (2-6%)^{1,5}. Dilatation is triggered by the vicious cycle of elevation in gastrin secretion due to stretched antrum and stomach secretion, which is elevated due to gastrin secretion^{1,2}. Patients have generally suffered from presence of peptic ulcer in the long term (8-10 years), and they had irregular or mistreatment history^{1,5,6}. In our cases, patients had ulcer complaints for a shorter time (1 year and 2 years, respectively) compared to our findings from the literature. Both were diagnosed as peptic ulcer with endoscopy. The first case did not receive any ulcer treatment due to sociocultural reasons, and the second case had refused to be hospitalized although she applied to hospital because her complaints continued after one cure of post medical treatment 20 days ago.

In perforations together with pyloric stenosis, perforation starts off from the ulcer region and proceed onto the major curvature. Linear tears might rarely be seen along the major curvature due to gastric volvulus and acute abdominal dilatation^{1,2,6}. In our first case, perforation had started from the ulcer region and proceeded onto the major curvature. In the second case, we had advanced gastric dilatation and erosion in gastro-splenic ligament and partial circulation

problem at major curvature. Most probably, the perforation along the major curvature had stemmed from partial gastric volvulus.

Abdominal compartment syndrome is a breakdown in circulation due to the elevation of pressure in a limited anatomic region, and therefore blood rushes the tissues, making a negative effect on the functionality of the organs^{3,7}. In etiopathogenesis, peritonitis, perforation and acute stomach dilatation are the reasons to be attributed to^{2,6,7}. In grade 4 cases, mortality is between 71-85%^{3,7}. In decompressive laparotomies the most frequent death reason encountered is reperfusion syndrome. This appearance proceeds on with high mortality, characterized by hypotension, asystoly attacks and supra-ventricular arrhythmia due to a sudden expansion in abdominal and pelvic veins. In order to compensate for the effects of reperfusion syndrome, prophylaxis should be performed with solutions containing mannitol and sodium bicarbonate at the preoperational stage. Vasoconstrictor and inotropic agents might be useful in preventing cardiovascular collapse^{3,7,8}. In both cases, measurement result (40-45 mm-Hg) and clinical findings with grade 4 were accepted as abdominal compartment syndrome. Because of this appearance proceeding with high mortality, the first case, and though prophylactic treatment had been performed to the second case, reperfusion syndrome developed, and both of them died.

We consider that this rarely seen pathology, which results from delay in the treatment as well as the abdominal compartment syndrome due to the acute abdomen and sepsis appearance, leads to high mortality rate. Therefore, hereby we discuss this issue.

CORRESPONDENCE TO

Dr. Cem Kaan Parsak, M.D. Cukurova University E mail: cparsak@cu.edu.tr Phone: 90.322.3386432 Fax: 90.322.3386432 Adres: Cukurova University Medical Faculty Department of General Surgery 01330 Balcali/ADANA/TURKEY

References

1. Paimela H, Joutsu T, Kivilioto T: Recent trends in mortality from peptic ulcer disease in Finland. *Digestive diseases and Sciences*, 1995; 40(3): 631-635.
2. Farag S, Fiallo V, Nash S, Navab F: Gastric perforation in a case of gastric volvulus. *Am J Gastroenterol*, 1996; 91(9):1863-1864.
3. Schein M, Wittman DH: The abdominal compartment syndrome following peritonitis, abdominal trauma and operations. *Complications in Surgery*, 1996; 15: 1-10.

4. Kron IL, Harman PK, Stanton P: The measurement of intra-abdominal pressure as a criterion for abdominal re-exploration. *Ann Surg*, 1984; 1:28-31.
5. Forbes GM, Glaser ME, Cullen DJE: Duodenal ulcer treated with H.Pylori eradication, Seven year follow-up. *Lancet*, 1994; 343: 258-260.
6. Lunca S, Rikkers A, Stanescu A: Acute massive gastric dilatation: severe ischemia and gastric necrosis without perforation. *Rom J Gastroenterol Sep*, 2005; 14(3):279-283.
7. Flores AE, Avila GE, Gonzales GE, Rivera BE, Lopez JL, Reynoso T : Early diagnosis and risk factors associated with abdominal compartment syndrome. *Cir Cir May-Jun*, 2005; 73(3):179-183.
8. Serpytis M, Ivaskevicius J; Intra-abdominal hypertension and multiple organ dysfunction syndrome. *Medicina*, 2005; 41(11): 903-909.

Author Information

Cem K. Parsak, M.D.

Department of General Surgery, Cukurova University Medical Faculty

Gurhan Sakman, M.D.

Department of General Surgery, Cukurova University Medical Faculty