

# Adenocarcinoid Tumors of the Gastrointestinal Tract: Case Report and Review of the Literature

R Ranganath, A Ramakrishnan, A Ayyappan, M Vikas

## Citation

R Ranganath, A Ramakrishnan, A Ayyappan, M Vikas. *Adenocarcinoid Tumors of the Gastrointestinal Tract: Case Report and Review of the Literature*. The Internet Journal of Surgery. 2006 Volume 10 Number 1.

## Abstract

Composite adenocarcinoma-carcinoid tumors have been described in the esophagus, stomach, ampulla of Vater and in the colon. These form a distinct pathologic entity in a spectrum of tumors ranging from the pure adenocarcinoma to the pure carcinoid. The biologic behavior, treatment and prognosis of these tumors is determined by the glandular component. We describe two varied clinical presentations in this spectrum, to bring into focus this clinical and pathologic chimera.

## INTRODUCTION

The presence of both neuroendocrine and glandular elements in a tumor of the gastro-intestinal tract (GIT), lends itself to diagnostic and therapeutic dilemmas. It has been shown that 13% of all gastric cancers and 5-10% of colorectal cancers may have a neuroendocrine component in them<sup>1</sup>. The following two cases illustrate the clinical presentation, pathologic features and management of these tumors.

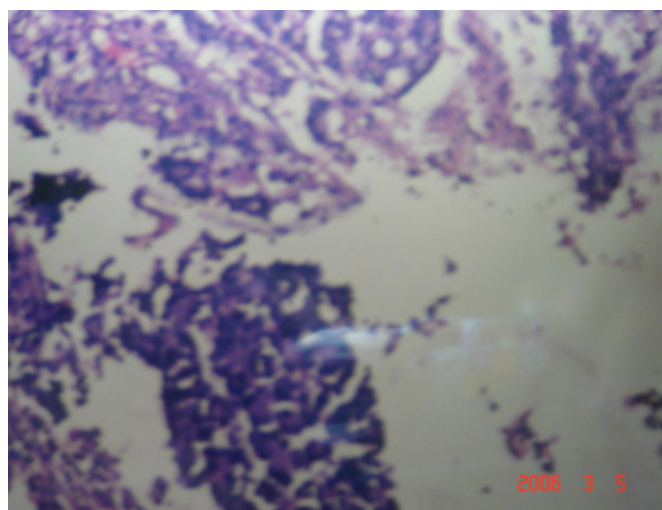
## CASE 1

A 38-year-old man presented with history of bleeding per rectum and fatigability. Clinical examination revealed an 8 x 6 cm firm nodular mass in the epigastrium. There were no pelvic deposits or supraclavicular nodes. Investigations demonstrated an ulceroproliferative tumor arising in the mid-transverse colon with no evidence of distant metastases. Biopsy was suggestive of a poorly differentiated adenocarcinoma.

With this clinical picture, the patient underwent a tranverse colectomy with segmental resection and anastomosis of a loop of adherent jejunum. His recovery was uneventful. The postoperative histopathology demonstrated areas of well differentiated adenocarcinoma interspersed with distinct areas of carcinoid tumor (Fig. 1).

## Figure 1

Figure 1: Photomicrograph of a section of the tumor showing both carcinoid and adenocarcinoma components.



The adenocarcinoma component extended up to the muscular layer, and the lymph nodes demonstrated only reactive hyperplasia. The patient is on follow-up for 8 months now and doing well.

## CASE 2

A 58-year-old man presented with symptoms suggestive of obstructive jaundice and a clinically palpable gallbladder.

Investigations revealed a periampullary tumor causing obstruction to the common bile duct, and numerous sessile polyps in the entire stomach. Endoscopic biopsy from the lesions in the stomach was suggestive of carcinoid tumor and from the periampullary tumor was suggestive of

adenocarcinoma. There were no distant metastases.

The patient underwent a total gastrectomy with Whipple's procedure with reconstruction through an esophago-jejunosomy and a pancreato-jejunosomy. His recovery was uneventful. The post-operative histopathology showed carcinoid tumor in all the polyps in the stomach. The duodenal lesion was reported as a well differentiated adenocarcinoma infiltrating the muscular layer. All the lymph nodes were reactive. He has completed 16 months on follow-up and is doing well.

Neither of these patients had any feature of the carcinoid syndrome nor was the urinary 5-HIAA (5-Hydroxy Indole Acetic Acid) elevated in them.

### DISCUSSION

In 1927, Hamperl was the first to notice the presence of neuroendocrine cells in adenocarcinomas of the gastrointestinal tract<sub>1</sub>. Since then, these endocrine cells have been detected in a variety of neoplasms of the GI tract. 5-10% of all colorectal cancers show the presence of these cells<sub>1</sub>.

Pathologically these tumors have been classified into: amphicrine tumors, wherein the tumor cells themselves contain both endocrine and exocrine granules, and mixed tumors<sub>2</sub>. Mixed tumors have been further characterized as composite tumors wherein the two components are intermingled intimately and combined tumors wherein the carcinoid and the adenocarcinoma component are present in distinct areas of the tumor. A subset of the combined tumors are the so called "collision tumors" which demonstrate a distinct interface between the two components<sub>3</sub>.

The histogenesis of these tumors has been postulated to be a bi-directional differentiation of the crypt base stem cells, which are totipotent<sub>4</sub>. Collision tumors are hypothesized to arise from two different populations of cells that proliferate independently.

Most cases of mixed adenocarcinoid tumors of the colon arise in association with long standing ulcerative colitis<sub>5</sub>. Reports of tumors which arise de novo are few<sub>5</sub>. Clinical presentation is mostly with a palpable mass and bleeding per rectum, with a small proportion of patients suffering from

the carcinoid syndrome<sub>6</sub>. Radical surgery as for any adenocarcinoma of the colon is the sine qua non of management and adjuvant therapy is decided based on the stage of the epithelial tumor<sub>6</sub>.

The incidence of a carcinoid tumor of the GIT co-existing with an adenocarcinoma synchronously has been reported to range from 0.3-4.3%. Most of these patients had the carcinoid tumor more proximally in the gut. Prognosis and management depend upon the stage of the individual tumors. Some authors recommend an active search for a co-existent adenocarcinoma in the presence of a carcinoid of the GIT<sub>7</sub>.

In the mixed tumors, the prognosis and overall survival is determined by the glandular component and not by the carcinoid component<sub>8</sub>.

The above discussion attempts to focus attention on the spectrum of histogenesis, pathology, clinical presentation, management and prognosis of an uncommon clinico-pathologic entity.

### CORRESPONDENCE TO

Ranganath R. Division of Surgical Oncology, Cancer Institute (WIA), Adyar, Chennai – 600020 Ph: 044 – 22350241. e-mail id: pranganam@yahoo.co.in Fax: 044 – 24912085.

### References

1. Carlo Capella, Stefano La Rosa, Silvia Uccella, Paola Billo, Matteo Cornaggia. Mixed endocrine - exocrine tumors of the gastrointestinal tract. *Seminars in diagnostic pathology* 2000; 17 (2): 91 - 103.
2. Komminoth R. Duodenal neuroendocrine tumors. *Rev Esp Patol.* 1999; 32: 401-403.
3. Laszlo Mandoky. Amphicrine tumor. *Pathology Oncology research.* 1999; 5 (3): 239-244.
4. Knight BK, Hayes MM. Mixed adenocarcinoma with carcinoid tumor of the colon: A report of 4 cases with postulates on histogenesis. *S Afr Med Journal* 1987; 72(10):708-710.
5. Lyss AP, Thomson JJ, Glick JH. Adenocarcinoid of the colon arising in pre existing ulcerative colitis. *Cancer* 1981; 48: 833-839.
6. Shah PR, Tustin RP, Haray PN. Adenocarcinoid of the midgut: An unusual presentation of a rare tumor. *The Internet Journal of Surgery* 2003; 4 (2).
7. Chaturvedi KU, Kaur H. Composite carcinoid carcinoma of the colon. *Indian Journal of Cancer* 1994; 31 (3): 203-206.
8. Varghese NM, Zaitoun AM, Thomas SM, Senapati A, Theodossi A. Composite glandular carcinoid tumor of the terminal ileum. *J Clin Pathol* 1994; 47: 427-429.

**Author Information**

**R. Ranganath**

Division of Surgical Oncology, Cancer Institute (WIA)

**AS. Ramakrishnan**

Division of Surgical Oncology, Cancer Institute (WIA)

**A. Ayyappan**

Division of Surgical Oncology, Cancer Institute (WIA)

**Mahajan Vikas**

Division of Surgical Oncology, Cancer Institute (WIA)