

# Management Of High Energy Tibial Fractures Using Ilizarov Apparatus

S Sidharthan, A Sujith, A Rathod, R Pathak

## Citation

S Sidharthan, A Sujith, A Rathod, R Pathak. *Management Of High Energy Tibial Fractures Using Ilizarov Apparatus*. The Internet Journal of Orthopedic Surgery. 2005 Volume 3 Number 1.

## Abstract

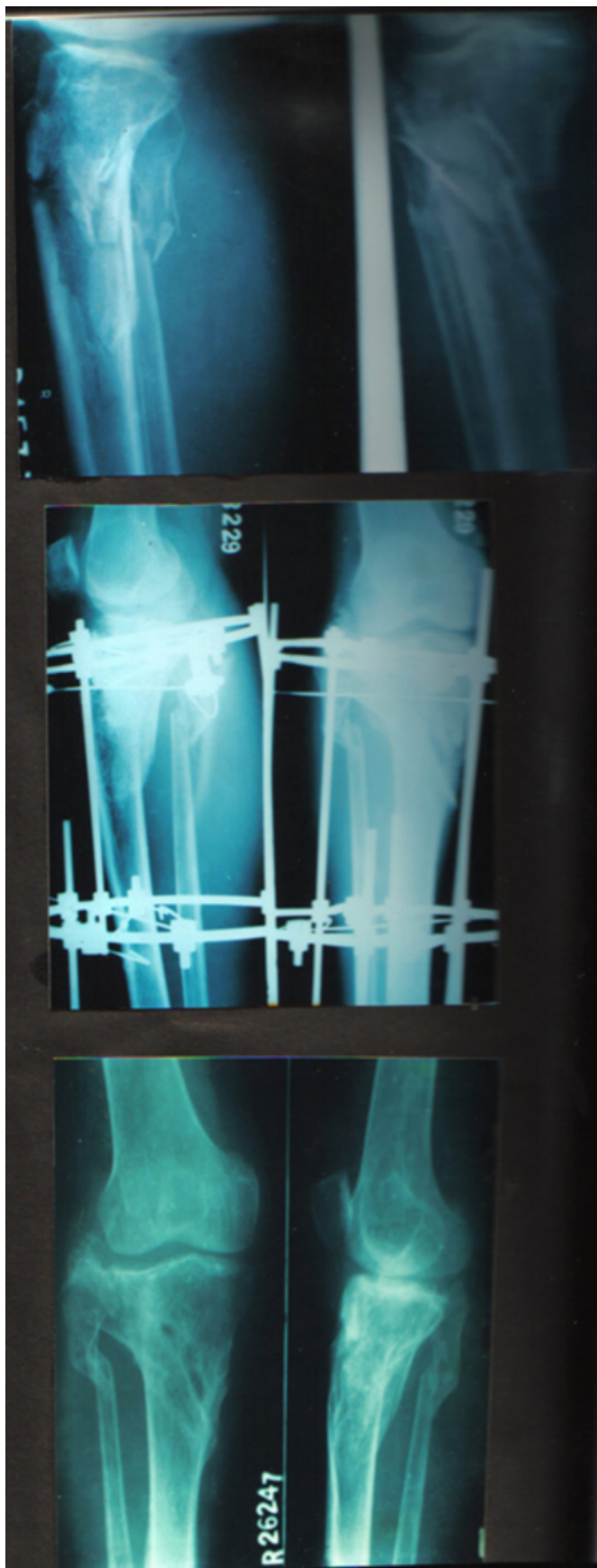
Forty-two high-energy tibial fractures (18 closed and 24 open) in 41 patients were treated with Ilizarov apparatus between 1999 and 2004. Open wounds were debrided and tension free primary closure using interrupted nylon sutures was attempted wherever appropriate. In others, either split thickness skin grafting or local gastrocnemius flaps were used. Corticotomy and bone transport was instituted in patients with significant bone loss. Early weight bearing with range of motion exercises of ankle and knee joints were encouraged. Average fracture healing time was 5.3 months (range 3.5 ... 8.5 months). Complications included pin site inflammation / infection (40.4 %), muscle transfixation (2 cases), shortening (3 cases), ankle joint stiffness (2 cases) and wire fracture (1 case). Based on Johner and Wruh's Criteria, there were 34 excellent, 6 good, 2 fair, and no poor results. The Ilizarov device provided early and definitive fixation for high-energy tibial fractures with good results.

## INTRODUCTION

Fractures of tibia are very common in patients with trauma (1). Their treatment, prognosis, and outcome are mainly determined by the mechanism of injury, degree of resulting comminution, soft tissue injury and displacement (2). Fractures produced by indirect trauma have a better prognosis than those produced by direct trauma (3,4). The risk of delayed union and nonunion in closed (1,4) and open treatment is increased with comminution (5). Open fractures

have a higher infection rate than closed fractures (6) and the rate increases with the increasing severity of the soft tissue injury (7,8). Minimally displaced fractures allow more simple treatment than displaced fractures (1). Therefore high-energy injuries have added to the number and complexity of fractures of long bones, especially those of tibia and so have the treatment modalities addressing them. We evaluated the use of Ilizarov device as the initial and definitive mode of fracture stabilization of these fractures.

**Figure 1**



## **MATERIALS AND METHODS**

From 1999 to 2004, 42 high-energy tibial fractures in 41 patients (37 male, 4 female) were treated primarily with Ilizarov apparatus. Grade III open and/or comminuted tibial fractures was the major inclusion criteria. Exclusion criteria included low energy fractures; grade 3C open fractures and patients who found the apparatus aesthetically unacceptable. The mean age was 39.1 years (range, 14-65 years). Road traffic accidents were responsible for majority of cases (33). Three of the fractures were segmental, and 1 was bilateral. Four patients had multiple traumas. There were 18 closed fractures and 24 open fractures. Using the Gustilo and Anderson (8) classification, 4 were Grade I, 3 were Grade II, 8 were Grade IIIA and 9 were Grade IIIB. There were 21 proximal metaphyseal, 17 diaphyseal and 3 distal metaphyseal fractures.

Informed consent was obtained in all cases. All open wounds were irrigated copiously with normal saline followed by debridement of all the devitalised bone and soft tissue. Antibiotic treatment was initiated in the emergency room with Cefazolin given intravenously for all open fractures and additional gentamycin for Grade III open fractures. The antibiotics were given for 3 days in type I and II wounds and for 5 days for type III wounds. Tension free primary closure using interrupted nylon sutures was attempted wherever appropriate. If safe closure could not be accomplished, the size of the wound was minimised by mobilization of the adjacent tissues over the bone with or without additional split thickness skin grafting. All the Grade IIIA fractures were closed successfully with no wound complications. Of the Grade IIIB fractures, 2 wounds could be successfully approximated and four cases required a gastrocnemius flap. Two patients with a Grade IIIB comminuted fracture presented late after injury with wound infection. A thorough debridement of all the devitalized bone, soft tissue and the infected material was done with primary approximation of bone and soft tissues. The wounds however were not primarily closed, but allowed to heal by secondary intention. A 14-year-old boy with a Grade IIIB wound and segmental bone loss underwent debridement of the remaining fragmented bone and primary closure. Tubular bone transport was performed to regain the length in the three cases mentioned above.

The final application of Ilizarov external fixator involved the use of pre-assembled frames to save the operative time. We generally used a four-ring construct except in segmental fractures (2 cases) where a 5 ring and 6 ring constructs were

used. Wire insertion site hygiene was meticulously taught to the patient. Immediate postoperative regimen consisted of range of motion exercises of ankle and knee. Partial weight bearing was commenced within 48 hours progressing to full weight bearing within the limits of pain. The patients were assessed clinically and radiologically for alignment, bone contact, and later, callus formation, in the outpatient clinic. If in three to six weeks time no callus response was evident, compression at the fracture site was performed. The frames were removed under analgesia and sedation in the outpatient clinic. The leg was protected in a patella-tendon bearing cast for further 4 weeks.

## RESULTS

Forty-one patients with 42 fractures were followed up until union and for a further period of 12 months. Patients were assessed for pain and functional limitations, and examined for angular and rotational mal-alignment and range of motion. Leg lengths were measured clinically.

Pin tract infection occurred in 17 (40.4%) of cases. Twelve resolved by systemic antibiotics for 5 days, in another 4, soft tissue release around the offending wire was done and in one the wires had to be completely removed and reapplied. One case of wire fracture occurred in a case of segmental fracture, which was replaced with no further complications. Three (7.3 %) patients had an angulation of 5° at the fracture site, and three had shortening between 1-2 cms of the fractured leg. Stiffness around the ankle occurred in two cases. Knee range of motion was satisfactory in almost all cases. Two cases of EHL transfixation occurred in our series, which later recovered after frame removal. There were no cases of osteomyelitis or neurologic or vascular complications among these patients.

When there was early evidence of callus formation in the follow up X-rays, union was clinically verified by the absence of pain and motion while fully weight bearing on the tibia with the frame still attached and destabilized. If pain or angulations occurred, the frame was restabilised and immobilisation continued until the above criteria were met. A patella-tendon bearing cast was used for an additional 3 to 4 weeks. Union was determined to be the time when fracture healing occurred and all forms of immobilization or support were discontinued. Union occurred at an average of 5.3 months (3.5 to 8.5months). Based on Johner and Wruhs criteria (2), the final results were rated as 34 excellent, 6 good and 2 fair. No poor results were seen.

**Figure 2**

Table 1: Johner and Wruh's Criteria for evaluation of Final Results After Tibial Shaft Fracture

Criteria	Excellent	Good	Fair	Poor
Nonunion/infection	None	None	None	Yes
Neurovascular injury	None	Minimal	Moderate	Severe
Deformity				
Varus/valgus	None	2-5°	6-10°	>10°
Pro/recurvatum	0-5°	6-10°	11-20°	>20°
Rotation	0-5°	6-10°	11-20°	>20°
Shortening	0-5 mm	6-10 mm	11-20 mm	>20 mm
Mobility				
Knee	Full	>80%	>75%	<75%
Ankle	Full	>75%	>50%	<50%
Subtalar	>75%	>50%	<50%	
Pain	None	Occasional	Moderate	Severe
Gait	Normal	Normal	Mild limp	Significant
Activities				
Strenuous	Possible	Limited	Severely limited	Impossible
Study results	34	6	2	0

**Figure 3**

Table 2

Abbreviations																
SP - SPONTANEOUS RELEASE					E - EXCELLENT					VA - VEHICULAR ACCIDENT						
LL - LIMB LENGTHENING					G - GOOD					RA - RAILWAY ACCIDENT						
MT - MUSCLE TRANSFIXATION					F - FAIR					FFH - FALL FROM HEIGHT						
SG - SKIN GRAFTING					P - POOR					DFO - DIRECT FALL OF HEAVY OBJECT						
ROM - RANGE OF MOTION					FL - PULL					WR - WIRE REMOVALS						
Case	Age	Sex	Mech of Injury	Site	Fracture Pattern	Soft Tissue Status	Infection at Entry (Number)	Infection at Exit (Number)	Fracture Union (Months)	Fix Time (Months)	Ext Time (Months)	Shedding (Months)	Complications	Other	Final Union (Months)	Final Status
1	38	F	VA	LL	42B2	Closed	4	4	24	4	4	4	FL	FL	FL	FL
2	48	M	VA	LL	42B2	Closed	4	4	24	4	4	4	FL	FL	FL	FL
3	38	M	VA	LL	42B2	Closed	4	4	24	4	4	4	FL	FL	FL	FL
4	48	M	VA	LL	42B2	Closed	4	4	24	4	4	4	FL	FL	FL	FL
5	38	M	VA	LL	42B2	Closed	4	4	24	4	4	4	FL	FL	FL	FL
6	38	M	VA	LL	42B2	Closed	4	4	24	4	4	4	FL	FL	FL	FL
7	38	M	VA	LL	42B2	Closed	4	4	24	4	4	4	FL	FL	FL	FL
8	38	M	VA	LL	42B2	Closed	4	4	24	4	4	4	FL	FL	FL	FL
9	38	M	VA	LL	42B2	Closed	4	4	24	4	4	4	FL	FL	FL	FL
10	38	M	VA	LL	42B2	Closed	4	4	24	4	4	4	FL	FL	FL	FL
11	38	M	VA	LL	42B2	Closed	4	4	24	4	4	4	FL	FL	FL	FL
12	38	M	VA	LL	42B2	Closed	4	4	24	4	4	4	FL	FL	FL	FL
13	38	M	VA	LL	42B2	Closed	4	4	24	4	4	4	FL	FL	FL	FL
14	38	M	VA	LL	42B2	Closed	4	4	24	4	4	4	FL	FL	FL	FL
15	38	M	VA	LL	42B2	Closed	4	4	24	4	4	4	FL	FL	FL	FL
16	38	M	VA	LL	42B2	Closed	4	4	24	4	4	4	FL	FL	FL	FL
17	38	M	VA	LL	42B2	Closed	4	4	24	4	4	4	FL	FL	FL	FL
18	38	M	VA	LL	42B2	Closed	4	4	24	4	4	4	FL	FL	FL	FL
19	38	M	VA	LL	42B2	Closed	4	4	24	4	4	4	FL	FL	FL	FL
20	38	M	VA	LL	42B2	Closed	4	4	24	4	4	4	FL	FL	FL	FL
21	38	M	VA	LL	42B2	Closed	4	4	24	4	4	4	FL	FL	FL	FL
22	42	M	VA	LL	42B2	Closed	4	4	24	4	4	4	FL	FL	FL	FL
23	38	M	VA	LL	42B2	Closed	4	4	24	4	4	4	FL	FL	FL	FL
24	38	M	VA	LL	42B2	Closed	4	4	24	4	4	4	FL	FL	FL	FL
25	38	M	VA	LL	42B2	Closed	4	4	24	4	4	4	FL	FL	FL	FL
26	38	M	VA	LL	42B2	Closed	4	4	24	4	4	4	FL	FL	FL	FL
27	38	M	VA	LL	42B2	Closed	4	4	24	4	4	4	FL	FL	FL	FL
28	38	M	VA	LL	42B2	Closed	4	4	24	4	4	4	FL	FL	FL	FL
29	38	M	VA	LL	42B2	Closed	4	4	24	4	4	4	FL	FL	FL	FL
30	38	M	VA	LL	42B2	Closed	4	4	24	4	4	4	FL	FL	FL	FL
31	38	M	VA	LL	42B2	Closed	4	4	24	4	4	4	FL	FL	FL	FL
32	38	M	VA	LL	42B2	Closed	4	4	24	4	4	4	FL	FL	FL	FL
33	38	M	VA	LL	42B2	Closed	4	4	24	4	4	4	FL	FL	FL	FL
34	38	M	VA	LL	42B2	Closed	4	4	24	4	4	4	FL	FL	FL	FL
35	38	M	VA	LL	42B2	Closed	4	4	24	4	4	4	FL	FL	FL	FL
36	38	M	VA	LL	42B2	Closed	4	4	24	4	4	4	FL	FL	FL	FL
37	38	M	VA	LL	42B2	Closed	4	4	24	4	4	4	FL	FL	FL	FL
38	38	M	VA	LL	42B2	Closed	4	4	24	4	4	4	FL	FL	FL	FL
39	38	M	VA	LL	42B2	Closed	4	4	24	4	4	4	FL	FL	FL	FL
40	38	M	VA	LL	42B2	Closed	4	4	24	4	4	4	FL	FL	FL	FL
41	38	M	VA	LL	42B2	Closed	4	4	24	4	4	4	FL	FL	FL	FL

## DISCUSSION

The best mode of treatment is elusive in high-energy tibial fractures. Because of the tenuous soft-tissue coverage of the tibia, plate fixation has typically been associated with an unacceptably high prevalence of wound complications, especially when it has been performed for more severe fractures (29). Tibial nailing though in popular use also has its own share of complications. Malunion occurs after up to 37% of tibial nailing procedures (10) and it is particularly common following fractures of the proximal third of the tibia (11). Severe comminution further adds to the complication. Twenty one (51%) proximal tibial comminuted fractures were treated with Ilizarov fixator with only one case of malunion. Intramedullary nail insertion is also shown to interfere with circulation in the diaphyseal cortex (12,13). Current debate concerns the use of reamed and unreamed intramedullary nailing because both techniques, to varying degrees negatively affect the circulation of cortical

bone (<sub>14,15</sub>). In patients with an open fracture, this has significant implications. When the intramedullary blood supply is destroyed, it leads to necrosis of diaphyseal bone. The vascular system will reconstitute in 2 to 3 weeks, during which time the presence of dead bone and an open fracture wound may increase the risk for infection. External fixator only provided a temporary measure with the additional morbidity associated with pin tract infections. Moreover early weight bearing could not be encouraged.

Ilizarov fixator was chosen to primarily fix those fractures that produced high rate of complications with most conventional methods of fixation. For over half a century the Ilizarov device has been used for treatment of acute fractures and non-unions (<sub>16</sub>). The structure is stable and enables the patient to bear weight on the affected limb straight away even in very comminuted fractures (<sub>17</sub>), not easily achievable by other methods of fixation. The Ilizarov device is minimally invasive with little interference in the biology of fracture while at the same time providing optimal skeletal stability. It also provides opportunity for wound care and management of open fractures. The timing of soft tissue coverage is a subject of controversy. The standard teaching has been that open fractures remain open until the patients is returned to the operating room for a secondary debridement to ensure that adequate debridement of necrotic tissue from the wound has done prior to wound closure (<sub>18</sub>). This recommendation recently has been challenged, with authors advocating primary closure of open wounds in some cases. Shtarker et al. (<sub>19</sub>) used primary suturing and Ilizarov fixation in the treatment of open tibial fractures with good results. Delong and associates (<sub>20</sub>), reported on the study of open fractures with immediate primary closure of the open fracture wound after a thorough debridement. Early wound closure either by primary suture or other means of wound cover after a thorough debridement was the hallmark of this series.

Our protocol encouraged patient to partially weight bear within 48 hours progressing to full weight bearing within the limits of pain (usually within the first week). General condition of the patient and the presence of other associated injuries also influenced the decision to weight bear. An Ilizarov fixator enables the surgeon to correct malalignments and in case of bone loss, to perform adequate limb lengthening (<sub>21</sub>). Only three cases of malunion (7.3%) occurred in this series because necessary adjustments with the rods were made in the earlier stages. All the fractures in this series united. Tucker et al. (<sub>22</sub>) reported 100% union of

26 tibial fractures in 23 patients treated with the Ilizarov fixator. The average union time was 25.6 weeks. Shtaker (<sub>19</sub>) reported 32 open tibial fractures treated with Ilizarov fixator. Healing time was 21.9 weeks in patients with a single injury and 25.7 weeks with multiple trauma similar to the results reported by Schwartzman et al (<sub>23</sub>).

This series is unique with respect to the complexity of the fractures considered. The specific category of fractures subjected to Ilizarov fixation was with the view to clearly define the role of the fixator in primary management of tibial fractures. Even though the circumstances were adverse with respect to the fracture pattern, the union time was not unduly prolonged. However cases that required corticotomy and distraction, necessitated prolongation of the time on the fixator. This is an additional option with the Ilizarov fixator that makes it so versatile.

### CONCLUSION

We recommend the usage of Ilizarov apparatus to provide primary definitive fixation for high-energy tibial fractures. Early weight bearing even in severely comminuted fractures is the key factor that separates it from other methods of fixation. It promotes early functional recovery, eliminating fracture disease. Dynamisation and correction of deformities in any plane is easily accomplished. Frame constructs could be modified to facilitate wound cover and access. Therefore it lends the much-needed flexibility in complex fractures.

### CORRESPONDENCE TO

Sujith Sidharthan, Eyyani House, Thanissery Post, Irinjalakuda, Thrissur, Kerala – 680701, India. Tel.: +914802823091 e-mail: sujsidh@gmail.com

### References

1. Nicoll EA (1974) Closed and open management of tibial fractures. *Clin Orthop* 105:144-153.
2. Johner R, Wruhs O (1983) Classification of tibial shaft fractures and correlation with results after rigid internal fixation. *Clin Orthop* 178:7-25.
3. Bauer GL, Edwards P, Widmark PJ (1962) Shaft fractures of the tibia. Etiology of poor results in a consecutive series of 173 fractures. *Acta Chir. Scand* 124:386.
4. Urist MR, Mazet R, and McLean FC (1954) The pathogenesis and treatment of delayed union and malunion. *J Bone Joint Surg [Am]* 36:931-980.
5. Rosenthal RE, MacPhail JA, and Ortiz JE (1977) Nonunion in open tibial fractures. *J Bone Joint Surg [Am]* 59:244.
6. Witschi TH, Omer GE (1970) The treatment of open tibial shaft fractures from Vietnam War. *J Trauma* 10:105-111.
7. Clancey GJ, Hansen ST (1978) Open fractures of the tibia. *J Bone Joint Surg [Am]* 60:118-122.
8. Gustilo RB, Anderson JT (1976) Prevention of infection in the treatment of one thousand and twenty-five open

- fractures of long bones. *J Bone Joint Surg [Am]* 58:453-458.
9. Bilal C, Leutenegger A, Ruedi T (1994) Osteosynthesis of 245 tibial fractures; Early and late complications. *Injury* 25:349-358.
10. Williams J, Gibbons M, Trundle H, Murray D, Worlock P (1995) Complications of nailing in closed tibial fractures. *J Orthop Trauma* 9:476-481.
11. Lang GJ, Cohen BE, Boss MJ, Kellam JF (1995) Proximal third tibial shaft fractures: Should they be nailed? *Clin Orthop* 315: 64-74.
12. Hupel TM, Weinberg JA, Aksenov SA, Schemitsch EH (2001) Effect of unreamed, limited reamed and standard reamed intramedullary nailing on cortical bone porosity and new bone formation. *J Orthop Trauma* 15:18-27.
13. Kessler SB, Hallfeldt KK, Perren SM, Schweiberer L (1986) The effects of reaming and intramedullary nailing on fracture healing. *Clin Orthop* 212:18-25.
14. Rhinelander FW (1998) Effects of medullary nailing on the normal blood supply of diaphyseal cortex. *Clin Orthop* 350:5-17.
15. Schemitsch EH, Kowalski MJ, Swiontkowski MF (1996) Soft tissue blood flow following reamed versus unreamed locked intramedullary nailing:A fractured sheep tibia model. *Ann Plast Surg* 3:70-75.
16. Catagni M (1991) A.S.A.M.I (Association for the Study and Application of Ilizarov's Method) Group: Fractures of the Leg (Tibia). In Bianchi Maiocchi A, Aronson J (eds). *Operative Principles of Ilizarov*. Baltimore, Williams and Wilkins 91-124.
17. Dagher F, Roukoz S (1991) Compound tibial fractures with bone loss treated by Ilizarov technique. *J Bone Joint Surg [Br]* 73:316-321.
18. Cierny G III, Byrd HS, Jones RE (1983) Primary versus delayed soft-tissue coverage for severe open tibial shaft fractures. *Clin Orthop* 178:54-63.
19. Shtarker H, David R, Stolerio J, Grimberg B, Soundry M (1997) Treatment of open tibial fractures with primary suture and Ilizarov fixation. *Clin Orthop* 335:268-274.
20. DeLong WG Jr, Born CT, Wei SY, Petrik ME, Ponzio R, Schwab CW (1999) Aggressive treatment of 119 open fracture wounds. *J Trauma* 46:1049-1054.
21. Tukiainen E, Asko-Seljavaara S (1993) Use of the Ilizarov technique after a free microvascular muscle flap transplantation in massive trauma of the lower leg. *Clin Orthop* 297:129-134.
22. Tucker HL, Kendra JC, Kinnebrew TE (1992) Management of unstable open and closed fractures using the Ilizarov Method. *Clin Orthop* 280:125-135.
23. Schwartzman V, Martin SN, Ronquist RA, Schwartzman R (1992) Tibial fractures: the Ilizarov alternative. *Clin Orthop* 278:207-216.

**Author Information**

**Sujith Sidharthan, MS (orth), DNB (orth)**

Resident, Department of Orthopaedics, King Edward Memorial Hospital

**Anjali Sujith, MD, DNB**

Resident, Barnard Institute of Radiology, Madras Medical College

**Ashok K. Rathod, MS (orth), DNB (orth)**

Lecturer, Department of Orthopaedics, Dr RN Cooper Hospital

**Rajeev H. Pathak, MS (orth)**

Professor, Department of Orthopaedics, Dr RN Cooper Hospital