

Sliding Perforator Island Flap For Covering A Big Lumbosacral Defect

R Hussein, S Anis

Citation

R Hussein, S Anis. *Sliding Perforator Island Flap For Covering A Big Lumbosacral Defect*. The Internet Journal of Plastic Surgery. 2008 Volume 5 Number 2.

Abstract

The use of perforator island flaps to cover big skin defects is described by many authors. Flex C.Behan¹ described this flap in many publications and showed many cases of hands, face, leg, upper back and other areas. (1,2,3,4,5,7)
Closure of big defects is commonly done by skin grafting or distant flap transfer which often gives bulky masses. Use of transposed local flaps is an excellent idea which can employ different shapes like V-Y and other forms. (1)

CASE REPORT

36 years old Malay man who has a recurrent dermatofibrosarcoma protuberans on the back at the level of the lumbo-sacral region was subjected on 10th of July 2008 for excision of the lesion with a safety margin of 2 – 3 cm, as shown in fig (1) and (2)

The defect measured 12 cm X 10 cm and was rhomboid shaped.

The general surgeon asked to wait until histopathologist gave us the needed informations about the safety margin excised. When he confirmed that the margins are free of any neoplastic cells we proceeded to cover the defect.

Figure 1

Figure 1: Defect after tumor excision of the tumor (dermatofibrosarcoma protuberans)

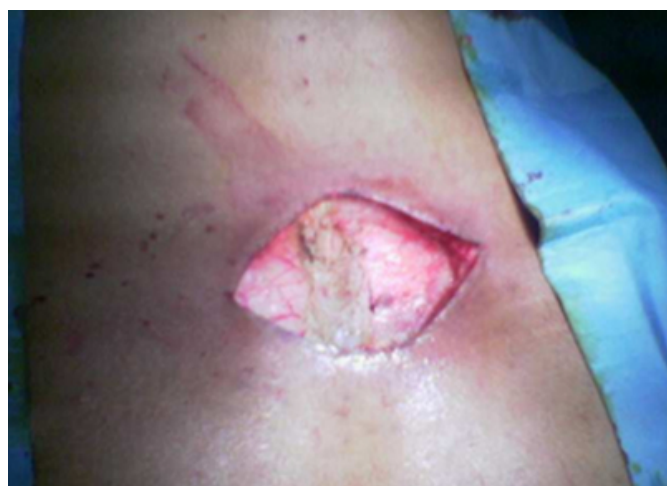
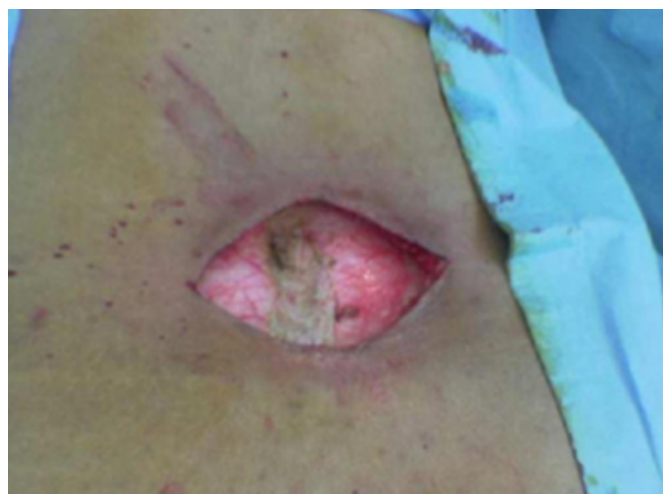
Figure 2

Figure 2



The author designed and mapped the defect and surrounding possible skin flaps.

He put the design as shown in figure (3 - 7) either to make (right thoraco-lumbar and left gluteal) or (left thoraco-lumbar and right gluteal) island flaps.

TECHNIQUE

Incisions were done around the marked areas in Fig (4 and 7) and release of the fasciocutaneous flaps from the surrounding skin and mobilizing these flaps to meet at the center (Fig 5). Mild dissection of proximal ends of these flaps was done to become more mobile. Incision of the deep fascia was also done on both flaps with securing the bleeding vessels.

When the flaps became mobile enough, and met easily to fill the defect, the author started to undermine the upper and lower edges of the wound.

When the author became comfortable with the all flaps, he started to close the wound in layers with a suction drain below the flap Fig (8 and 9). The medial edges of the flaps are sutured to each other and fixed to the underlying tissue over the spine to close any possible dead space.

Figure 3

Figure 3: The defect




Figure 4

Figure 4: Mapping

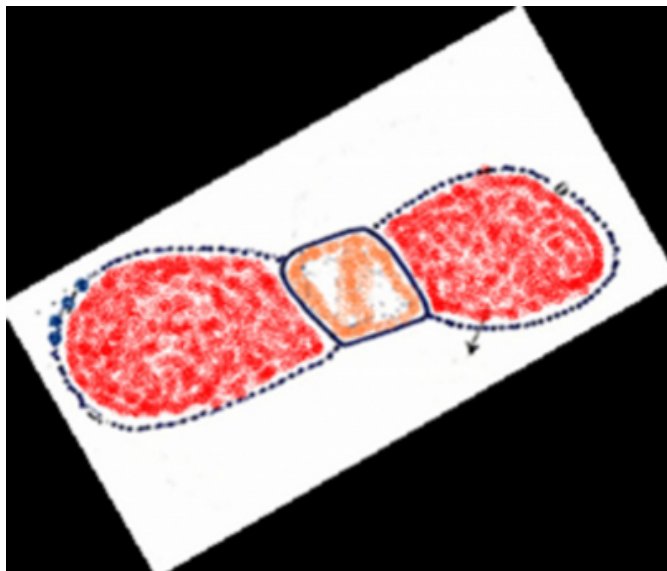


Figure 5

Figure 5: Flap dissection

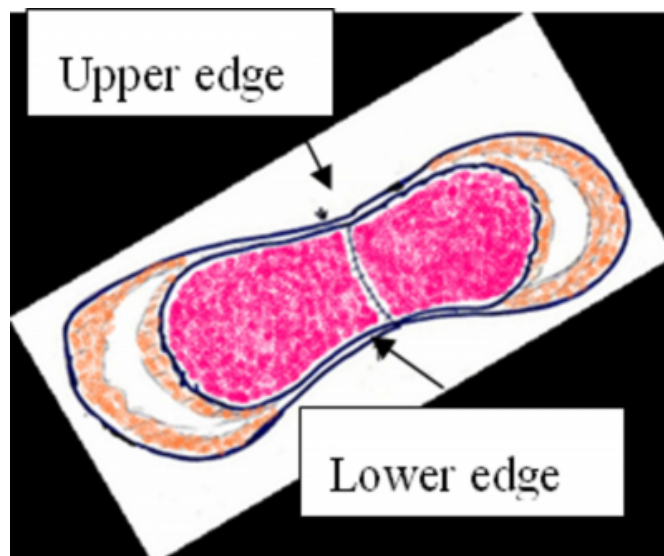


Figure 6

Figure 6: Closure complete

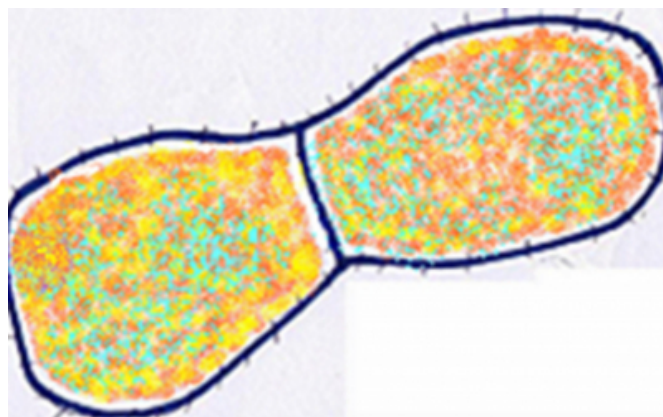
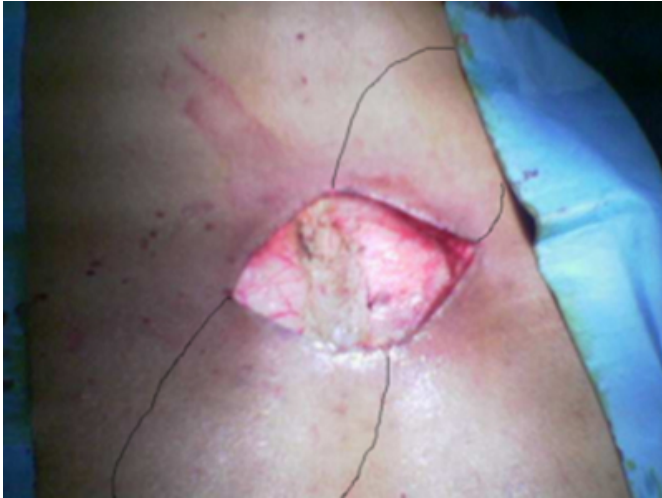

Figure 7

Figure 7: Defect and mapping



POST OPERATIVE

Elastoplast was used with the dressing to cover the wound. Intermittent suction in the 1st 24 hours was done. One session of hyperbaric oxygen was given on the second postoperative day.

Suction vacuum was used until the 8th day, with Ciprofloxacin injection for one week.

Limitation of movement after surgery was requested and prone position or later position was allowed. No sleeping on the back was permitted.

RESULTS

Flaps are nicely healed and closure of the wound was complete

Figure 8

Figure 8: One week after operation with a drain in place

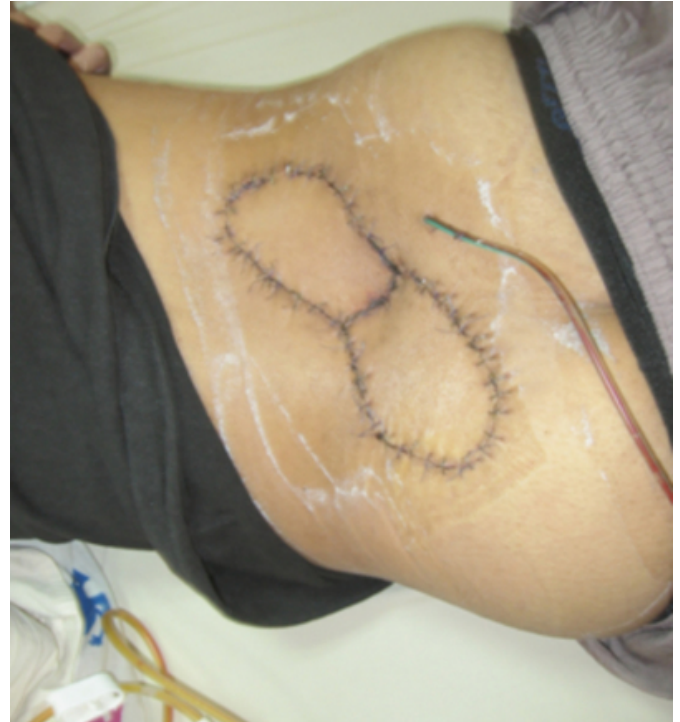

Figure 9

Figure 9

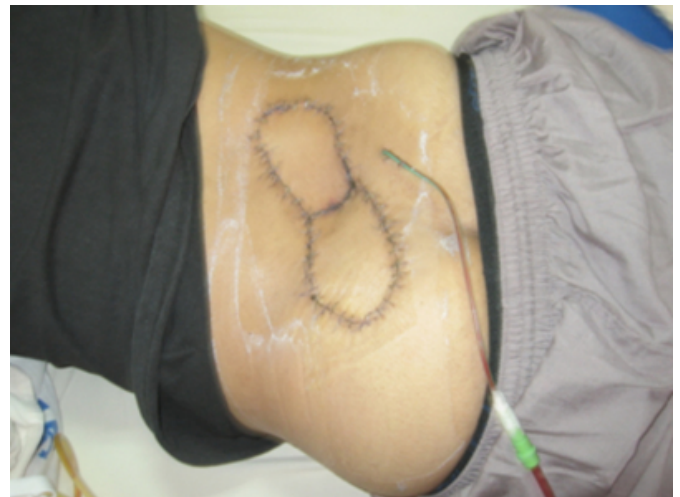

Figure 10

Figure 10: 11 days postoperative

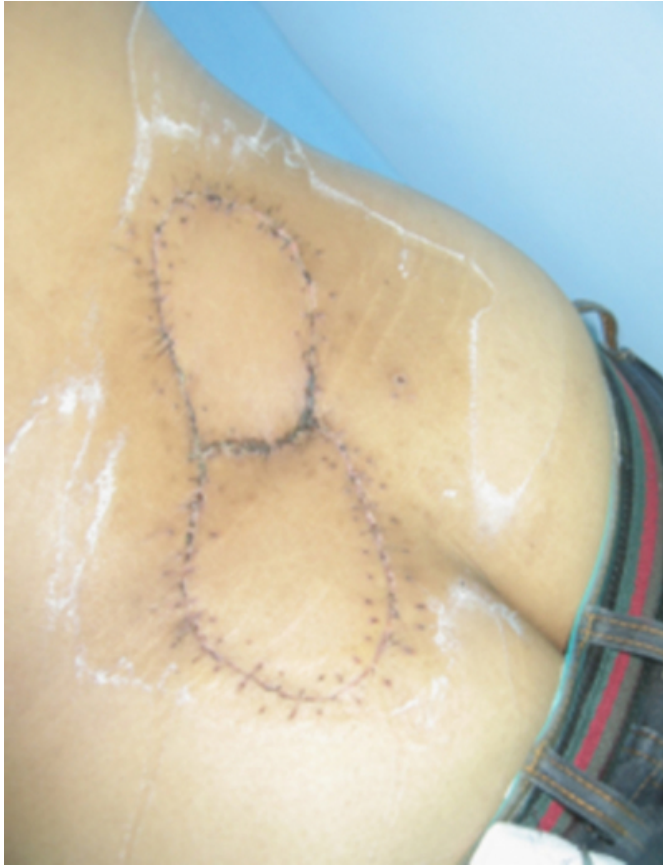
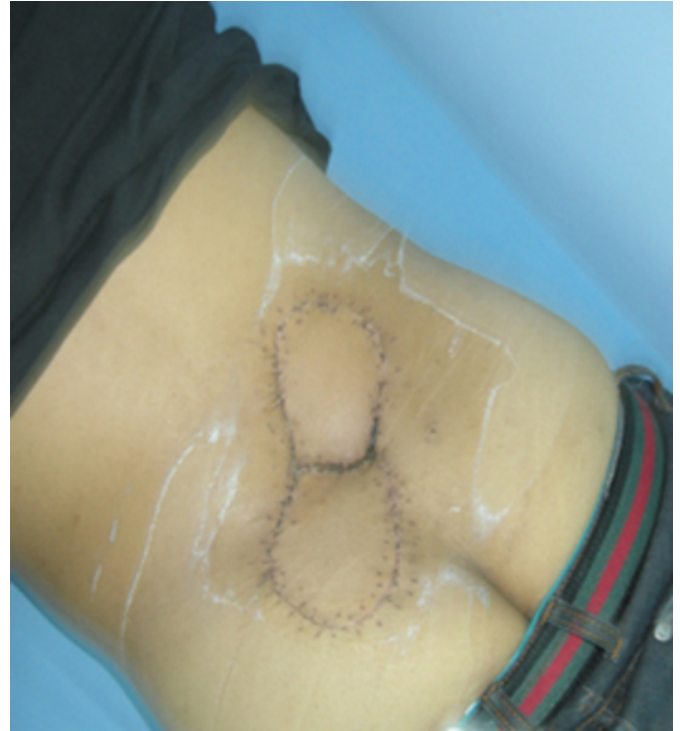
Figure 11

Figure 11



DISCUSSION

Perforator arterial supply to the skin from the underlying soft tissue as muscle or deep fascia are to be considered responsible for viability of the flap.(6)

Design of the flap and dissection need to be based on allocation of the proper arterial supply from the underlying tissues.

With larger flaps the chance of viability and good blood supply will be more. Design of the flaps also should suits the size and shape of the defect. If the perforator artery is well known, the flap can be freed as a pedicle flap and moved up to 90°

CONCLUSION

Mr Felix C. Behan whom the author met in Lengkwari Malaysia 2008, said that this method is an excellent technique to replace free micro-vascular flaps.

ACKNOWLEDGEMENT

Thanks to all colleagues in surgery department in Selayang Hospital headed by Mr Gerald, Mr Abdullah Saleh, Mr Harjit. Thanks to Dr Siti Zaleha Mohd Saleh Director of Hospital Selayang. Appreciate Dato Professor Dr Kalid Yusoff Dean and Dato Professor Dr Aminuddin Ahmad Deputy Dean of Faculty of Medicine University Technology

Mara. Many thanks to Ms Lim Lay Hoay, Head of Plastic Surgery in Malaysia and all plastic surgery colleagues in Egypt and Malaysia.

CORRESPONDENCE TO

Dr Ahmed Hussein AER, plastic surgeon, Malaysia
ahmedhusseinr@yahoo.com,
ahmedhussein@salam.uitm.edu.my

References

1. Behan F C: The Key Stone Design Perforator Island Flap in Reconstructive Surgery, ANZ J.Surg. 2003;73:112-120
2. Behan F C : Key Stone Island Flap An Alternative Reconstructive Option to Free Flaps in Irradiated Tissue, ANZ J.Surg. 2006;76:407-413
3. Behan F C: Reiteration of core principles of the Keystone Island Flap: Correspondance, ANZ J.Surg. 2006;76:1127-1134
4. Behan F C: Evaluation of the Fasciocutaneous Island Flap Leading to the Keystone Flap principle in Lower Limb Reconstruction, ANZ J.Surg. 2006;78:116- 117
5. Behan F C: Lateral Supramalleolar Flap in Reconstruction of Pressure ulcers in Patients with Spinal cord Injury, ANZ J.Surg. 2008;78:167- 171
6. Pelissier P, Santoul M, Pnsolle V, Casoli V, Behan F C: The Key Stone Design Perforator Island Flap. Part I: Anatomic study J BJPS. 2007. 60, 883 - 887
7. Pelissier P, Gardet H, Pnsolle V, Casoli V, Behan F C: The Key Stone Design Perforator Island Flap. Part II: Clinical applications J BJPS. 2007. 60, 888 - 891

Author Information

Rahoma Ahmed Hussein

Associate Professor And Consultant Plastic Surgeon, Faculty Of Medicine, University Technology Mara

Syed Anis

Consultant General Surgeon, Pusrawi Hospital