

Congenital Absence of Pericardium and Straight Back Syndrome: Do They Have Similarities?

M Ali Ostovan, R Mollazadeh

Citation

M Ali Ostovan, R Mollazadeh. *Congenital Absence of Pericardium and Straight Back Syndrome: Do They Have Similarities?*. The Internet Journal of Cardiology. 2006 Volume 4 Number 2.

Abstract

The straight back syndrome, consisting of loss of normal upper thoracic spinal curvature is not an uncommon entity. In contrary congenital defects of the pericardium is a rare disease (1/10000 autopsies). In this report we present a case presented with chest pain whom after initial work up was presumed to have congenital absence of pericardium but further investigation uncovered the diagnosis as straight back syndrome. Here in we review the literature for the possible similarities between these two entities and the possible reason for our first misdiagnosis.

INTRODUCTION

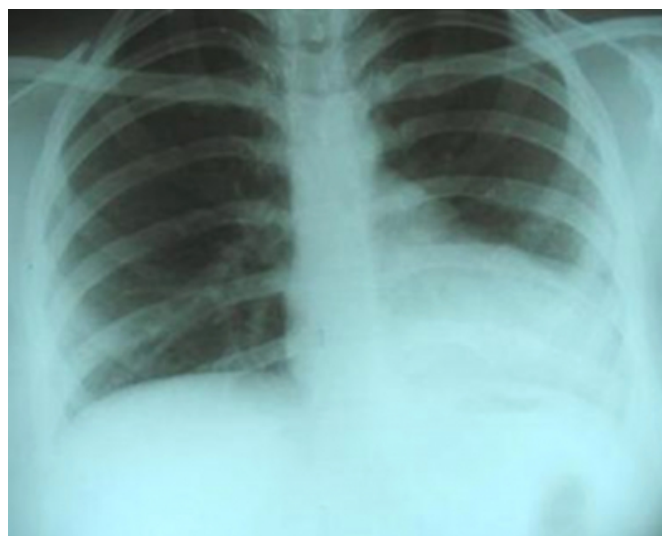
The straight back syndrome, consisting of loss of normal upper thoracic spinal curvature associated with cardiac murmurs which was previously considered a form of 'pseudo heart disease', has been attributed to squashing of the heart in the reduced anteroposterior diameter of the chest¹. On the other hand complete or partial absence of the pericardium is an uncommon congenital anomaly with various complications and presentations². Herein we report a young girl who presented with chest pain and dyspnoea, whom we thought to have congenital absence of pericardium primarily but later found to suffer from straight back syndrome.

CASE PRESENTATION

A 16-year-old girl with no previous cardiac problems came to the outpatient clinic with ill-defined chest pain. She declared that she had this pain for many months. She complained of dyspnoea but not easy fatigability. Her cardiac examination was completely normal. Her electrocardiogram showed poor R wave progression. Postero-anterior chest -X ray showed cardiac levoposition with borderline cardiac size (Figure1).

Figure 1

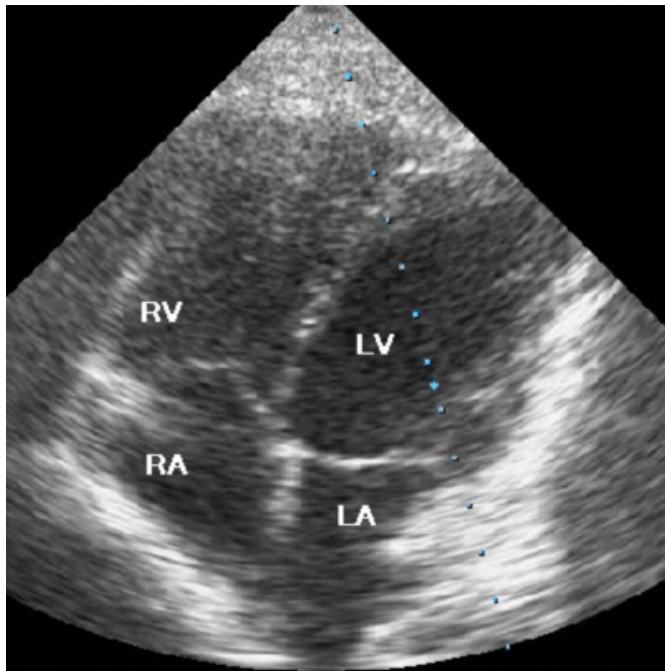
Figure 1: Posteroanterior chest X -ray of the patient. Heart is moved to left hemithorax, cardiac size is enlarged, left heart border is straightened.



Unusual echocardiographic views (Figure2) and paradoxical septal motions (Figure3) during transthoracic echocardiography augmented the suspicion of congenital absence of pericardium, so magnetic resonance imaging was performed. Contrary to our expectation, pericardial contour was intact (Figure 4).

Figure 2

Figure 2: Transthoracic echocardiogram of the patient in apical 4- chamber view that has abnormal view; right atrium and right ventricle falsely seem to be dilated.



RA: Right Atrium, RV: Right Ventricle, LA: Left Atrium, LV: Left Ventricle

Figure 3

Figure 3: M- mode transthoracic echocardiography of the patient in parasternal short axis view that shows paradoxical septal motion.

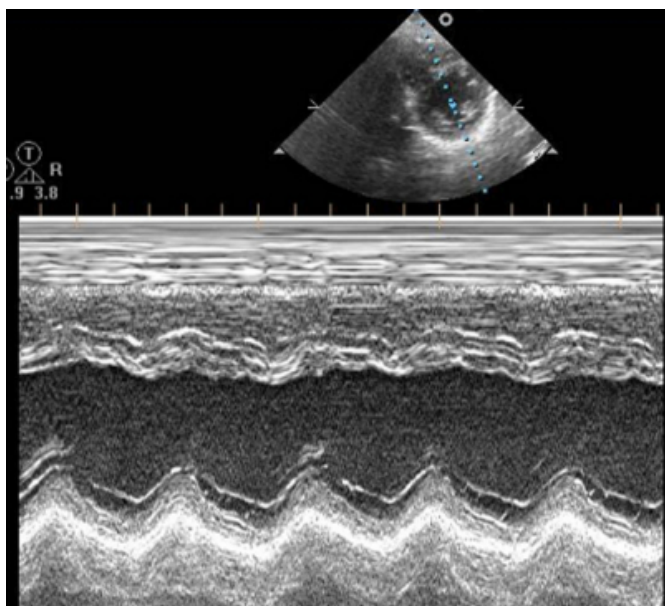
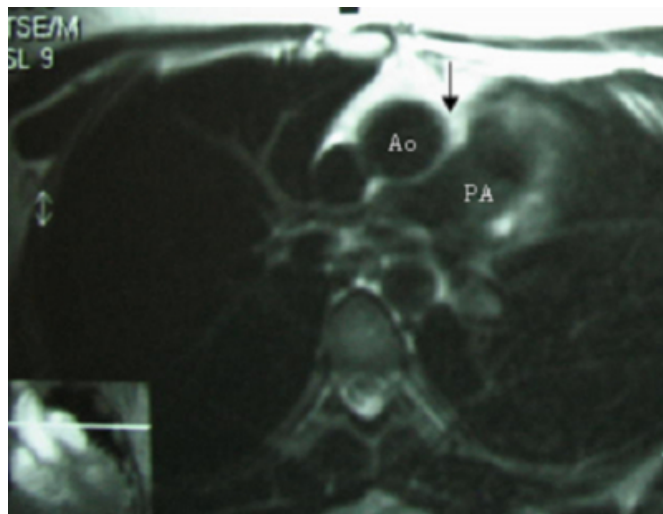


Figure 4

Figure 4: ECG gated T weighted spin echo magnetic resonance image showing no interposition of lung between aorta and pulmonary artery (arrow): Ao: Aorta, PA: Pulmonary Artery



A thorough physical re – examination revealed flat back; a lateral chest x-ray confirmed the presence of obliteration of thoracic kyphosis of the spine.

DISCUSSION

Except for one report of coexistence of congenital absence of pericardium and straight back syndrome³, these two entities seem to be unrelated. Herein we review the literature for their similarities and differences

ETIOLOGY

Congenital pericardial absence is due to premature atrophy of the left common cardiac vein with insufficient blood supply to the pleuropericardium leading to its agenesis. Male/female ratio is 3:1. This entity was described in the context of different syndromes^{4,5,6,7}. HLA typing in straight back syndrome indicates that it is inherited as an autosomal dominant condition and suggested that the antigenic determinants may be located on chromosome 6¹.

CLINICAL MANIFESTATIONS

Congenital absence of the pericardium is an uncommon finding ((1/10,000 in autopsies) comprise partial left (70%), partial right (17%) or total bilateral (extremely rare) pericardial absence²). Most patients are asymptomatic are discovered incidentally during cardiac surgery for an unrelated condition or at postmortem examination. Symptomatic patients may experience non-exertional paroxysmal stabbing chest pain⁸. However homolateral cardiac displacement and augmented heart mobility impose

an increased risk for traumatic aortic dissection₉. Partial left sided defects can be complicated by cardiac strangulation caused by herniation of the left atrial appendage, atrium or ventricle through the defect (chest pain, shortness of breath, syncope, or sudden death). About 30% of patients have additional congenital abnormalities_{4,5,6,7}. Partial absence of pericardium is often associated with other cardiac anomalies including atrial septal defect, bicuspid aortic valve, mitral valve stenosis, patent ductus arteriosus, tetralogy of Fallot or pulmonary malformation. Coexistence with recurrent pulmonary infections₂ and endocarditis₁₀ are also reported.

On the contrary, straight back syndrome usually comes to attention due to cardiac murmurs. Referring diagnosis include atrial septal defect, pulmonic stenosis and rheumatic heart disease. In one study half the patients were asymptomatic; others had dyspnea after brisk effort, palpitation and atypical chest pain₁₁.

PHYSICAL FINDINGS

In patients suffering from pericardial absence clinical examination may show a significantly displaced apical impulse, which may be palpated in the anterior or midaxillary line. Basal ejection murmurs, apical midsystolic clicks and murmurs may also be found. Increased splitting of the second heart sound may be due to the presence of a right bundle branch block that is frequently associated with this defect₁₂.

In straight back syndrome decrease in antero-posterior chest dimensions due to loss of thoracic kyphosis. Other findings in order of frequency are: palpable pulmonary artery pulsation, ejection systolic murmurs in pulmonic area, palpable impulse in left lower sternal border, accentuation and delay in tricuspid valve closure, exaggerated inspiratory splitting of the second heart sound, increase in amplitude of aortic and pulmonary closure. None of patients had thrill in pulmonic area nor did any of them have diastolic murmurs₁₁. Apical systolic click and murmurs are usually due to coexistent mitral valve prolapse₁₃.

ELECTROCARDIOGRAM

Electrocardiographic manifestations of pericardial absence are: bradycardia, right bundle branch block, poor R-wave progression secondary to leftward displacement of the precordial transitional zone, and prominent P-waves in the mid-precordial leads which denote right atrial overload₈.

ECG manifestations of straight back syndrome are right bundle branch block in V₁ and small terminal r waves in aV_R

₁₁.

CHEST –X RAY

Chest X-ray findings due to pericardial absence are levoposition of the heart, flattening and elongation of the left ventricular border, and a lucent area between the diaphragm and the heart, or aorta and pulmonary artery due to lung interposition.

Surprisingly patients with straight back syndrome may have some findings in the Chest X ray: pancake appearance simulating cardiomegaly, levoposition of heart, prominence of the main pulmonary artery₁₃. In all patients both the antero-posterior diameter and the ratio of antero-posterior to transthoracic diameter were below the normal mean₁₁. On the lateral chest radiograph the distance from the middle of the anterior border T₈ to a vertical line connecting T₄ and T₁₂ was found to be significantly reduced compared to controls, and a value less than 1.2 cm is the established criteria for straight back₁.

ECHOCARDIOGRAPHIC FINDINGS

Due to pericardial absence heart forms a “teardrop” appearance due to elongated atria and relatively bulbous ventricles because of suspension of the heart from its basal pedicle₁₄. Findings in order of decreasing frequency are: unusual windows (a higher and more lateral window is required), cardiac hypermobility (cardiopsis), abnormal swinging motion, paradoxical or flat systolic motion of the ventricular septum with normal systolic thickening₁₅. Right ventricular overload with reduction in right atrial dimension may be evident with decreased tricuspid valve excursion. Increased diastolic wave velocities in both the superior vena cava and pulmonary veins on Doppler examination with decreased caval systolic wave velocity suggest accentuation of changes in systemic over pulmonary venous return₁₆ (esp. in partial defects).

Echocardiograms were normal in 36% and abnormal in 64% of patients (mitral valve prolapse (MVP) in (58%) and bicuspid aortic valve in (6%)) of patients with straight back syndrome₁₃. Strong association of MVP with this syndrome was proposed previously₁₇. One of the important issues on the long-axis view of tomographic echocardiography is the aorto-septal angle of patients with straight back syndrome which was wide and thought to be due to clockwise rotation of the heart rather than right ventricular enlargement₁₈.

OTHER TECHNIQUES

ECG -gated MRI and spiral chest CT-scan are two other diagnostic tools to diagnose pericardial absence¹⁹. ECG gated T₁ weighted spin echo magnetic resonance image is highly sensitive and is capable of demonstrating the absence of the preaortic pericardial recess in pericardial absence which is present in normal hearts^{8,19}.

TREATMENT

Complete cases of pericardial absence require no intervention unless complications occur. Patients with debilitating symptoms may benefit from pericardioplasty. However, in partial defects, when herniation occurs or is threatened, extension of the defect by the pericardiectomy, or pericardioplasty may be preformed^{2,8} but in straight back syndrome therapy is directed toward specific coexisting conditions (e.g. MVP).

CONCLUSION

Although congenital absence of the pericardium and straight back syndrome seem to be unrelated, it is important to know their similarities: usually asymptomatic, basal systolic murmurs, right bundle branch block in ECG, levoposition of heart in postero-anterior chest X-ray. Furthermore we want to propose that echocardiography of the patient with straight back syndrome could have abnormal view and paradoxical septal motion probably due to clockwise rotation of heart. Not knowing these issues lead us to misdiagnose patient as congenital absence of pericardium primarily.

CORRESPONDENCE TO

R.Mollazadeh, Nemazee Hospital, Shiraz, Iran E mail: mollazar@yahoo.com Tel: +98 917-313-3749 Fax: +98-711-6261089 P.O. Box: 71435-1414

References

1. Davies M. K., Mackintosh P., Cayton R. M, Page A. J. F. , Shih M. F. and Litter W. A. The Straight Back Syndrome . Q J Med 1980; 49: 443-460
2. LeWinter M.M.,Kabbani Samer 🧐 Pericardial disease. In : Braunwald E,Zipes D, Libby P (eds): Heart disease .7th ed .Philadelphia , W B Saunders , 2005 , pp1779
3. Iwafuchi Y,Okada Y,Kato T,Horikawa K,Terashima

- M,Kobayashi S A case of complete absence of the left pericardium coexisting with straight back syndrome. Kokyu To Junkan 1991; 39:1055-9.
4. Boscherini B, Galasso C,Bitti ML. Abnormal face, congenital absence of the left pericardium, mental retardation, and growth hormone deficiency Am J Med Genet 1994 ;49:111-3
5. Lorell BH. Pericardial diseases. In: Heart Disease: a Textbook of Cardiovascular Medicine, edited by Braunwald E. Philadelphia, PA: Saunders, 1997, p. 1478-1534
6. Lu C, Ridker PM. Echocardiographic diagnosis of congenital absence of the pericardium in a patient with VATER association defects. Clinical Cardiol 1994;17:503-4
7. Zakowski MF,Wright Y,Ricci Jr A.Pericardial agenesis and focal aplasia cutis in tetrasomy 12p (Pallister -killian syndrome).Am J Med Genet 1992;42:323-325
8. Abbas A E ,Appleton CP, Liu PT, Sweeny JP Congenital absence of the pericardium: case presentation and review of literature.Int J Cardiol 2005;98:21-5
9. Kandemir O,Yildiz U,Can B,Kale ATEzcaner T,Zorlutuna Y.congenital complete absence of the left pericardium in a patient with ascending aortic aneurysm. Anadolu Kardiyol Derg. 2006 ;6:11.
10. Sivaprakasam MC ,Narayanan A,vettukatti JJ Absent pericardium: at risk for endocarditis?Cardiol Young 2006 ;16:182-3
11. Antonio C. De Leon Jr. M.D.; Joseph K. Perloff M.D.; Homer Twigg M.D.; Massoud Majd M.D. The straight back syndrome Clinical Cardiovascular Manifestations. Circulation 1965;32:193-203
12. Spodik D., Congenital abnormalities of the pericardium, The Pericardium: A Comprehensive Review (1st ed.), Marcel Dekker, New York1997; 65-75.
13. Ansari A. The "straight back" syndrome: current perspective more often associated with valvular heart disease than pseudoheart disease: a prospective clinical, electrocardiographic, roentgenographic, and echocardiographic study of 50 patients.Clin Cardiol. 1985; 8:290-305.
14. Alizad A and Seward J.B. Echocardiographic features of genetic diseases J. Am. Soc. Echocardiogr. 2000 ;13 : 796-800.
15. Connolly H.M., Click R.L. Schattenberg T.T, Seward J.B. and Tajik A.J., Congenital absence of the pericardium: echocardiography as a diagnostic tool, J. Am. Soc. Echocardiogr.1995;8: 87-92
16. Fukuda N., Oki T. and Iuchi A. et al., Pulmonary and systemic venous flow patterns assessed by transesophageal Doppler echocardiography in congenital absence of the pericardium Am. J. Cardiol. 1995;75:1286-1288
17. Raggi P ,Callister T.Q.,Lippolis N.J., Russo D.J. Is mitral valve prolapse due to cardiac entrapment in the chest cavity?:A CT view Chest 2000;117:636-642
18. Yanagisawa N,Honda M,Watanabe H,Nakamura F,Higuchi Y,Wada T. Counterclockwise rotation of the heart: a correlative study with tomographic echocardiography 1981;11:881-9
19. Wang Z.T., Reddy G.P,Gotway M.B. CT and MR imaging of pericardial disease.2003;23:167-180

Author Information

Mohammad Ali Ostovan

Cardiology Department, Nemazee Hospital

Reza Mollazadeh

Cardiology Department, Nemazee Hospital