

# Delayed Diagnosis of a Patient with Cervical Spine Injury resulting in Complete Cervical Spine Dislocation without Serious or Lingering Neurological Signs: A Case Report

R Clubb

---

## Citation

R Clubb. *Delayed Diagnosis of a Patient with Cervical Spine Injury resulting in Complete Cervical Spine Dislocation without Serious or Lingering Neurological Signs: A Case Report*. The Internet Journal of Emergency Medicine. 2006 Volume 4 Number 1.

## Abstract

**Background:** Following a car accident, patient complains of hip and neck pain, and weakness in the right upper extremity. Evaluation in the emergency room, as well as radiographs revealed a normal cervical spine with mild degenerative changes. The following day, the patient complained of neck pain and bilateral hand numbness. Preparation for flexion-extension radiograph led to a complete anterior dislocation at C5-C6.

**Results:** Following anterior and posterior fusion of the cervical spine, Physical Therapy and Occupational Therapy evaluation revealed mild non-fatigable weakness of the bilateral upper extremities and negative neurological testing.

**Conclusion:** Initial physical examination did not reveal cervical spine pathology. However, physical and neurological examinations were incomplete. A proper diagnostic exam, including a detailed physical and neurological examination, as well as a proper series of diagnostic tests may have eliminated the possibility that the cervical spine injured patient would face the dire consequences of a severely unstable cervical spine.

## INTRODUCTION

Patients that sustain multiple injuries in traumatic accidents are susceptible to neglected spinal injuries. Neglected spinal injuries are defined as injuries not treated in a timely fashion and found late when options for care are limited<sup>1</sup>.

According to Sengupta<sup>1</sup>, this type of overlooked spinal injury is often associated with polytrauma or altered level of consciousness. However, he states that the overlooked diagnosis is largely preventable by adhering to appropriate protocols for clearing the cervical spine in a trauma patient.

Lin, Lee and Lee<sup>2</sup> state that a missed cervical spine fracture may potentially result in devastating consequences, and there has been much discussion on the appropriate management for patients with these fractures. Fracture with dislocation of the cervical spine presents even more complications, especially when the initial fracture is occult. One of the 68 radiographs that Lin et al<sup>2</sup> examined for occult fractures of the cervical spine contained a fracture dislocation of the C6-C7 level. However, the initial radiographs were negative for

fracture, except for evidence of a subtle disc space widening at the affected level. Of all the radiographs examined by the investigators, occult fractures in cervical spine fracture patients were missed on initial radiographs in 40% of the cases. The investigators suggest that radiographs are not 100% sensitive in ruling out fracture, and state that CT scan is clearly superior in imaging bony pathology. Furthermore, Sengupta<sup>1</sup> recommends the use of magnetic resonance imaging (MRI) in addition to radiograph and CT scan with their purpose to assess the integrity of the posterior ligament complex.

There remains controversy regarding the choice of appropriate diagnostic tests with regards to the cervical spine injury. Although Sengupta<sup>1</sup> stated that the standard of care included the use of flexion-extension radiographs, he did not recommend their use in the acute cervical spine injury secondary to the possible injury to the posterior ligamentous complex. Therefore, the recommendation has been made to include CT scan and MRI as routine diagnostic tests.

Hoffman et al<sup>3</sup> supports the use of a decision instrument based on clinical criteria which would assist physicians in reliably identifying patients requiring radiography after blunt trauma. Furthermore, Poonoose, Ravichandran and McClelland<sup>4</sup> report that inadequate neurologic assessment is a factor in missed and mismanaged injuries of the spinal cord.

The following case report describes the examination, treatment, outcomes, and mismanagement for a polytraumatic patient with neglected spinal injury, followed by complete cervical spine dislocation, subsequent reduction, and surgery, without serious or lingering neurological deficits. Many of the issues regarding the neglected or mismanaged cervical spine injury are addressed and contributed to this specific case.

## **CASE REPORT**

An 80 year-old man, following a head on collision car accident, was found lying on the ground with his head propped up by a pillow. Bystanders stated that the patient climbed out of his car independently and walked around at the scene of the accident, and then lay on the ground. Emergency medical personal arrived at the scene and found the patient alert and oriented, with complaints of right shoulder weakness and cervical spine pain. The patient was placed in a cervical collar, placed on a back-board and transported to the emergency room of the local trauma hospital.

Upon arrival to the emergency room approximately 20 minutes later, the patient was no longer complaining of cervical spine pain and right shoulder weakness, but instead was complaining of left hip pain. It was noted in the emergency room that the patient did not complain of any type of headache, neck pain, shortness of breath, chest pain, nausea, vomiting, abdominal pain, paralysis, or paresthesias.

The spine examination consisted of palpation along the dorsal aspect of the midline lumbar and cervical spine, which elicited no tenderness. The left hip and greater trochanter were painful to palpation and the patient resisted full hip extension. The left knee was effused but Apley's test was negative.

A brief, cursory neurological assessment was conducted. The results of the neurological exam concluded that the patient was oriented to person, place and time; that the patient exhibited no focal deficits, was alert, and had

appropriate affect; and that his memory was intact.

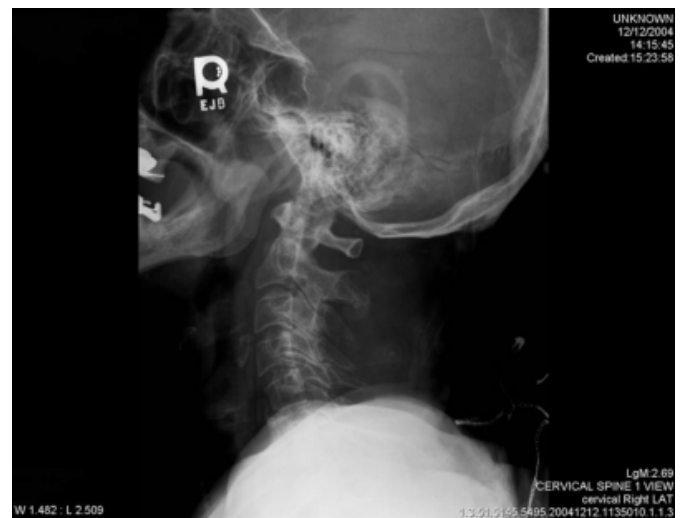In addition to cardiac monitoring and blood work, radiology orders consisted of neutral cervical spine radiographs as well as left femur, left hip and left pelvis radiographs.

Additionally, a Computed Tomography scan (CT scan) was ordered of the head, cervical spine, chest, abdomen, left femur, left hip and left pelvis.

Initial radiographs of the cervical spine revealed no definite fracture or dislocation, and the report stated that the prevertebral soft tissue appeared normal. (See Figure 1.) Additionally, the findings of the cervical spine CT scan reported no fracture or dislocation, no prevertebral abnormalities, and confirmed multilevel degenerative disc disease that was greatest at C5-C6 and C6-C7. Furthermore, CT scan findings stated that there was a very mild kyphosis at C5-C6, and that there was a loss of disc height with endplate sclerosis at C5-C6 and C6-C7. (See Figure 2.)

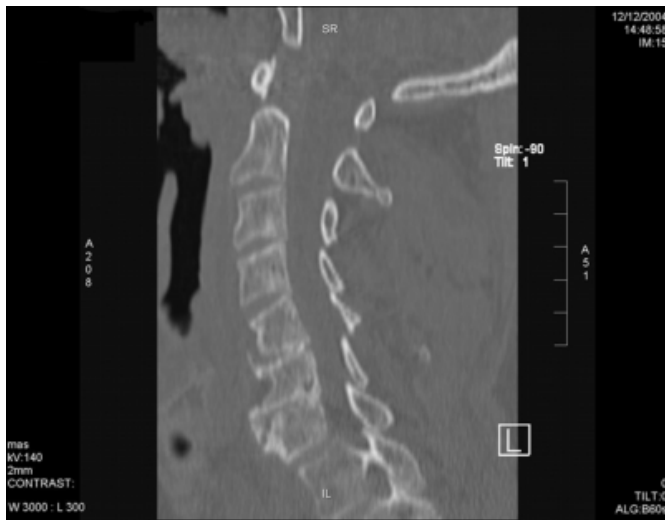## **Figure 1**

Figure 1: Initial lateral view cervical spine radiograph.



**Figure 2**

Figure 2: Initial Noncontrast CT image of cervical spine.



Based on the initial CT scan and radiograph, fracture or subluxation of the cervical spine was ruled out, with evidence of degenerative changes only. No MRI was performed at this point and, therefore, there was no evidence regarding the nature of any possible soft tissue injury. The doctors associated with the case questioned the likelihood of cervical spine injury versus degenerative changes of the cervical spine, but this was not addressed by the doctor again. Initial radiographic results indicated a posterior dislocation of the left femoral head, and the patient was referred to an orthopedic surgeon for evaluation and reduction of the left hip dislocation. The CT scan of all other systems was negative, and no other acute traumatic injuries were attributed to this patient.

Over the next 5 1/2 hours, while the patient was resting in an emergency room bed waiting for an orthopedic consultation regarding the injury to his left hip, he complained about mild numbness of the right hand. During the orthopedic consultation, the surgeon noted that the patient was wearing a cervical collar and stated that the patient had been complaining of numbness in his right hand, but that it had resolved on its own. The surgeon noted that the patient's bilateral upper extremities had full range of motion in the shoulders, elbows, wrists and hands and that he was neurovascularly intact.

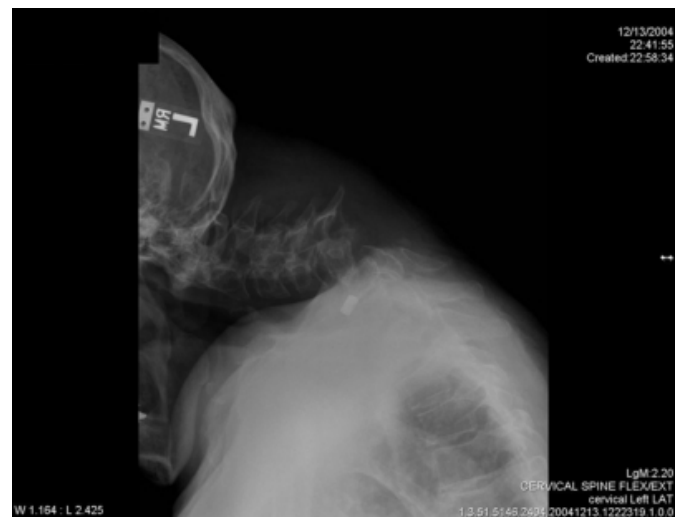
Upon examination of the left lower extremity, the surgeon noted that the left lower extremity was internally rotated and that pain was present with any attempt of range of motion of the left hip. Furthermore, he noted that the patient's distal gross motor and sensory function were intact for the left

lower extremity. The surgeon noted that radiographs and CT scan of the patient's left hip confirmed left posterior fracture dislocation, and therefore a reduction of the hip was required. Following the exam, the orthopedic surgeon manipulated and reduced the left hip without complication, and placed an abduction pillow between the patient's legs. A CT scan was ordered to further assess the extensive damage to the acetabulum and femur, and the degree of instability present that would require operative intervention.

The following morning, the patient was reported to be awake, not complaining of any neck pain. Results of the post reduction CT scan confirmed a left acetabular fracture that was in need of open reduction internal fixation, and the patient was scheduled for surgery. However, that evening the patient complained of "some neck pain and tingling in the hands and arms". A neurology consultation was requested and a flexion-extension radiographic view was ordered and subsequently scheduled for this patient. Upon initiation of flexion for the flexion-extension radiographic view, the patient experienced a complete dislocation of the C5-C6 cervical spine. Radiographic findings of the lateral radiograph of the cervical spine demonstrated a complete dislocation or dissociation at C5-C6. (See Figure 3.)

**Figure 3**

Figure 3: Cervical spine flexion and extension radiograph.

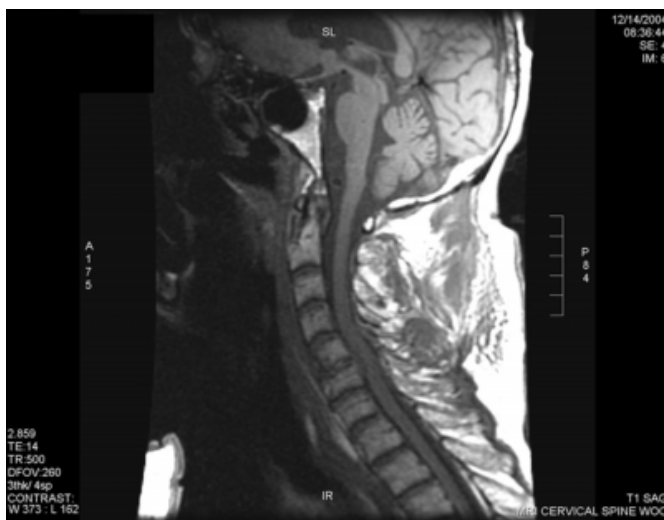

There was marked acute flexion angulation at C5-C6, with extreme widening of the interspinous distance at this level. The patient's cervical spine was realigned with a complete reduction of the cervical spine. The patient was then placed in a Philadelphia collar and started on a steroid protocol to control edema. On the following morning, an MRI confirmed complete reduction of the C5-C6 fracture

dislocation. The MRI films revealed severe multilevel degenerative changes in the facet joints and the vertebral body endplates at C2-C3, C3-C4, C4-C5, C5-C6, and C6-C7 levels. Additionally, spinal canal stenosis and mild cord edema were noted at the C5, C5-C6, and C6 levels with traumatic disruption of the C5-C6 intervertebral disc with posterior extrusion. Furthermore, it was noted that there was extensive prevertebral and posterior paraspinal soft tissue edema, and a clear disruption of the C5-C6 interspinous ligament. (See Figure 4.)

#### **Figure 4**

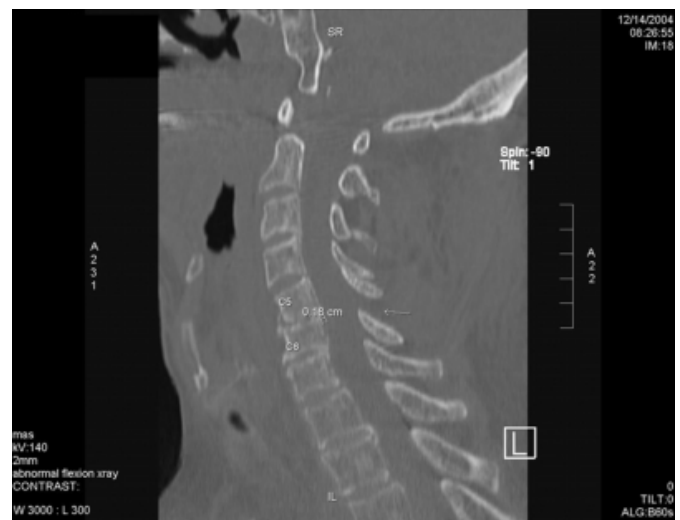Figure 4: MRI of cervical spine following reduction from C5-C6 dislocation.



A post-reduction CT scan of the cervical spine revealed sclerotic degenerative changes and narrowing at C5-C6, with a 2-millimeter retrolisthesis of C5 on C6. There was a widened separation between the spinous process of C5 and the superior portion of the spinous process of C6, of which the body was compressed by 20 percent. A small fragment of bone was noted dorsal to the interspinous distance between C5 and C6, consistent with an avulsion fracture of the C5-C6 spinous processes, and suggestive of a disruption of the interspinous ligament. Finally, there were nondisplaced fractures of the bilateral C5 facet joints. (See Figure 5.) When a comparison was made to the initial, pre-dislocation CT scan, images were considered similar, and both were consistent with hyperflexion injury of the cervical spine.

#### **Figure 5**

Figure 5: Repeat CT scan following reduction from C5-C6 dislocation.



Later that same morning, the patient continued to complain of generalized weakness and numbness but stated that his arms were much improved. He was found to be weaker in his right upper extremity than his left. The physician stated that the patient complained of generalized numbness in his arms, but that his symptoms had decreased and he was much better. The physician stated that the patient's cervical spine was immobilized, that his pupils and extraocular movements were intact, and that his face was symmetric. Further musculoskeletal examination revealed that the patient was able to use both upper extremities, and that the gross strength in the right upper extremity was 4/5, with the right hand at only 3/5. The patient's left hand function was 4/5 to 5/5, with the gross strength of the left upper extremity a 4/5 or 5/5. Right lower extremity strength was tested and considered to be 4/5 to 5/5. The patient's left leg was placed in long leg traction secondary to multiple trauma, and therefore was not tested. The patient was able to dorsiflex and plantarflex the feet and had good sensation and joint position sense bilaterally. Following review of all films and musculoskeletal exam, the patient was recommended for stabilization surgery of the cervical spine and was transferred to the intensive care unit. The decision was made to hold off on acetabular surgery until the cervical spine was stabilized with surgery.

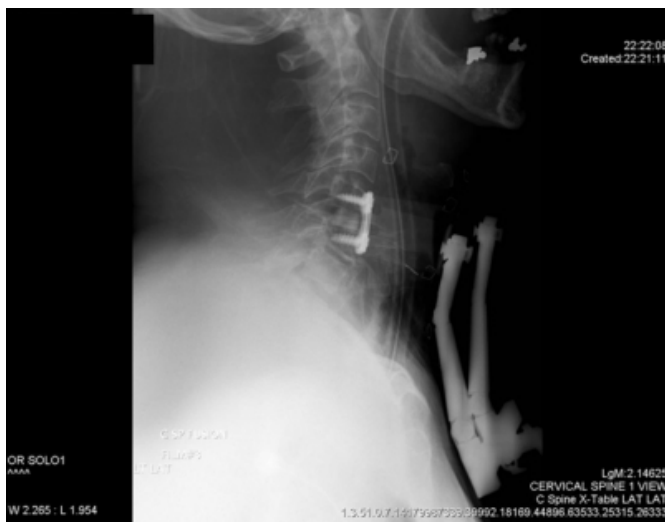The initial surgery was scheduled for the following day, 12/14/2004, and consisted of an anterior cervical discectomy, interbody arthrodesis with autograft and allograft, microscopic dissection of C5-C6 and cervical

plating with an Atlantis plate.

The patient was placed under general anesthesia and a repeat x-ray was performed on the patient to ensure that the surgical procedure would be performed on the correct level, and once the level was confirmed, an incision was made through the C5-C6 disc. The physician noted that the disc space was very narrow and that there were fractures, especially toward the lateral aspect of the vertebral bodies anteriorly, and the remaining disc material was removed. Additionally, the superior and inferior end plates were partially removed, and a significant uncinate process bone spur was found, and subsequently shaved down. Following this, the epidural space was now accessible and it was noted that there were small fragments of disc material behind the body of C6, as well as central vertebral osteophytes, all of which were removed. The remaining portion of the end plates were decorticated, and an 8 millimeter bone autograft, packed with bone shavings that had been saved from the shaved osteophytes, was countersunk into the superior surface of C6. An anterior plate was then secured to the anterior aspect of C5 and C6. (See Figure 6.)

#### Figure 6

Figure 6: Radiograph following anterior fusion of C5-C6 in the cervical spine.



Following surgery, a Philadelphia collar was placed on the patient. Conclusions regarding the nature of injury noted from the anterior approach included an endplate fracture and an epidural disc herniation.

Following anterior fusion of the cervical spine, it was found that the patient had good cervical alignment and would be prepared for a second surgery, involving posterior fusion of

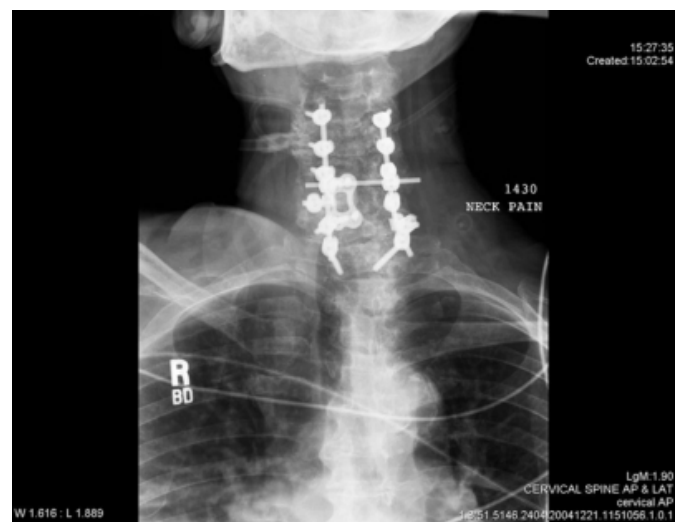C3-T1. Gross muscle testing at this time revealed 3/5 strength in bilateral upper extremities and bilateral lower extremities.

The posterior fusion of C3-T1 was performed the following day. The procedure involved cervical fusion from C3 to T1 using lateral mass screws at C3 to C7 and pedicle screws at T1. The procedure involved the use of an allograft and intraoperative fluoroscopy to guide the surgeon to the correct cervical spinal level.

Similar to the procedure for the anterior fusion, the patient was placed under general anesthesia. The patient was log rolled to a prone position, and an incision was made from approximately C2 to T2. At this point, the surgeons noted that the C5-C6 dislocation and separation was evident. Lateral mass screws were placed medial to the midpoint of the lateral mass on each side of the vertebral bodies. Next, T1 laminotomies were performed on either side of T1 and pedicle screws were placed in the pedicle. The lamina and the facet joints were decorticated and packed with allograft bone and all of the screws were tightened. (See Figure 7 and Figure 8.)

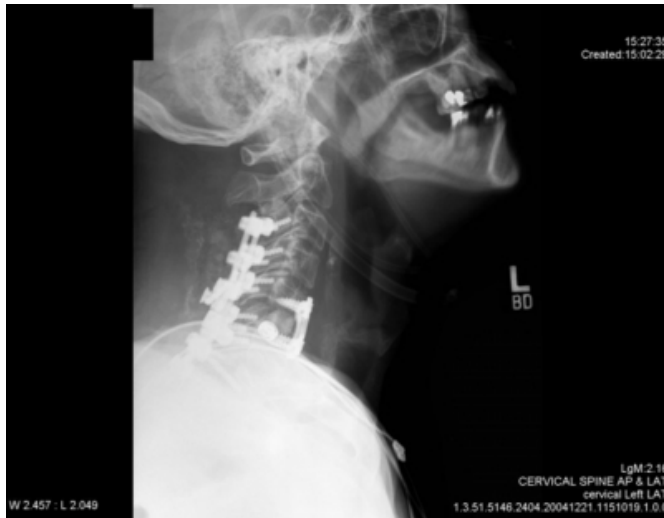#### Figure 7

Figure 7: Radiograph following posterior fusion of C3-T1 of the cervical spine.



**Figure 8**

Figure 8: Radiograph showing anterior fusion at C5-C6 and posterior fusion of C3-T1 of the cervical spine.



Following the posterior cervical fusion, it was noted that the patient continued to suffer from bilateral upper extremity weakness, with right weakness greater than left.

Furthermore, nursing noted that the patient exhibited a strong left hand grip but only a very slight right-hand grip, and he was able to raise his left and right upper extremities off the bed upon command.

Following surgery of the left hip, which involved open reduction and internal fixation 5 days post-trauma, and over the next 26 days, the patient's strength steadily improved with the help of physical therapy and occupational therapy. At his weakest point following all surgeries, the patient was graded at approximately 3+/5 in the right upper extremity, and a 4/5 in the left upper extremity, requiring assistance with grooming, self-care, and all transfers. During therapy, the patient's strength improved to the point that he was functioning independently with the bilateral upper extremities, and being challenged with resistive therapeutic exercise by the time of discharge. Additionally, he gained full independence in issues regarding grooming, self-care, and wheelchair propulsion. At discharge, the patient was non-ambulatory due to continuing issues regarding the left hip, so he was transferred to a long-term skilled nursing facility to address his specific hip needs. Although still wearing a Philadelphia collar for the cervical spine, the patient was no longer being actively followed by the neurosurgeon for his cervical spine.

Ten weeks following stabilization surgery, the patient had a follow up visit with his physician. At the time of this visit,

the patient's cervical spine had completely healed with no neurological deficits, and he was discharged from the physician's care. The patient's strength continued to improve with 4/5 to 4+/5 strength in the bilateral upper extremities and 5/5 in the right lower extremity.

## **DISCUSSION**

The initial physical examination on this patient did not reveal any type of cervical spine pathology. The initial radiographic and CT reports stated that there was no sign of fracture or dislocation. In fact, if this patient had not had a fractured and dislocated hip, he would have been sent home with no evidence of severe cervical spine pathology. Furthermore, in the event that he had been sent to physical therapy, the therapist would have been faced with a potentially serious situation. A proper differential diagnostic exam by the attending physician or trauma surgeon, including a much more detailed physical examination and a full neurological assessment was warranted to ensure this patients safety and proper medical management.

Poonnoose, Ravichandran and McClelland<sup>4</sup> investigated the incidence of missed and mismanaged injuries of the spinal cord, and attempted to identify the causes of failure to recognize vertebral column injuries in patients with coexisting significant neurologic deficit. The investigators examined medical records of 569 patients with neurologic deficits secondary to traumatic spinal cord injury. It was found that in 52 of the cases, the diagnosis was initially missed, with the time before recognition of the injury as short as 10 hours and as long as 6 weeks. Furthermore, 34 of the 52 missed cases underwent a therapeutic intervention that was inappropriate for their condition and therefore, was mismanaged by the referring hospital. The investigators identified several factors that contributed to a failure to identify a spinal column or spinal cord injury including ambience and circumstances surrounding the injury, inadequate neurologic assessment, associated injuries, and radiographic or radiodiagnostic errors. The investigators suggest that spinal cord injuries should be suspected in all cases of high velocity road traffic accidents. Additionally, the investigators recommend that a detailed motor and sensory examination including the perianal area is essential to exclude paralysis. They go on to suggest that neurologic deficits may be unrecognized if a systemic examination is not performed. The investigators state that brief and cryptic neurologic assessments made in the emergency department, implying that all groups of muscles have normal power or

sensation when a specific detailed examination was not carried out invites problems. The diagnosis of spinal cord injury is made on the basis of clinical examination, and thus a thorough examination is warranted. Associated injuries, including patients that are unconscious, have a head injury, are intoxicated, or are critically ill with multiple injuries can also contribute to the possible missed spinal cord injury. Finally, the investigators state that radiographic or radiodiagnostic errors contribute significantly to missed spinal column injuries. Lateral radiographic views alone are not adequate in determining the presence of fracture, and should be part of a series of 5 cervical spine radiographs to improve the diagnostic accuracy derived from radiographs. The investigators recommend the series to include anteroposterior, lateral, 2 different oblique views, and open mouth views. Additionally, the investigators state that immediate post-trauma flexion-extension views are inappropriate and impractical, and may lead to further neurologic deterioration. Dynamic views obtained prematurely can precipitate spinal cord injury, and should only be carried out 2 to 6 weeks after injury. However, if a 2 to 6 week delay is not practical, then it is suggested that a computed tomographic scanning or MRI be performed to rule out bony or ligamentous instability.

Harris <sup>5</sup> states that the statistics are alarming regarding the increased incidence of missed cervical spine injuries, and that there has been a more than doubling of the incidence of missed cervical spinal cord injuries during the past decade. Harris suggests that the primary attending physician or trauma surgeon in the emergency setting must maintain an active and high degree of suspicion regarding the possibility of spinal cord injury in all blunt trauma patients. Additionally, he believes that the attending physician should perform and accurately document a neurologic examination appropriate to the patient's clinical condition. Harris proposes that the physician should rely on radiographic, orthopedic and neurosurgical consultants for accurate diagnosis. Harris states that one should be mindful of a "negative" conventional radiographic examination in the presence of an abnormal clinical evaluation, thus requiring further diagnostic tests, including CT scan or MRI. Finally, Harris states that the flexion-extension view should never be used to determine stability or instability of a cervical spine injury, especially in the acute cervical spine injury.

Sengupta <sup>1</sup> suggests that secondary to the limitation of plain radiographs, the standard of care has shifted to include the

use of flexion-extension radiographs, CT scan and MRI to evaluate for subtle cervical spine injury. However, he states that flexion-extension views should never be used to determine stability of a cervical spine injury, with their purpose to assess the integrity of the posterior ligament complex. Furthermore, it is suggested that one should wait 1 to 2 weeks after trauma before performing the flexion-extension view, and that patients should be evaluated with an MRI scan or treated with a hard cervical orthosis.

With the diagnostic examinations available today, and the degree of unknown ligamentous injury that may be present, the safest and most appropriate series of tests would seem to be a combination of the recommended series of 5 radiographs from Poonnoose, Ravichandran and McClelland <sup>4</sup>, with CT scan and MRI evaluation, engaging in no dynamic testing. Madhavan et al <sup>6</sup> state that the incidence of unstable injuries to the cervical spine is approximately 30 per million of the population per year. Secondary to the rare nature of the unstable cervical spine injury, as well as the degree with which the injury is missed, the judicious use of diagnostic exams is warranted.

Crim, Moore and Brodke <sup>7</sup> investigated the role of advanced imaging in the clearance of the cervical spine in multitrauma patients. The investigators state that flexion-extension radiographs have unacceptably high false positive and false negative rates. Additionally, they suggest that although the CT scan is superior in detecting fracture, its accuracy in detection of ligamentous injuries has not been documented. The investigators state that the MRI is highly sensitive in the detection of ligamentous injury and should therefore be used in conjunction with other diagnostic exams.

Furthermore, the use of MRI has been suggested as an essential tool before reduction of a cervical spine dislocation. Vaccaro et al <sup>8</sup> studied MRI evaluation of the intervertebral disc, spinal ligaments, and spinal cord before and after closed traction reduction of cervical spine dislocations. The investigators suggest that cervical spine dislocation is frequently associated with neurologic deficits and that treatment of these injuries through open or closed reduction has occasionally resulted in permanent neurologic worsening. The neurologic worsening has been attributed to the possibility that reduction of the cervical spine increase the amount of intervertebral disc herniation into the spinal cord. The purpose of the study was to determine the incidence of disc herniations, before and after closed reduction of cervical dislocations, and to study changes to

the intervertebral disc, spinal cord, and spinal ligaments that occur with closed reduction.

The investigation involved 11 patients, 9 with bilateral and 2 with unilateral facet dislocation. All patients received a pre-reduction MRI that was helpful in detecting cervical disc herniations, ligamentous disruption and spinal cord edema. Following reduction of the cervical spine, a second MRI was performed. The relative size of disc herniations was compared on pre-reduction and post-reduction scans, and a determination was made considering the change in herniation size. The investigators identified cervical spine disc herniations in only 2 of 11 patients before closed reduction was performed. Following reduction, 5 patients had cervical spine disc herniation. Although not considered statistically significant secondary to the small patient population, the conclusion was made that cervical spine intervertebral disc herniations were more common after closed reduction than before reduction of cervical spine dislocation.

Hart<sup>9</sup> questioned the use of MRI following cervical facet dislocation. He states that the decision making process about the use of MRI before treatment is initiated involves a discussion concerning the importance of the stakes to the patient versus the odds of further injury. Hart states that rupture of the posterior longitudinal ligament and intervertebral disc annulus has been demonstrated to be extremely common following facet dislocation, and the choice of not obtaining pre-reduction MRI with patients with preserved neurologic function involves a high stakes gamble. Furthermore, Hart states that he believes that the question of whether to obtain a pre-reduction MRI depends on the patient's neurologic status. For example, in patients with nearly complete spinal cord injury, immediate reduction of the dislocation is the most appropriate treatment to aid in the possibility of recovery of neurologic function. However, patients with less neurologic injury are more difficult when it comes to appropriate management of their dislocation. The potential to cause further neurologic injury has been documented, whereas the detrimental affects of delay in reduction needed to obtain an MRI are less clear. Therefore, it is believed that once a better understanding of the extent of the injury has been determined by MRI, then a more appropriate course of treatment can be developed.

## **CONCLUSION**

The circumstances surrounding the cervical spine injury, inadequate neurologic assessment, associated injuries, and

radiographic or radiodiagnostic errors have been identified as the most likely reasons that a cervical spine or spinal cord injury would be missed, and consequently mismanaged. The circumstances surrounding the patient detailed in this case further strengthen these assertions. The diagnosis of spinal cord injury should be made on the basis of a thorough clinical examination, including detailed motor and sensory assessment, as well as the aid of diagnostic tests.

Inadequate neurological testing, along with radiographic errors have been well documented to lead to diagnostic errors regarding cervical spine injuries. Therefore, it is recommended that the practitioner follow strict clearing protocols for the cervical spine, including a complete neurological assessment, along with the use of a decision instrument that may include a combination of diagnostics and consultation with several specialists to aid in the most appropriate treatment of the cervical spine injury.

Furthermore, it is suggested that in addition to a more detailed neurological examination, that the practitioner be sensitized to the possibility of cervical spine or spinal cord injuries in all cases of high velocity road traffic accidents or blunt trauma injuries to the cervical spine.

If a complete physical and neurological examination has identified abnormal clinical findings, a negative conventional radiographic examination should be looked at with suspicion, and therefore further diagnostic testing involving CT scan and MRI is warranted. A combination of several radiographic views, with the CT and MRI, gives the practitioner the best chance of diagnostic accuracy. However, immediate post-trauma flexion-extension views are considered inappropriate and can precipitate spinal cord injury

If the patient detailed in this case had not fractured and dislocated his hip, he could possibly have been sent home or to rehabilitation with no evidence of severe cervical spine pathology. In the event that he had been sent to physical therapy for hip rehabilitation or possibly cervical spine rehabilitation, the therapist would have been faced with a potentially serious situation.

It has been revealed that up to 40% of cervical spine injuries are missed upon initial radiograph<sup>2</sup>. Therefore, there is a relatively high possibility that a patient with severe cervical spine pathology will go home or to physical therapy without an accurate diagnosis of pathology. This emphasizes the importance of an appropriate and complete differential



diagnostic examination performed by the practitioner to eliminate the possibility that the cervical spine injured patient would face the dire consequences of a severely unstable cervical spine.

## **ACKNOWLEDGEMENT**

I would like to give special thanks for all of the hard work with editing and advice to Dr. Sharon Olson, PhD, Director of Texas Woman's University School of Physical Therapy.

## **References**

1. Sengupta DK. Neglected spinal injuries. Clin Orthop Relat Res. 2005 Feb;(431):93-103.
2. Lin JT, Lee JL, Lee ST. Evaluation of occult cervical spine fractures on radiographs and CT. Emerg Radiol. 2003 Dec;10(3):128-34. Epub 2003 Apr 18.
3. Hoffman JR, Mower WR, Wolfson AB, Todd KH, Zucker MI. Validity of a set of clinical criteria to rule out injury to the cervical spine in patients with blunt trauma. National Emergency X-Radiography Utilization Study Group. N Engl J Med. 2000 Jul 13;343(2):94-9.
4. Poonnoose PM, Ravichandran G, McClelland MR. Missed and mismanaged injuries of the spinal cord. J Trauma. 2002 Aug;53(2):314-20.
5. Harris JH Jr. Missed cervical spinal cord injuries. J Trauma. 2002 Aug;53(2):392-3.
6. Madhavan P, Monk J, Wilson-MacDonald J, Fairbank J. Instability due to unrecognised fracture-subluxations after apparently isolated injuries of the cervical spine. J Bone Joint Surg Br. 2001 May;83(4):486-90.
7. Crim JR, Moore K, Brodke D. Clearance of the cervical spine in multitrauma patients: the role of advanced imaging. Semin Ultrasound CT MR. 2001 Aug;22(4):283-305.
8. Vaccaro AR, Falatyn SP, Flanders AE, Balderston RA, Northrup BE, Cotler JM. Magnetic resonance evaluation of the intervertebral disc, spinal ligaments, and spinal cord before and after closed traction reduction of cervical spine dislocations. Spine. 1999 Jun 15;24(12):1210-7.
9. Hart RA. Cervical facet dislocation: when is magnetic resonance imaging indicated? Spine. 2002 Jan 1;27(1):116-7.

**Author Information**

**R. David Clubb, PT, MS, PhDc, OCS**

Methodist Dallas Medical Center, Texas Woman's University