

Brachial Plexus Compression Neuropathy: A Rare Complication Of Warfarin Therapy

N Barua, K Mahmood

Citation

N Barua, K Mahmood. *Brachial Plexus Compression Neuropathy: A Rare Complication Of Warfarin Therapy*. The Internet Journal of Internal Medicine. 2004 Volume 5 Number 2.

Abstract

Anticoagulant medications have been widely used since the 1960s. Patients benefiting from advances in anticoagulant therapy include those with prosthetic heart valves, who require lifelong anticoagulation in order to prevent the potentially devastating consequences of clot formation. We present the case of a patient requiring warfarin for a prosthetic heart valve who developed brachial plexus compression as a result of a haematoma, in the absence of trauma or over-anticoagulation.

CASE REPORT

An 82-year-old woman with a history of aortic valve replacement was admitted with infectious gastroenteritis and arthralgia. Her symptoms were managed conservatively with simple analgesia and physiotherapy – NSAIDs (non-steroidal anti-inflammatory drugs) were not prescribed in view of warfarin therapy.

On the fourth day of admission an area of bruising was noted along the medial aspect of the patient's right arm which was attributed to venepuncture. Over the next 24 hours the bruising extended to involve the entire medial surface of the arm. Urgent coagulation studies revealed an INR (International Normalised Ratio) of 2.41, which was below the target range of 2.5 to 3.5.

The following morning the patient complained of throbbing pain throughout her right arm. On examination, a non-fluctuant swelling, approximately five centimetres in diameter, was palpable on the medial aspect of her upper arm. At this time the motor and sensory function of the right hand was intact. Repeated coagulation studies indicated an INR of 2.74 – within the intended therapeutic range.

Urgent ultrasound imaging revealed an 8 x 3 centimetre haematoma [fig.1], and visible bleeding from a small artery as well as a larger more proximal vessel [fig.2]. A vascular surgical opinion was sought, and it was decided that as the patient had intact distal neurological function, that she should be managed conservatively with analgesia and close observation of distal motor function. As the INR at this point was 2.74, warfarin was omitted, but no attempt was made to

reverse the anticoagulation in view of her prosthetic heart valve.

Figure 1

Figure 1: Ultrasound image – 8 x 3cm haematoma

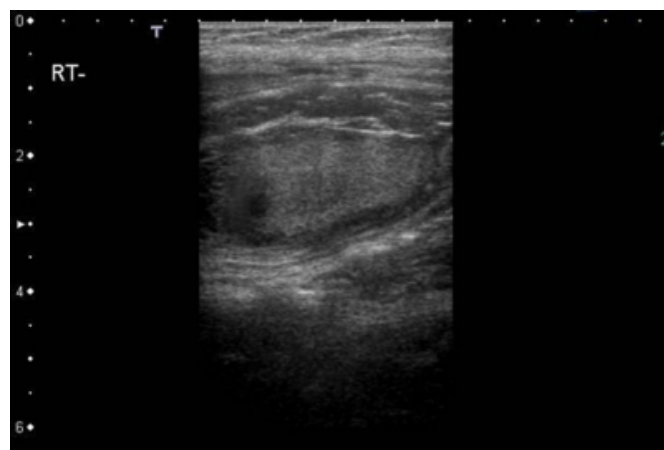
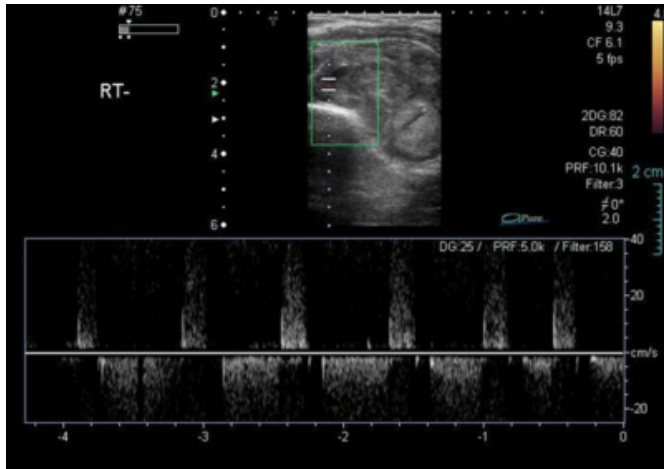


Figure 2

Figure 2: Ultrasound image – Doppler study indicating arterial flow



Over the next 12 hours the patient developed weakness of her right hand. Examination revealed weak thumb flexion, and absent finger flexion. Finger and wrist extension was painful, but intact. Sensation of the palmar aspect of the right hand was significantly reduced.

In view of the onset of neurological symptoms indicative of active brachial plexus compression, surgical evacuation of the haematoma was undertaken. A large haematoma posterior to the neurovascular bundle and biceps was removed, but no active source of bleeding was identified. The deep fascial layers were left open to prevent further compression in the event of recurrent bleeding.

Signs of recovery of motor function were apparent by the second post-operative day, with the patient able to flex and extend the wrist. Motor function continued to improve with physiotherapy. Unfortunately, sensory recovery of the palmar aspect of the right hand was minimal, despite surgical decompression within 24 hours of the onset of neurological dysfunction.

DISCUSSION

Compression neuropathy as a complication of anticoagulant therapy is a rare occurrence. A review of 79 cases of compressive neuropathy associated with anticoagulant use by Hoyt et al.¹, demonstrated compressive neuropathy to be more common in the lower limbs (87%), more common with heparin (45%) than warfarin therapy (18%), and most frequent when outside of the intended therapeutic range of anticoagulation (60%).

Of the few cases reported in the English literature, brachial

plexus compression appears most common in the context of trauma¹, over-anticoagulation², and following arteriography^{3,4} or jugular puncture⁵.

Hoyt et al.¹ report the case of a 61-year-old man on warfarin, who developed a wrist drop after falling onto his outstretched right arm, which resolved after surgical evacuation of the haematoma. Elseber et al.² report the case of a 69-year-old woman on heparin after a stroke, who developed compressive neuropathy of the brachial plexus and long thoracic nerve. Coagulation studies demonstrated a prolonged activated partial thromboplastin time (APTT), above the intended therapeutic range. As the patient had only mild neurological deficit, she was treated conservatively with discontinuation of heparin.

Only one reported case of spontaneous brachial plexus haemorrhage was found, in a 48-year-old jackhammer operator⁶. The authors postulate that haemorrhage was likely to be the result of indirect trauma from use of the jackhammer. This patient was also treated conservatively with analgesia and observation.

Severity of pain, motor and sensory dysfunction, and progression of neurological deficits are the key factors when deciding whether a patient requires surgical decompression. The timing of intervention is paramount - in one review, surgical drainage within 48 hours of the onset of neurological symptoms led to improvement in 100% of patients. This number fell to 50% when intervention was delayed beyond 48 hours¹.

A review of brachial plexus neuropathy after arteriography by O'Keefe³, showed that severe residual deficits remained in 6 of 9 patients in whom surgical decompression was delayed beyond 24 hours of the onset of motor dysfunction. A review of 5 cases of brachial plexus compression following arteriography⁴, demonstrated that the clinical response to surgery was most marked when drainage was undertaken within 24 hours of the onset of nerve paresis.

CONCLUSION

Compressive neuropathy is a rare complication of anticoagulation, which can occur when patients are within the intended range of anticoagulant therapy, and in the absence of overt trauma. Clinicians need to be aware of the significance of unexpected bruising, pain and neurological weakness in anticoagulated patients, as prevention of permanent neurological deficit depends on early decompression. Persistent, severe or progressive

neurological deficits require urgent intervention, as recovery is most likely when decompression is achieved within 24 hours of the onset of neurological dysfunction.

ACKNOWLEDGEMENTS

Ultrasound images courtesy of Dr S. Vinayakamurthy, Department of Radiology, Queens Medical Centre, Nottingham.

References

1. Hoyt TE, Tiwari R, Kusske JA. Compressive neuropathy as a complication of anticoagulant therapy. *Neurosurgery* 1983;12:268-271
2. Elseber AA, Kent PD, Jennings CA. Compressive neuropathy of the brachial plexus and long thoracic nerve. A rare complication of heparin anticoagulation. *Chest* 2001;120:309-311
3. O'Keefe DM. Brachial plexus injury following axillary arteriography. Case report and review of the literature. *J Neurosurg* 1980;53:853-857
4. Molnar W, Paul DJ. Complications of axillary arteriotomies. An analysis of 1,762 consecutive studies. *Radiology* 1972;104:269-276
5. Fuller GN, Dick JPR, Colquhoun IR. Brachial plexus compression by haematoma following jugular puncture. *Neurology* 1994;44:775-776
6. Heller AC, Keuther T, Barnwell SL, Nesbit G, Wayson KA. Spontaneous brachial plexus haemorrhage - case report. *Surg Neurol* 2000;53:356-359

Author Information

Neil Barua, BMBS

Department of Cardiovascular Medicine, Queens Medical Centre

Khalid Mahmood, MBBS

Department of Cardiovascular Medicine, Queens Medical Centre