

An unusual cause of small bowel perforation. Has anything changed?

T Allsopp, G Fraser-Kirk

Citation

T Allsopp, G Fraser-Kirk. *An unusual cause of small bowel perforation. Has anything changed?.* The Internet Journal of Surgery. 2009 Volume 23 Number 2.

Abstract

Foreign body ingestion can be a frequent cause for presentation to the emergency department for all populations of patients. While paediatric patients generally account for the greatest percentage of this presenting cohort, people with psychiatric conditions, alcohol impairment, visual impairment, poorly fitting dentures and the elderly may uncommonly present^{1,2,3,4,5}. It is estimated that up to 90% of ingested foreign bodies will pass spontaneously with only 8-20% requiring endoscopic retrieval^{1,3,4} and 1% requiring surgical intervention⁵. We report below an unusual case of accidental ingestion of a bread clip causing small bowel perforation in a healthy young man.

CASE REPORT

A 32-year-old man presented to a small hospital in rural Australia on the 3rd October 2009, with a twenty-hour history of severe and constant colicky right-sided abdominal pain. He had associated nausea but no vomiting and his bowels had reportedly opened normally the previous day. His past medical history included a spontaneous pneumothorax and pleurodesis and previously treated hepatitis C. At presentation he was afebrile, normotensive, but required oxygen supplementation to maintain appropriate saturations. He displayed maximal tenderness over McBurney's point with associated rebound and rigidity, and was transferred to a regional hospital for surgical intervention of presumptive acute appendicitis.

On arrival at Toowoomba Hospital (Queensland, Australia) he was in obvious distress, febrile at 38.2 degrees Celsius, tachycardic (130bpm) and still requiring large oxygen flow rates to maintain normal saturation. On examination at this time he had a rigid abdomen with associated rebound tenderness, abdominal distension, involuntary guarding and maximal tenderness in the right iliac fossa. On further questioning he reported a four-week history of intermittent right upper quadrant abdominal pain and pleuritic chest pain. This had previously been treated as lower respiratory tract infection with oral antibiotics.

An erect chest x-ray revealed free air under the diaphragm with no evidence of consolidation or pneumonia. Further

investigations showed no leukocytosis (white cell count $7.4 \times 10^9/L$) and an otherwise normal full blood count and biochemistry. A presumptive diagnosis of perforated acute appendicitis was made and the patient proceeded to theatre for laparoscopy.

Intra-operatively, significant turbid fluid and pus were seen throughout the abdomen. The appendix was identified and macroscopically normal but the patient was also seen to have intra-abdominal inflammatory adhesions. The procedure was immediately converted to a laparotomy and the small bowel was examined. An obvious perforation and an entrapped foreign body were identified in the mid ileum. The section of ileum showed local inflammation and an inter-loop collection. A small bowel resection and anastomosis was performed via an endo-luminal stapler and a thorough abdominal washout was completed.

Post-operative recovery was complicated by basal atelectasis and consolidation, continuing abdominal pain, superficial midline laparotomy wound dehiscence and early ileus. He was subsequently treated with intravenous antibiotics, incentive spirometry, wound packing and analgesia. Despite continual abdominal pain, no further abdominal collections were identified on computed tomography. He was eventually discharged home eighteen days after initial presentation to hospital.

Macroscopically, the foreign body was identified as a

plastic bread clip embedded in the small bowel wall with focal perforation through an area of haemorrhage and induration (Figure 1). In close proximity to the perforation was a site of ulceration and a pale linear scar extending 40mm proximally over the mucosal surface from the offending bread clip. Microscopically, the site of perforation was lined by necro-inflammatory slough, inflamed granulation tissue and scar. Interestingly, the plastic bread clip was found to be dated “3rd October 2005” which was four years prior to his presentation. As the patient did not recall ever ingesting the foreign body, it is difficult to determine the exact time it spent in the gastro-intestinal tract. Given though the proximal mucosal scar, intra-operative findings, granulation tissue and the scar at the site of perforation, we believe it to have been at least several days.

Figure 1

Figure 1: The mucosal surface of the mid ileum showing the impaction of the foreign body (A). Note the serosal surface and site of perforation demonstrated by the arrow (B)

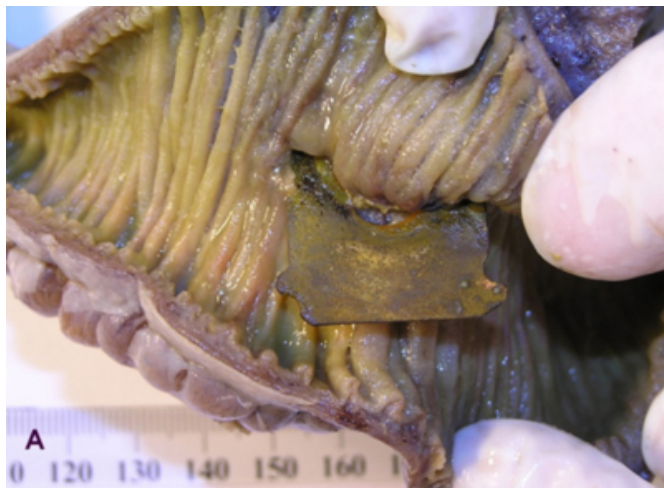
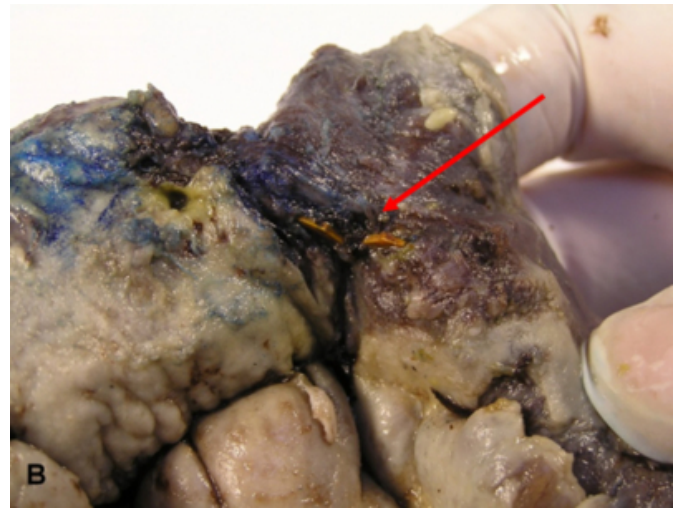

Figure 2



DISCUSSION

Foreign body ingestion rarely can cause substantial morbidity and complications. It is estimated that in the United States, approximately 1500 people die per year from foreign body ingestion into the gastrointestinal tract¹. One such foreign body that has previously been documented to cause local complications, as far back as 1983-1984, is the bread clip⁶. Previously documented rare complications include death^{7,8} and local complications; perforation, gastrointestinal bleeding, obstruction, colonic impaction and dysphagia^{1,2,6,9,10,11}. It is estimated that the risk of perforation from any foreign body in the gastrointestinal system is around 1%⁵.

Currently in Australia, bread clips are plastic non-degradable clips with sharp edges and a clasp design. They are used to seal plastic bread bags (Figure 2).

Figure 3

Figure 2: Close up of the ingested foreign body detailing the expiry date



Ingestion of bread clips make up an extremely small percentage of all ingested foreign bodies. To date there have been 24 cases of bread clips discovered in the gastrointestinal system¹ requiring different degrees of intervention. Unfortunately, as the patient is often unaware of ingestion and the clips are often not apparent on x-ray or CT, presentation often does not occur until a complication arises. There have also been documented cases of a bread clips being found incidentally during surgery or at autopsy^{2,7,12}.

While there have been several previous case reports demonstrating small bowel perforation from a bread clip, we believe this case has several pertinent not previously documented points. Previously, it was suggested that the elderly population is more prone to accidental ingestion due to poorly fitting dentures with possible contribution from visual impairment and cognitive impairment^{1,2,6,8}. This is the youngest documented person to have accidentally ingested a bread clip with normal intra-oral sensation, full dentition and no visual or cognitive impairment.

In addition, this is only the second dated bread clip documented to have caused perforation and it is older than the clip dated by Tang et al.¹⁰. Unfortunately, as in the case documented by Tang et al., it is impossible to accurately determine how long the bread clip had been present in this patient. Although the bread clip was dated “October 2005”, it could have been present from several days up to four years given the patient was unaware of ingestion.

From review of the documented cases in the literature, it is apparent that the small bowel appears to be the most common site of impaction and perforation². Newell et al. propose that the mechanism of entrapment is that the irregularly folded mucosa of the small bowel mucosa becomes trapped in the teeth of the bread clip. This then acts as a one-way valve, entrapping more small-bowel mucosa and leading to erosion and perforation². From the macroscopic appearance of our specimen, we postulate that this is the mechanism for our patient’s perforation. Bundred et al. have also proposed that failure to grasp the full thickness of the wall results in necrosis and sloughing of the mucosa thereby releasing the clip to attach again distally⁶.

Interestingly, in our patient the macroscopic histopathological appearance suggested an ulcerated area adjacent to the clip and a pale linear scar extending 40mm proximally from the clip. We therefore propose that in this case, the entrapment of the mucosa of the small bowel was initially superficial and in some areas may have resulted in necrosis and release of the entrapped foreign body. This adds further belief to the theory that the bread clip had been ingested a considerable time prior to presentation.

While endoscopic removal of foreign bodies is now seen as ideal treatment, unfortunately bread clips present a difficult problem. Given the often strong entrapment between mucosa and bread clip, location of entrapment and late presentation, at present endoscopic retrieval has limitations. So far, endoscopic removal has only been successful when a bread clip is known to have been ingested and intervention can be performed early^{1,3}. As most patients unknowingly ingest the bread clip and only present after complications, laparotomy is often still a required intervention.

A previously suggested hypothesis regarding the frequency of small-bowel impaction involves the size of the bread clip. It is thought that impaction often occurs in this location as the width of the bread clip most closely approximates the diameter of the small bowel². One interesting point to note from the previously documented cases is that the sensitivity of x-ray and computed tomography in identifying the bread clip appears to be poor^{1,2,9,10}.

Given that multiple suggestions have been made in the past in literature and directly to the bread bag clip manufactures, we were amazed to see that this totally preventable incident continues to occur. We wish to acknowledge our support of previous documented recommendations including:

- Bread clips should be made of biodegradable material^{1,10}.
- Identification could be made easier with a radio-opaque marker built into the bread clip that would be apparent on x-ray or CT-scan^{1,9,10}.
- The bread clip shape could be modified to prevent the edges and teeth from catching the bowel wall^{1,10}.
- The size of the bread clip could be increased to allow more likely identification prior to swallowing^{1,10}.
- Bread clips could be eliminated by using another sealing mechanism ^{8, 10} for example a sealing tape¹¹.

Impaction or perforation of a foreign body should always be considered in patients who present with an acute abdomen or unexplained gastrointestinal bleeding. Ideally, given the potential for morbidity and mortality, we advise that bread clips should be eliminated or re-designed completely.

References

1. Morrissey SK, Thakkar SJ, Lance Weaver M, Farah K: Bread bag clip ingestion: A rare cause of upper

gastrointestinal bleeding. *Gastroenterology and Hepatology*; 2008; 4 (7): 499- 500.

2. Newell KJ, Taylor B, Walton JC, Tweedie EJ: Plastic bread-bag clips in the gastrointestinal tract: report of 5 cases and review of the literature. *Canadian Medical Association Journal*; 2000; 162 (4): 527-529.

3. McKinley JM, Brady PG: Bread bag clip: Kitchen aid or gastrointestinal barricade? *Gastroenterology and Hepatology*; 2008; 4 (7): 501- 502.

4. Wong KKY, Fang CX, Tam PKH: Selective upper endoscopy for foreign body ingestion in children: an evaluation of management protocol after 282 cases. *Journal of Paediatric Surgery*; 2006; 41: 2016- 2018.

5. Katsinelos P, Kountouras J, Paroutoglou G, et al.: Endoscopic techniques and management of foreign body ingestion and food bolus impaction in the upper gastrointestinal tract: A retrospective analysis of 139 cases. *Journal of Clinical Gastroenterology*; 2006; 40 (9): 784- 789.

6. Bundred NJ, Blackie RAS, Kingsnorth AN, Eremin O: Hidden dangers of sliced bread. *British Medical Journal*; 1984; 288: 1723-1724

7. Guindi MM, Troster MM, Walley VM: Three cases of an unusual foreign body in small bowel. *Gastrointestinal Radiology*; 1987; 12: 240-242.

8. Beer TW: Fatalities from bread tag ingestion. *The Medical Journal of Australia*; 2002; 176 (10): 506.

9. McDonald S, Rusnak C: Plastic bread-bag clips: the saga continues. *Canadian Medical Association Journal*; 2000; 163(1): 16.

10. Tang APH, Kong AB, Walsh D, Verma R: Small bowel perforation due to a plastic bread clip: The case for clip redesign. *ANZ Journal of Surgery*; 2005; 75: 360-362.

11. Ellul JP, Hodgkinson PD: Problems with a plastic bread-bag clip. *Archives Emergency Medicine*; 1989; 6: 156-157

12. Cook DS: Dietary dangers: ingestion of a bread bag clip. *Journal of Clinical Pathology*; 2001; 54: 79.

Author Information

T. Allsopp

Department of General Surgery, The Toowoomba Hospital, Toowoomba, Queensland, Australia

G. Fraser-Kirk

Department of General Surgery, The Toowoomba Hospital, Toowoomba, Queensland, Australia