

# A 48-Year-Old Man With An Excruciating Pain In His Left Knee

I Sioutis, G Vasileiadis, P Papagelopoulos

## Citation

I Sioutis, G Vasileiadis, P Papagelopoulos. *A 48-Year-Old Man With An Excruciating Pain In His Left Knee*. The Internet Journal of Rehabilitation. 2009 Volume 1 Number 1.

## Abstract

A man is complaining for pain in both medial and lateral femoral of his left lower limb especially during knee flexion. His is not suffering from any disease and his laboratory tests are unremarkable. During the physical examination, he has a positive Ober's test. In the MRI a minute fracture in the joint surface was revealed. The final diagnosis of his condition is that of spontaneous osteonecrosis of the knee (SPONK) complicated by iliotibial band syndrome. After 5 months of conservative treatment he is able to walk for short distances without feeling any pain. It is important to differentiate between the 2 separate entities, SPONK and secondary osteonecrosis, in order to treat each disease appropriately. For SPONK conservative treatment has good results, while for secondary osteonecrosis a surgical solution should be preferred.

## BACKGROUND

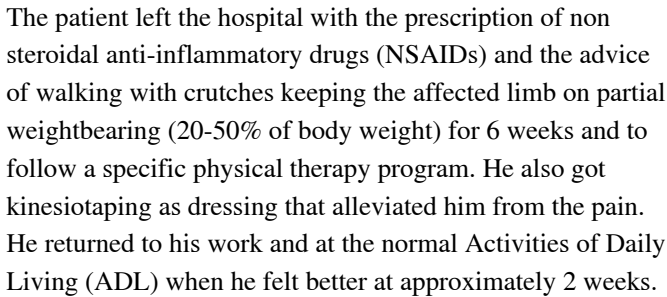
A 48-year-old man presents to the outpatient department of the orthopaedic clinic complaining for an excruciating pain in the area of both medial and lateral femoral condyles of his left lower limb. The symptoms begun from the medial condyle nearly a month ago but during the last 3-4 days the painful sensation is more intense in the region of the lateral condyle. He reports that the pain is not constant during normal walking and that it is aggravated when he is climbing up or down the stairs. The patient is doing a sedentary work and he spends a lot of time in front of a computer. He doesn't remember to have injured his knee recently. He is not suffering from any other disease or allergy and he is not under any medication. He is a smoker of 20 cigarettes a day.

On physical examination, the general appearance of the patient was normal with a heart rate of 80 bpm, blood pressure of 130/82 mm Hg, a respiratory rate of 12 breaths/min, and a temperature of 98.6°F (37.0°C). His musculoskeletal system appears normal and only a slight effusion in the left knee was revealed without any noticeable muscular atrophy or skin discoloration. The girth measurement of the left knee was slightly bigger than that of the right knee (42 cm versus 40 cm) at the level of the patella. Measurements taken 5 cm and 20 cm proximal to the base of the patella and 15 cm distal to the apex of the patella were practically the same for both knees and in the normal range. During palpation pain was elicited over the area of the

medial femoral condyle especially during knee flexion. This pain was radiating over to the lateral femoral condyle. There was a painful restriction of knee's flexion while the strength testing was found normal for both knee flexion and extension. The Ober's test was performed and was found positive.

Routine laboratory tests were performed in order to rule out any autoimmune or infectious disease. The X-ray of the knee was found also normal. In the MRI examination that was performed subsequently, edema was revealed as well as a minute fracture in the joint surface which exactly corresponds to the painful area (Figure 1).

Figure 1



## Figure 2

Combine the already given information that the patient is doing a sedentary work and he spends a lot of time in front of a computer with the second image in the MRI scan.

The patient is suffering from spontaneous osteonecrosis of the knee (SPONK) complicated by iliotibial band syndrome (ITBS).

The reason that led the patient with this problem to search out for a medical opinion was the tremendous amount of pain. Initially, no abnormalities were seen in the plain radiographs. The first abnormalities were depicted on the first MRI scan, in the form of bone marrow edema and a minute fracture in the joint surface of the medial condyle. This fracture on the subsequent MRI performed was enlarged ( $2.2 \times 3 \text{ cm}^2$ ). The site of the lesion is important for the differential diagnosis. In SPONK usually the lesions are recognized in the medial femoral condyle and are unilateral, whereas in secondary osteonecrosis, the second separate entity of osteonecrosis, as a rule both the medial and lateral sides are affected.

The etiology of SPONK is poorly understood, although a possible causative factor is minor trauma. On the other hand secondary osteonecrosis' pathogenesis is also practically unknown. For the pathogenesis of SPONK there are no associated risk factors whereas for secondary osteonecrosis the risk factors are:

- A possible mechanism is microvascular disruption in the subchondral bone, which causes infarction. This compromise of circulation leads to bone marrow edema and resultant

ischemia and necrosis.

The knee is the second most common site for osteonecrosis after the hip, comprising approximately 10% of cases of osteonecrosis. SPONK usually affects persons of young age (>55 y), while secondary osteonecrosis older people (<55y). The male to female ratio for both types of osteonecrosis is 1:3.

Osteonecrosis of the knee can easily be mistaken for primary osteoarthritis, meniscal tears, pes anserinus bursitis. Therefore it is important to identify osteonecrosis and even more it is important to differentiate between the 2 separate entities, SPONK and secondary osteonecrosis, in order to treat each disease appropriately.

In osteonecrosis the origin of the pain is the collapse of the necrotic segment. This can lead to disruption of the joint line, resulting in painful secondary arthritis. The range of motion of the joint may be limited by pain or effusion.

MRI is the gold standard for diagnosis of osteonecrosis with a 98% specificity and sensitivity. Other diagnostic procedures that may be used are: bone scans, venography, interosseous pressure measurements and core biopsy.

Regarding the medical therapy of osteonecrosis of the knee, treatment is similar for both SPONK and secondary osteonecrosis as long as the patient is asymptomatic. This encompasses a conservative regimen of partial weight bearing with crutches or a walker, nonsteroidal anti-inflammatory medications and physical therapy focusing on strengthening the quadriceps and hamstrings. However when the patient is symptomatic, treatment options differ. In SPONK continuation of non-operative treatment has good results, while in secondary osteonecrosis a surgical solution should be preferred. This may be either:

- A. Arthroscopic debridement,
- B. Osteochondral graphs,
- C. High tibial osteotomy,
- D. Core decompression,
- E. Unicompartmental knee arthroplasty
- F. Total knee arthroplasty.

In this patient the prolonged sitting in front of the computer, in combination with sudden rising up from the chair, could cause minor trauma and be a possible explanation for the pathogenesis of SPONK. His condition was complicated even more by ITBS caused by the internal rotation of the knee with which the patient walked in order to relieve from pain that was radiating over to the lateral femoral condyle. Treatment aimed to alleviate the knee from the pressure of the weight bearing by the use of the crutches for 6 weeks and to treat ITBS by dressing with kinesiotaping. Instead of this he was cautious for only 2 weeks and he returned to his work as soon as pain was bearable.

As a result of not following completely the medical advice he developed fully the disease called SPONK. Now, after 5 months walking only with partial pressure on his left lower limb, he is able to walk for short distances without any pain. He is in nonsteroidal anti-inflammatory drug medication and he follows a physical therapy program, focusing on strengthening the quadriceps and hamstrings. The new MRI is scheduled for this August and will show the progress of his knee condition.

### CME QUESTIONS

- 1 Which diagnostic tool is used to easily diagnose bone marrow edema?
- 2 Which of the following statements regarding bone marrow edema is true?

### References

1. Korompilias AV, Karantanas AH, Lykissas MG, Beris AE. Bone marrow edema syndrome. *Skeletal Radiol*. 2008 Jul 16. [Epub ahead of print]
2. Massara A, Orzincolo C, Prandini N, Trotta F. Transient regional osteoporosis. *Reumatismo*. 2005 Jan-Mar;57(1):5-15.
3. Pedraz T, Vela P, Esteve-Vives J, Pascual E. Normal initial magnetic resonance imaging in aseptic bone necrosis of the knee. *J Clin Rheumatol*. 2008 Apr;14(2):101-4.
4. Breitenseher MJ, Kramer J, Mayerhoefer ME, Aigner N, Hofmann S. [Differential diagnosis of bone marrow edema of the knee joint] *Radiologe*. 2006 Jan;46(1):46-54. Review. German.
5. Ortiz-Hernández L, Tamez-González S, Martínez-Alcántara S, Méndez-Ramírez I. Computer use increases the risk of musculoskeletal disorders among newspaper office workers. *Arch Med Res*. 2003 Jul-Aug;34(4):331-42.
6. Ijmker S, Mikkers J, Blatter BM, van der Beek AJ, van Mechelen W, Bongers PM. Test-retest reliability and concurrent validity of a web-based questionnaire measuring workstation and individual correlates of work postures during computer work. *Appl Ergon*. 2008 Nov;39(6):685-96. Epub 2008 Feb 4.

**Author Information**

**Ioannis Sioutis, MD**

Physical and Rehabilitation Medicine Dept, Askleipion State Hospital

**Georgios I. Vasileiadis, MD, PhD**

Physical and Rehabilitation Medicine Dept, Attikon University Hospital

**PJ Papagelopoulos, MD, DSc**

Ass. Prof., Department of Orthopaedics, Faculty of Medicine, University of Athens