

Missed Unstable Cervical Spine Injury Associated With The Alcohol Withdrawal Syndrome

D Wise, M Hunt, R Gabriel

Citation

D Wise, M Hunt, R Gabriel. *Missed Unstable Cervical Spine Injury Associated With The Alcohol Withdrawal Syndrome*. The Internet Journal of Rescue and Disaster Medicine. 2000 Volume 2 Number 2.

Abstract

Pain perception may be subtly masked by the alcohol withdrawal syndrome. A case is reported of a missed unstable cervical spine injury in this context

INTRODUCTION

Guidelines on the management of neck injury associated with blunt trauma indicate that significant injury is unlikely if the patient is fully conscious/not intoxicated, has no midline neck pain, no significant distracting injuries and

no neurological symptoms or signs (1,2). It is well known that acute alcohol intoxication can alter pain perception, however the symptom-altering effects of the alcohol withdrawal syndrome (3) are sometimes disregarded.

We report a case where the pain associated with an unstable cervical spine injury was masked initially by alcohol intoxication and then by the subsequent alcohol withdrawal syndrome.

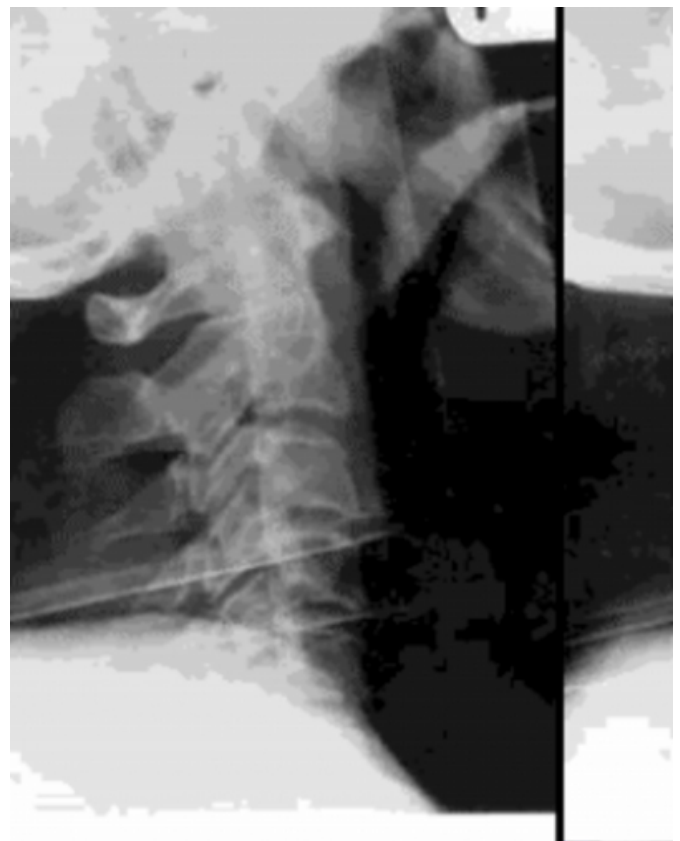CASE REPORT

A sixty-five year old man attended the Accident and Emergency Department one hour following a fall down fifteen steps. A witness stated that he had consumed half a bottle of vodka, had slipped and may have been unconscious for a few seconds after his fall. Other than alcohol abuse there was no past history of note. The paramedic ambulance crew had immobilized his neck on scene. He smelt of alcohol but was oriented with a Glasgow Coma Score of 15/15. He had minimal neck discomfort and no neurological symptoms or signs. Lateral cervical spine radiograph (Figure 1), supplemented

by a 'swimmer's' view to adequately demonstrate C6 -T1, together with antero-posterior and odontoid peg views were all unremarkable.

Figure 1

Figure 1: Lateral cervical spine radiograph at initial presentation shows no obvious abnormality.



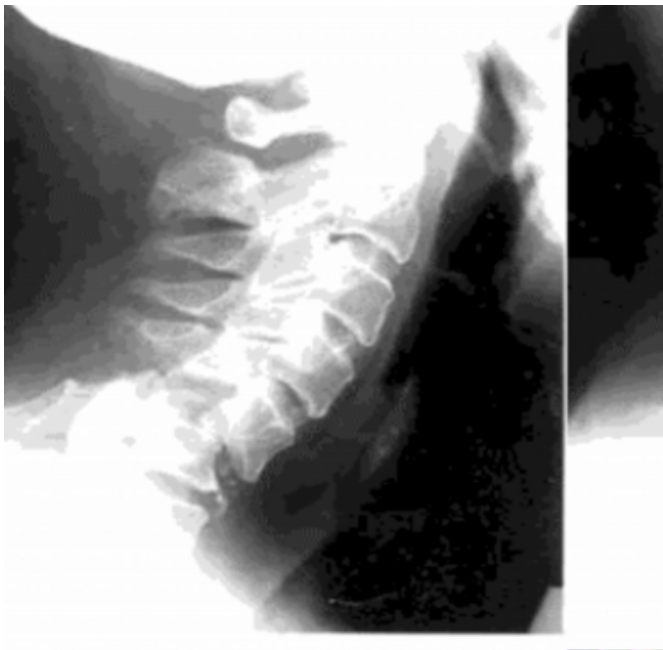
Log roll of the patient demonstrated no abnormality in his axial skeleton - specifically no posterior neck tenderness. A 2 cm shallow laceration over his occiput was sutured. No other injuries were apparent. The patient was admitted to the Accident and Emergency Department Observation Ward in view of the late hour, history of alcohol ingestion and

unconsciousness. He was kept in a hard cervical collar overnight. On review the following morning the acute effects of alcohol intoxication appeared to have worn off. He had no neck pain. The hard collar was removed.

He subsequently developed an acute alcohol withdrawal state, which responded well to a standard regimen of chlorthalidone orally and B vitamins intravenously. He was discharged from hospital after two days. Five weeks later he represented complaining of persistent neck pain. There had been no trauma in the interim. He had no neurological symptoms or signs. Lateral cervical spine radiograph showed C5-6 bifacet dislocation (Figure 2).

Figure 2

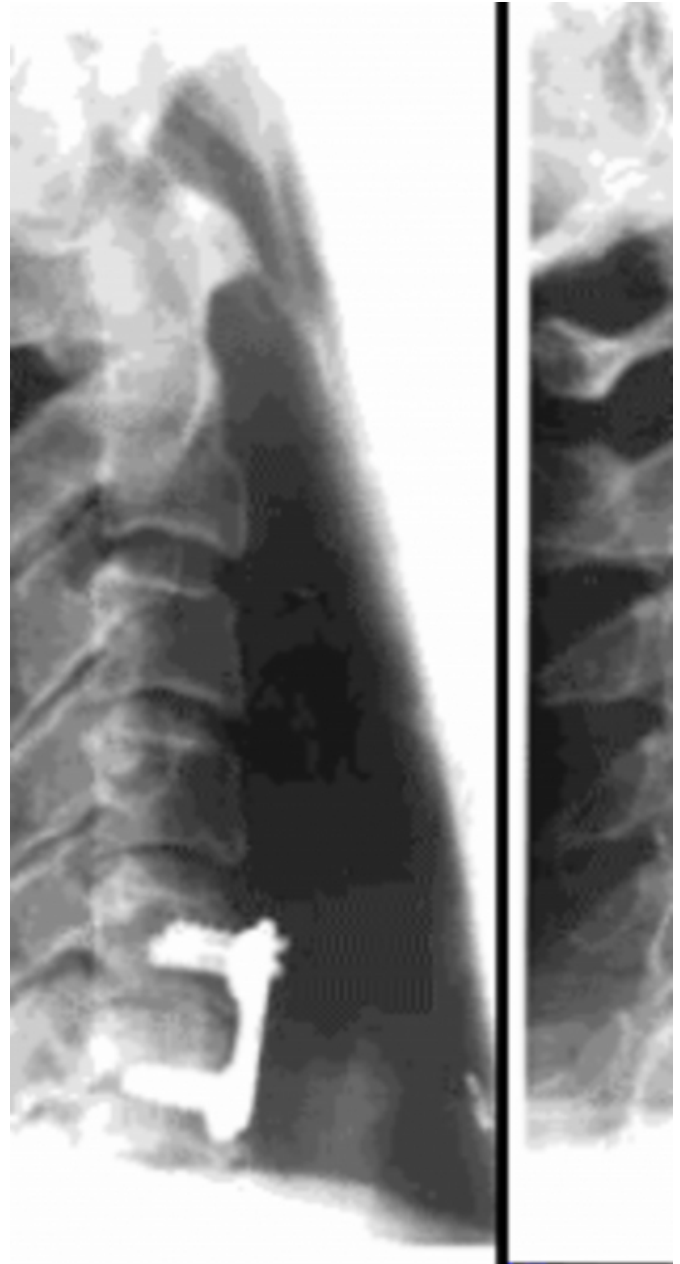Figure 2: Lateral cervical spine radiograph five weeks later shows C5-6 bifacet dislocation.



CT scan demonstrated no fractures. Reduction was successful with 16 lbs skull traction. Following anterior stabilization (Figure 3) the patient made an unremarkable recovery.

Figure 3

Figure 3: Following reduction by traction and internal fixation.



DISCUSSION

Neck injuries are common and guidelines on management are well established, particularly following the dissemination of the principles of the Advanced Trauma Life Support Course (2). The present patient had a mechanism of injury consistent with a serious neck injury (fell down fifteen steps). He had been drinking alcohol but appeared fully conscious (Glasgow Coma Score 15/15), had only minimal neck discomfort, no neurological symptoms or signs, no posterior neck tenderness, no significant distracting injuries and an unremarkable standard cervical spine radiograph

series. He was kept in a hard cervical collar until the acute effects of alcohol intoxication had worn off. However, the pain-perception altering effects of the alcohol withdrawal syndrome +/- its pharmacological treatment were overlooked; his immobilization was removed and his neck 'cleared' despite the presence of an unstable neck injury.

Any chronic alcohol abuser may suffer an alcohol withdrawal syndrome when hospitalized for any reason and, particularly if requiring pharmacological sedation, cannot therefore be deemed fully conscious. Classic pain symptoms may not be present in this context and significant injuries may be missed.

CORRESPONDENCE TO

David Wise 5/88 Barcom Avenue Rushcutters Bay Sydney NSW 2011 Australia email: davidwise2@hotmail.com

References

1. Hoffman J, Mower W, Wolfson A, et al. Validity of a Set of Clinical Criteria to Rule Out Injury to the Cervical Spine in Patients with Blunt Trauma. *N Engl J Med* 2000; 343(2): 94-99.
2. American College of Surgeons Committee on Trauma. *Advanced Trauma Life Support. Student Course Manual* 1997. 6th Edition. ISBN 1-880696-10-X
3. Hall W and Zador D. The Alcohol Withdrawal Syndrome. *Lancet* 1997; 349 (9069): 1897-1900

Author Information

David Wise, FRCS Ed

Registrar in Emergency Medicine, St Vincent's Hospital

Martin Hunt, FRCS FFAEM

Consultant in Accident and Emergency Medicine, Whipps Cross Hospital

Ramez Gabriel, FRCS Ed

Staff Grade in Accident and Emergency Medicine, Whipps Cross Hospital