

Adult Onset Cystic Hygroma Management

Y Ho, A Chang, P Canty

Citation

Y Ho, A Chang, P Canty. *Adult Onset Cystic Hygroma Management*. The Internet Journal of Otorhinolaryngology. 2009 Volume 12 Number 2.

Abstract

Cystic hygroma is an uncommon congenital lymphatic malformation. Its management is evolving from surgical excision to intralesion injection. A case of adult onset cystic hygroma is presented. The management of the hygroma is discussed to demonstrate that the management approach for cystic hygroma in adults is slightly different from that for children.

CASE REPORT

A 34-year-old female presented to the Ear, Nose and Throat (ENT) outpatient unit with a slowly expanding left neck mass that was diagnosed as a left brachial cyst. Computerized tomography (CT) showed an 80 mm x 60 mm x 60 mm well-circumscribed non-enhancing cystic mass in the left neck, anterior to the sternocleidomastoid from level 3 down towards the clavicle (Fig. 1). An ultrasound guided fine needle aspiration of the cyst showed abundant lymphocytes with no malignant cells. The cyst was excised with histopathology indicating a cystic hygroma (Fig. 2). The patient had repeat CT of the neck six months after surgery for follow up and it revealed no recurrence of lesions.

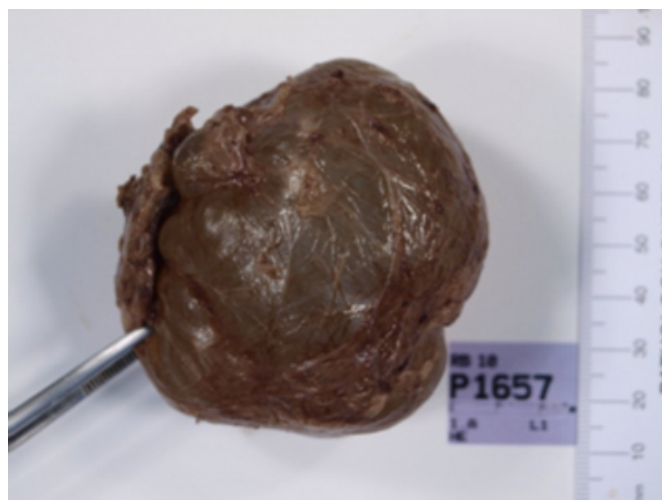
Figure 1

Fig. 1. (a) Axial, (b) sagittal and (c) coronal CT shows the lesion located in the left anterolateral neck with an intrathoracic component (arrows) and trachea deviation.

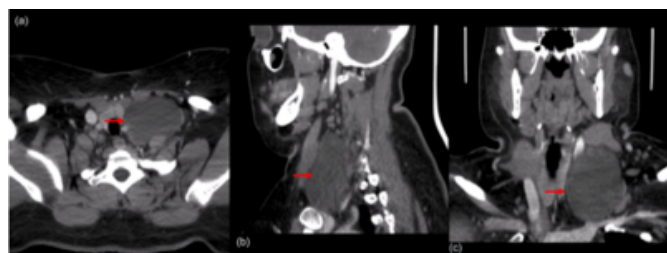

Figure 2

Fig. 2. A multiloculated cyst measuring 40 mm x 12 mm x 8 mm



DISCUSSION

Cystic hygromas, also called macrocystic lymphatic malformations, belongs to the family of lymphangioma. The mechanism of the formation of cystic hygromas remains unclear. There are several hypotheses suggested in the literature, these include sequestrations of developing lymphatic tissue derived from the primordial jugular sacs and failure to achieve lymphatico-venous communication resulting in congenital lymphatic blockage and lymphangioma formation.

Cystic hygroma is an uncommon congenital lymphatic malformation. The usual onset of the disease is during childhood. A study reported 90% of cystic hygroma was diagnosed in the first year of age. Some diagnosis was delayed until early adulthood. Trauma, infection,

malignancy and iatrogenic stimuli are the usual triggering factors for the enlargement of previously asymptomatic lesions. In our case, the patient gave a history of domestic violence involving an assault by her ex-partner in which the patient sustained a penetrating injury to her neck from a wooden spike. It was suggested that the retained wooden materials were the trigger for the foreign body reactions which resulted in proliferation of lymphatic tissues. Comparing to other body parts, the neck region has clearly defined tissue planes and ample space for expansion leads to cystic dilation and hygroma formation.

The management approach for cystic hygroma in adults is slightly different from that for children due to the fact that the differential diagnoses are different. Malignancy must be excluded in head and neck masses with adult onset. Some have suggested that in cystic hygroma, needle aspiration (FNA) should be done routinely to confirm the diagnosis histologically. Some forms of imaging are usually employed for the work-up of the cystic neck mass including ultrasonography, computed tomography and magnetic resonance imaging (MRI). Cystic hygromas have characteristically high signals in T1-weighted MRI and have low signals in T2-weighted MRI. Some have advocated these MRI features are diagnosing in cystic hygromas.

Treatment of cystic hygromas was largely surgical but it is now evolving. There were several cases of adult cystic hygroma that were successfully treated with intralesion sclerotherapy such as OK-423⁶. Some suggested intralesion sclerotherapy can be used for treating cystic hygroma as the first line agent. The cystic hygromas in adults were often macroscopic and infrahyoid in nature, which are highly treatable by surgery with low likelihood of recurrence. The benefit of sclerotherapy over surgery for adult cystic hygroma need to be established in further large trials so that it can gain its place as the first line treatment in adult cystic

hygromas. Adverse effects from sclerotherapy including infection and skin necrosis should not be overlooked.

In summary, cystic hygromas in adults are exceedingly rare. This case demonstrated that other than congenital causes, cystic hygromas can be caused by retained foreign materials from penetrating neck injuries. Even though they can still persist from childhood or remain asymptomatic until triggered as the other hypotheses suggested. Confirmation with histopathology is needed prior to definitive treatment; i.e., surgical excision. Sclerotherapy can be used as a salvage treatment, whereas first line sclerotherapy in treating adult cystic hygromas may need to be verified with further studies.

References

1. Oshikiri T, Morikawa T, Jinushi E, Kawakami Y, Katoh H. Five cases of the lymphangioma of the mediastinum in adult. *Ann Thorac Cardiovasc Surg* 2001; 7: 130–5.
2. Goetsch E, Hygroma colli cysticum and hygroma axillare. *Arch Surg* 1938; 36:394-479.
3. Huntington GS, McClure CFW, The anatomy and development of the jugular lymph sac in the domestic cat. *Am J Anat* 1910;10:177-311.
4. Riquet M, Briere J, Le Pimpec-Barthes F, et al, Cystic lymphangioma of the neck and mediastinum: are there acquired forms? Report of 37 cases. *M Rev Mal Respir*. 1999; 16: 71-9
5. Veeraraghavan G, Denny C, Lingappa A, Cystic hygroma in an adult; a case report, *Libyan Journal of Medicine*, 2009; 4, 160-61
6. Woolley SL, Smith DRK, Quine S. Adult cystic hygroma: successful use of OK-432 (Picibanil). *J Laryngol Otol*. 2008, 122: 1260–64.
7. Bill AH, Sumner DS, A unified concept of lymphangioma and cystic hygroma. *Surg Gynecol Obstet* 1965; 120:79-86,
8. Bhutta MF, Ching HY, Hartley BEJ. Cervico-thoracic teratoma masquerading as lymphatic malformation, *J Laryngol Otol*. 2006; 120: 955–58.
9. Curran AJ, Malik N, McShane D, et al: Surgical management of lymphangiomas in adults. *J Laryngol Otol* 1996; 110:586-589.
10. Giguere CM, Bauman NM, Sato Y, Treatment of lymphangiomas with ok-432 (Picibanil) sclerotherapy - a prospective multi-institutional trial. *Arch Otolaryngol Head Neck Surg*. 2002; 128: 1137-44

Author Information

Yiu Ming Ho, B Hlth Sci, MBBS

Department of Otolaryngology, Ear Nose and Throat, Royal Brisbane Hospital

Andrew Chang, MBBS

Department of Otolaryngology, Ear Nose and Throat, Royal Brisbane Hospital

Paul A Canty, MBBS, FRACS

Department of Otolaryngology, Ear Nose and Throat, Royal Brisbane Hospital